

# The Effect of Aqueous *Garcinia Kola* Seed On The Liver Histology

Nanyak Z. Galam<sup>1</sup>, Ibraheem M. Gambo<sup>\*1</sup>, Ali A. Habeeb<sup>2</sup>, Ali I. Shugaba<sup>3</sup>,

<sup>1</sup>Department of Human Physiology, University of Jos, Jos.

<sup>2</sup>Department of Human Physiology, College of Medicine, University of Maiduguri.

<sup>3</sup>Department of Human Anatomy, University of Jos, Jos.

Corresponding author: \*ibroababs@yahoo.com

## Abstract

**Background:** Various parts of *Garcinia kola* plant are used for a wide range of medicinal purposes in Africa where it is indigenous. The kernels of the nut are widely traded and are eaten as bitter stimulant while extract of the seed have been used traditionally for the treatment of cough and liver diseases. This study is done to evaluate the possible histological effect(s) of aqueous extract of *Garcinia kola* seeds on the liver of albino rat. Twenty (20) matured wister rats were grouped into four (A, B, C and D). Each group contained five(5) rats. Group A received 125mg/kg of the extract while groups B and C received 200mg/kg and 500mg/kg respectively. Group D served as control. The results obtained revealed that the treated sections of the liver showed no evidence of degenerative changes or cyto-architectural distortions of the hepatic parenchyma. It was concluded that intake of *Garcinia kola* in itself does not cause any acute morphological changes in the liver.

**Keywords:** *Garcinia kola* seed, Liver, histology.

## 1. INTRODUCTION

*Garcinia kola* is a medicinal plant grown in tropical rainforest in West Africa. The height of the plant is approximately 14m and it produces a reddish yellowish or orange colour fruits containing 2-4 seeds. *Garcinia kola* is endemic in the humid rain forest vegetation in the coastal areas and lowland plains up to 300m above sea level, average of 2500mm of rainfall per annum. Extract from the bark of the plant are used in traditional medicine for treatment of liver cirrhosis and hepatitis. *Garcinia kola* is a fruit from one of a family of many handsome, tropical evergreen trees and shrubs called mangosteens that are native to India and Southern Asia, southern Africa and Polynesia. The tree bears deep green, glossy, yellowish, pumpkin shaped fruit with a sour taste, primarily because of their high hydroxycitric acid content and they may contain thirty percent(Iwu,1987). The tree, which may thrive in poor soils, has been known in Asia for many reasons. It produces brownish-yellowish gum resin (xanthone) that is used commercially as a pigment, and it has also had some value in the timber industry. The fruit has also been used in Indian cuisines to flavor curries, preserve fish and as a condiment (Mahanato,1982).

It has also occupied a place in an ancient Indian Ayurveda as a purgative and as an aid that activates digestion. The last property created interest in the herb, and in 1965, researchers identified a compound called hydroxycitric acid (HCA) that had a chemical structure similar to that of citric fruits which may be of great value in weight loss programs and energy boosting regimens. Although most of the research into herb has been conducted in the laboratories, with no conclusive clinical trials to prove the herb efficacy, continuing test may hopefully reveal positive evidence. In Japan, *Garcinia* has been used to decrease body fat for years. Some of the constituent induced in *Garcinia* are the all-important hydroxycitric acid (HCA), phenol, acetic acid, calcium, tartaric acid, succinic acid and carbohydrate. *Garciniakola* is growing in popularity as a natural and effective way to help in weight loss programs. *Garciniakola* is a medium sized forest tree found through west and central Africa. The seed are eaten as refresh past time in Nigeria and are known to contain high content of biflavonoid compound. *Garciniakola* has been reported to contain a complex mixture of prephenylated benzophenones, xanthenes and biflavonoids. Antioxidants decline with age and such, requires nutritional supplements. Administration of *Garciniaseed* extract caused an increase in testosterone production in sprague-dawley rats' constituents also, Adesanya et al confirmed the spermatogenic and tissue enhancing effect of *Garciniakola* extract in male Wister rats. Considerable experimental evidence has been adduced in support of the anti-hepatotoxic efficacy of kolaviron in animals against such hepatotoxicants as paracetamol (Iwu,1987), carbon tetrachloride, thioacetamide, galactosomine, phalloidine and ethanol(Farombi,2002). In a previous study it was also observed that the hepatoprotective effect of the extract in amodiaquine induced gastric ulceration (Ajani et al, unpublished data). The seed of the plant have shown to have various bioactivities in experimental models such as neuroprotective and bronchodilatory effects. Various complex compounds have been isolated from *Garcinia kola* such as kolaviron, xanthenes, quacinoic acid, gareinal and tocotrienol(Orie,1993). *Garcinia kola* seeds are considered a poison anti-dote in Africa. Kolaviron, a biflavonoid of *Garciniakola* was found to protect rat's liver against carbon tetrachloride and phalloidin poisons (Iwu,1987). Lipid

peroxidation of rat liver was inhibited by *Garciniakola* seed extract in dose dependent manner possible due to isoflavones(Adegoke,1998).

## **2.Aims and Objectives**

The aims of this study are to histologically evaluate the possible effects of aqueous extract of *Garciniakola* seeds on the liver of albino rat and to compare the results with the ones reported by other researchers.

## **3.METHODOLOGY**

This study covered a period of twenty-one days. A total of twenty matured wister rats grouped into four were used.

## **4.COLLECTION AND PROCESSING OF SEEDS**

The seeds of *Garciniakola* were procured from a local market in Jos town, plateau state, Nigeria. It was identified in the department of botany, university of Jos plateau state Jos Nigeria. The neatly washed nut or seed of *Garciniakola* prepared were dried in the sun for two days. This helped to detach the thin bark or cuticle attached from the epicarp of the seeds and makes the bark brittle. The nuts were then sliced into pieces by cutting longitudinally with a kitchen knife to enhance drying. The sliced pieces were dried under the sun for two weeks and then using a mortar and pestle, the dried seeds were prepared until it turned into powder.

## **5.PREPARATION OF EXTRACT**

The dried powdered *Garciniakola* was dissolved in three liters of distilled water and shaken vigorously, it was allowed to stand on the bench shaking at intervals. The solution was then refrigerated for twenty four hours and then sieved using laboratory sieve. This is then allowed to stand for at least one (1) hour so as to allow the heavier particles to settle down after which, it was decant and filtered using Whatman filter paper and transferred into an open tray and dried in the oven at 40°C for 3days then scraped with a spatula and crushed into fine powder using laboratory mortar and pestle.

## **6.TREATMENT OF ANIMALS**

Twenty one male albino rats (150-210g) were used for the experiment. They were maintained under standard laboratory conditions in the animal house of university of Jos, plateau state, Nigeria, and fed with standard pellet diet and water *ad libitum*. The animals were weighed, coded and grouped randomly into group A, B, C, And D. group A containing five (5) rats with body weight ranging between 175 – 185 gram were administered with 125mg/kg dose of the extract, while group B and C containing 6 rats with body weight ranging between 180-185g and (200-210g) respectively were administered with 250mg/kg and 500mg/kg respectively. Group D containing four rats with body weight ranging between (150-165g) were not given the extract and served as the control group and they were given equal volume of normal saline. The animals in all the groups were given the extract for 21 consecutive days. Administration of the extract was done orally. On the 22days the animals were taken to the anatomy laboratory of the university Jos, plateau state for further histological studies on the liver, the animals were sacrificed by cervical dislocation and the liver excised. All experimental procedure followed the recommendation provided in the “Guide and care for the use of laboratory animals” (National Academy Press, 1996).

## **7. RESULTS**

The treated and controlled section of the liver showed normal histological feature. Figure 1, 2 reveals normal hepatocytes, normal and wider sinusoids while figure 3 and 4 reveals normal nuclei within the hepatocytes with radial disbursement cells and limited sinusoid.

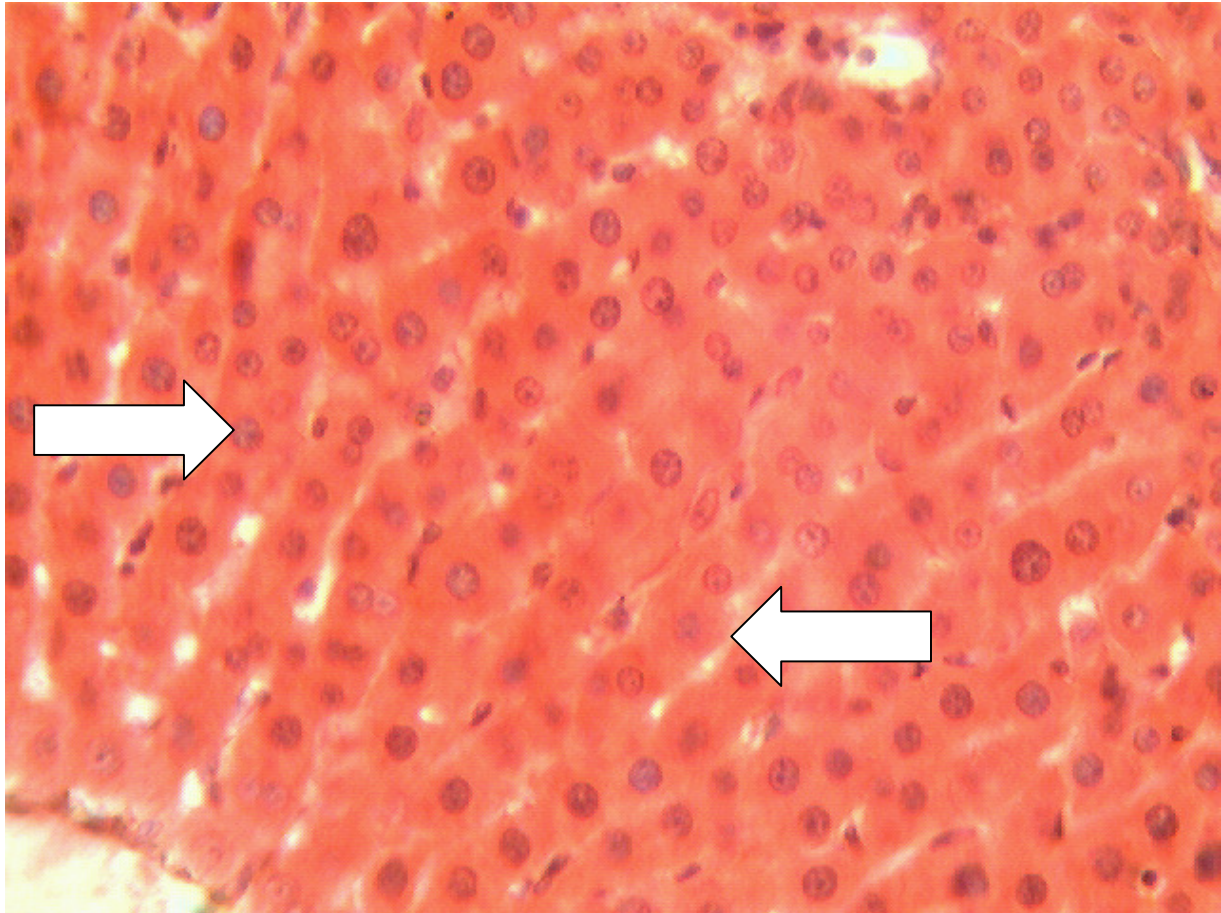

Figure 1: liver (H & E stain X400)  
control group  
Arrow right shows normal hepatocyte.  
Arrow left shows limited sinusoid.

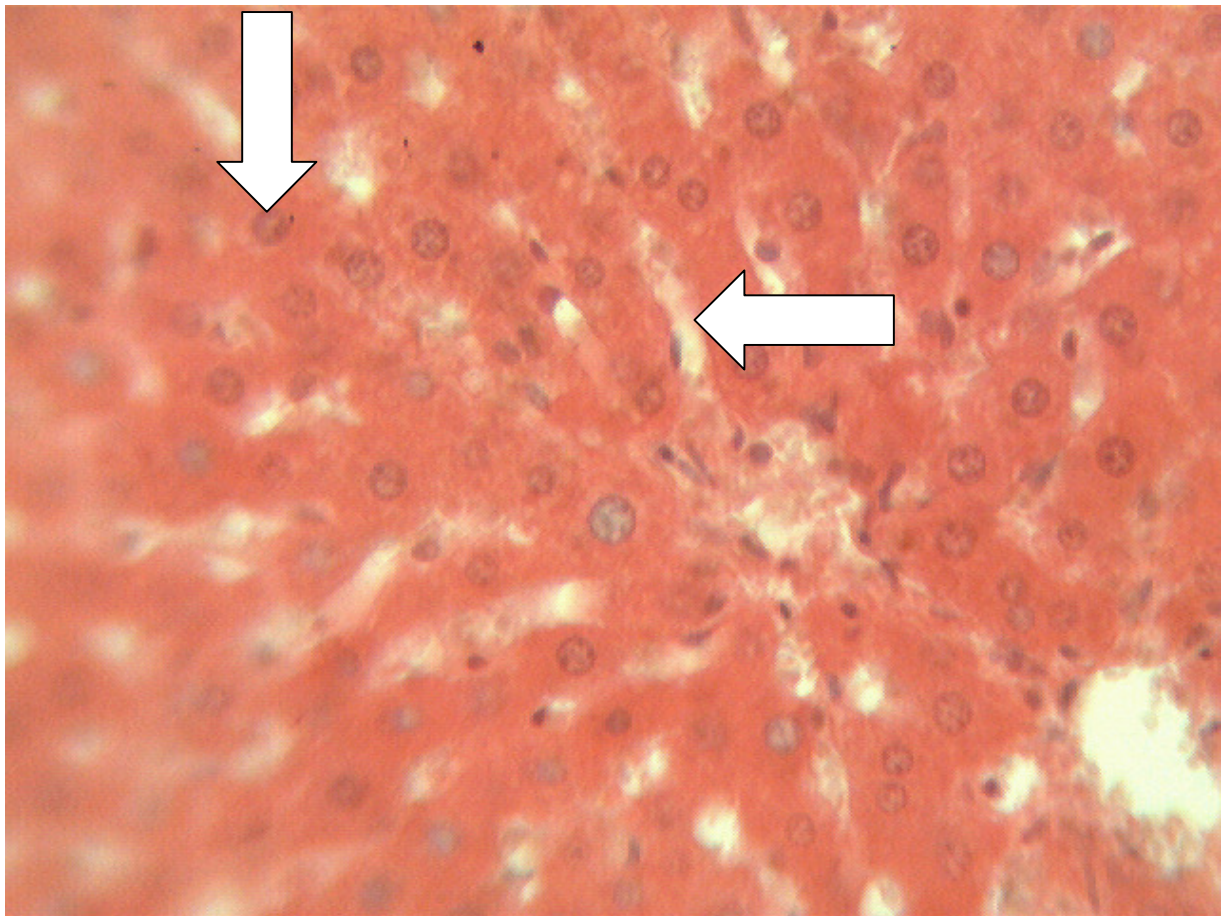


Figure 2: liver (H & E stain X400)  
group A (125 mg/kg of extract administered)  
Arrow down shows normal hepatocytes.  
Arrow left shows wider sinusoid.

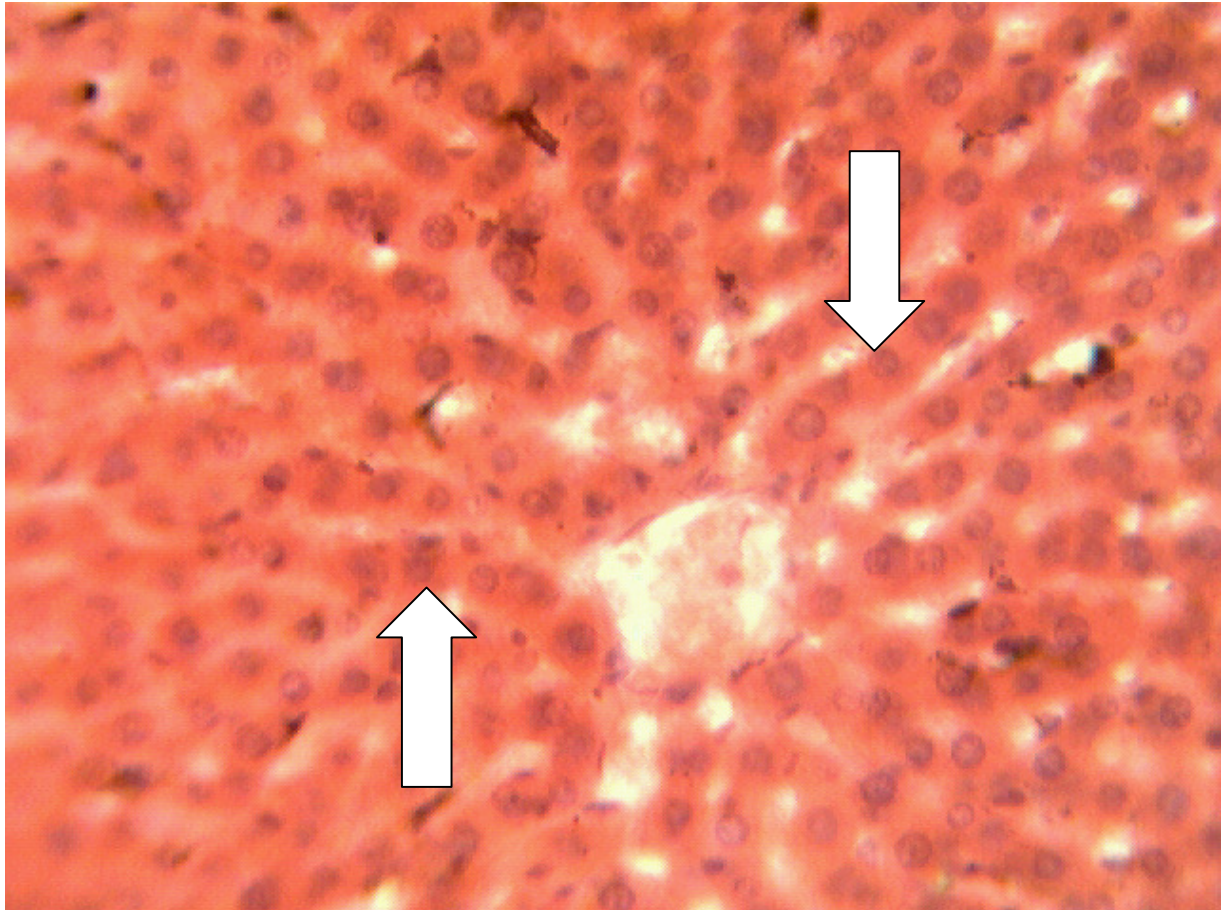


Figure 3: liver (H & E stain X400)  
group B (250 mg/kg of extract administered)  
Arrow down shows normal hepatocytes  
Arrow left shows wider sinusoid

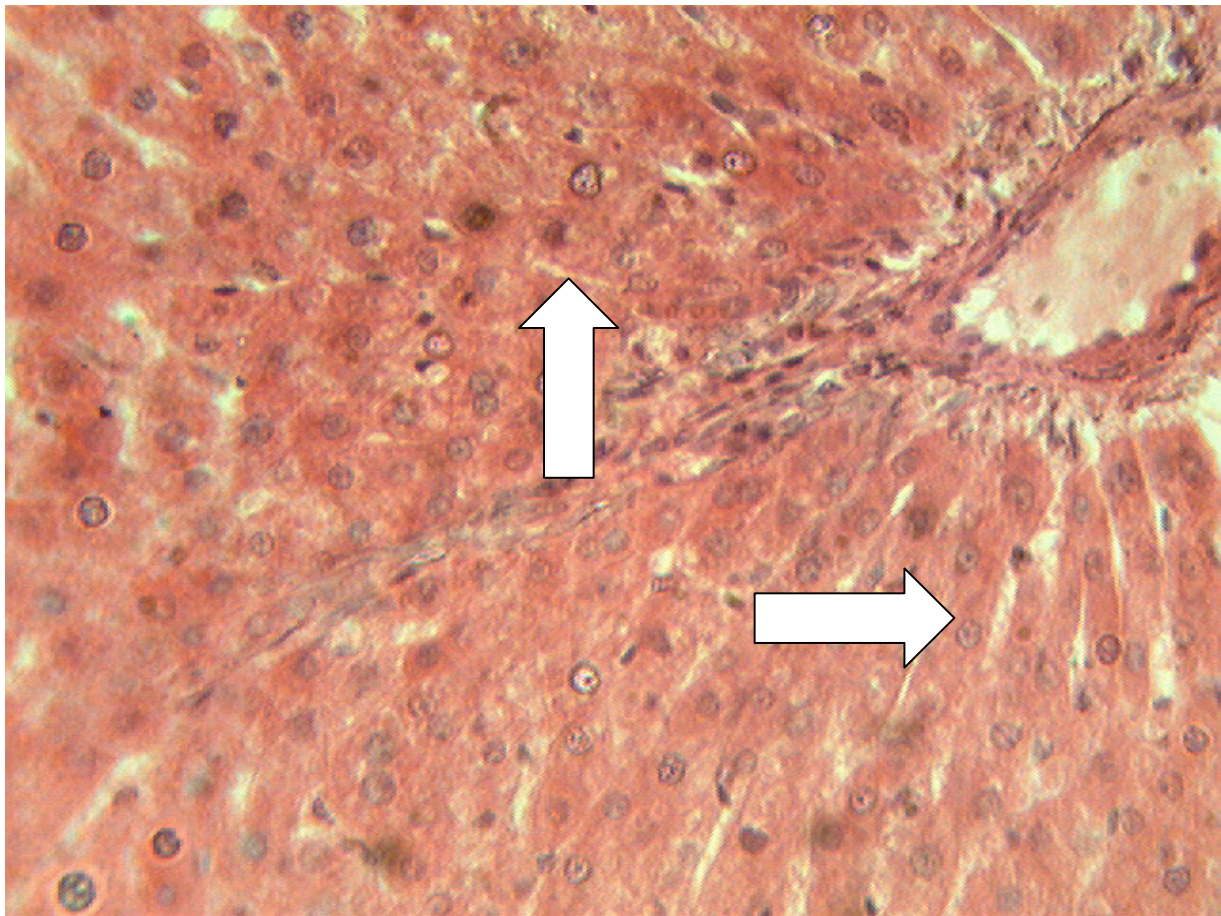


Figure 4: liver (H & E stain X400)

group C (500 mg/kg of extract administered)

Arrow up shows limited sinusoid

Arrow right shows normal nuclei within hepatocytes with radial disbursement cells

## 8. DISCUSSION

The histological findings revealed that there was no distortion on the cyto-architecture of the liver parenchyma in both the control and the treated groups figure 1 and 2, but there were a little distortion of the liver parenchyma in both figure 3 and 4. The result in figure one which is the control group revealed normal hepatocytes and limited sinusoids, figure 2 which is the group A shows normal hepatocytes and wider sinusoids, while figure 3 and 4 being group C and D respectively shows normal nuclei within the hepatocyte with radial disbursement cells and limited sinusoids. This confirms that consumption of *Garciniakola* seed is safe for the liver which is the first organ susceptible to any injurious substance in case of toxicity. This investigation further buttresses a similar work done by Iwu 1985, Akintowa and Essien, 1990, which confirmed in their work that *Garciniakola* have protective effect against a variety of experimental hepatotoxins. Studies have also shown the anti-hepatotoxic efficacy of this plant seed due to its Kolaviron content in animals against hepatotoxicants as paracetamol (Iwu 1986) carbon tetrachloride tioacetamide, gaketosamine, phalodine and ethanol (Farombi, 2000, Adaramoye et al, 2005). It may be inferred from the present study that even at higher dosage (500mg/kg) *Garciniakola* did not cause significant degenerative or trophic changes in the liver cells. The hepatic lobules which are polyhedral three dimensional in shape were preserved. The actual mechanism by which *Garciniakola* performs their functions is still unknown but may be due to their high bioflavonoids content. *Biflavonoids*, alkaloids and tannins have been associated with anti-microbial effects in various studies using the plant extracts. In *Garciniakola* flavonoid has been screened to have antioxidant property. This antioxidant which is expected to be active in the flavonoid isolated from the *Garciniakola* seed extract may have acted on the liver tissue by scavenging natural free radicals which involves the donation of electrons.

## REFERENCES

- Adegoke G. O, Vijay K.m., Sambaiah K., Lolash B.R (1998): Inhibitory effect of *Garciniakola* on lipid peroxidation in rat liver homogenates. Ind. J of exp. Biol.
- Farombi E.O, Akkani O.O, Emerole G.O (2002): Antioxidants and scavenging activities of Flavonoid Extract (Kolaviron) of *Garciniakola* seeds in vitro. Pharm. Boil. 40 (2) 1:107-116.
- Iwu M.M, onwuchekwa, U. A; Okuni C.O (1987): Evaluating the antihepatotoxic active of the bioflavonoids of *Garciniakola* seed. J of Ethnopharmacol 127-136.
- Mahanato S.B . Ganguly. A.N.; Dash N.P. (1982): Review-steriod saponins. Phytochemistry 21(5): 959-978.
- Orie N.N. and Ekon E.U (1993): The bronchodialator effect of *Garciniakola* East African Med. J 70: 143-145.

This academic article was published by The International Institute for Science, Technology and Education (IISTE). The IISTE is a pioneer in the Open Access Publishing service based in the U.S. and Europe. The aim of the institute is Accelerating Global Knowledge Sharing.

More information about the publisher can be found in the IISTE's homepage:

<http://www.iiste.org>

## CALL FOR PAPERS

The IISTE is currently hosting more than 30 peer-reviewed academic journals and collaborating with academic institutions around the world. There's no deadline for submission. **Prospective authors of IISTE journals can find the submission instruction on the following page:** <http://www.iiste.org/Journals/>

The IISTE editorial team promises to review and publish all the qualified submissions in a **fast** manner. All the journals articles are available online to the readers all over the world without financial, legal, or technical barriers other than those inseparable from gaining access to the internet itself. Printed version of the journals is also available upon request of readers and authors.

### IISTE Knowledge Sharing Partners

EBSCO, Index Copernicus, Ulrich's Periodicals Directory, JournalTOCS, PKP Open Archives Harvester, Bielefeld Academic Search Engine, Elektronische Zeitschriftenbibliothek EZB, Open J-Gate, OCLC WorldCat, Universe Digital Library, NewJour, Google Scholar

