

# Toxicological Pathology of Contraceptive in Rat by Oral Intubation for Six Months

MAJEED SALEH. K

55 Desborough Road, Hartford- Huntingdom, Cambridgeshire, PE 29 1 SN, England

Tel: 00447514071037 E-mail: [Salehmajeed1940@yahoo.co.uk](mailto:Salehmajeed1940@yahoo.co.uk)

HASAN MOHAMMED A. A.

Dep. of Pathology & Poultry Diseases, College of Veterinary Medicine, Univ. of Basrah, Iraq

Tel: 0060186606548 E-mail: [mohammedn10@yahoo.com](mailto:mohammedn10@yahoo.com)

ZAINAB W. KHUDAIR

Dep. of Pathology & Poultry Diseases, College of Veterinary Medicine, Univ. of Basrah, Iraq

Tel: E-mail: [pathovet.basra2015@gmail.com](mailto:pathovet.basra2015@gmail.com)

AL-SEREAH BAHAA. A

Dep. of Pathology & Poultry Diseases, College of Veterinary Medicine, Univ. of Basrah, Iraq

Tel: 9647700285271 E-mail: [bahaa\\_bkf@yahoo.com](mailto:bahaa_bkf@yahoo.com)

## Abstract

The study was done on laboratory white rats (Sprague dawelly) in 2 groups, 8 male and female as untreated control and 8 male and female as treated with contraceptive pills. The study showed that untreated animals were normal in breeding respect while treated animals showed no evidence of breeding at all and histopathologically untreated controls showed normal ovaries and testis while treated animals showed atrophy of ovaries and marked suppression of spermatogenesis. Other histopathological changes were also seen in liver and kidney.

**Keywords:** contraceptive, ovary, testis and rat

## Introduction

Because of high important of contraceptive to health of women during reproductive age the present research was done. [1] studied the effect of medroxyprogesteron acetate on the response of the rat mammary gland to carcinogenesis. [2] reported cardiovascular effect of endogenous and exogenous sex hormones over a women's lifetime. [3] studied the quantitative analysis of germ cells and leydig cells in rat made in fertile wis gossypol. [4] the comparative study Yaz and ovocept -ID on patients with simple ovarian cysts referring to iran-isfahan shariati hospital. [5] effect of compined oral contraceptive on the skin of mice. [6] studied evaluation of extended and continuous used oral contraceptive. [7] studied application of H-point standard additions method for simultaneous determination of levonorgestrel and ethinylestradiol in oral contraceptive LD [8] effect of contraceptive on skin in respect of acne and seborrhea. [9] studied combined oral contraceptives and body weight: do oral contraceptives cause weight gain. [10] studied the cardiovascular side effects of diethylstilbestrol, cyproteroneacetate, medroxyprogesterone acetate and estramustine phosphate used for the treatment of advanced prostatic cancer. [11] studied estrogen and skin: the effects of estrogen, menopause and hormone replacement

therapy on the skin.[12]did the improved organ maintenance of the human sebaceous gland: modeling in vitro the effects of epidermal growth factor, androgens, estrogens, 13-cis retinoic acid, and phenol red.

### Materials and Methods

Sixteen male and female rats were divided into 2 groups were reared in animal house of the veterinary medicine college of basrah university/Iraq. First group was considered as untreated and consisted of 4 males and females adult rat, the second group was treated group also consist of 4 males and 4 females adult rats. Treated rats were given one tablet of contraceptive (each tablet contain 0.15mg of levonorgestrel and 0.03mg of Ethinyl Estradiol) in drinking water for the first three months than they were given 2 tablet in drinking water for the last three month. The end of six month study rats were sacrificed and internal organ were fixed in 10 percent formalin in section were done and stained with (H and E stain).

### Results

Macroscopically, treated animals showed atrophy of the ovaries and reduced size of testis. Microscopically, there was evidence of atrophic ovary characterized by reduced number of gravian follicles and reduced number of corpora luteal while testis showed marked suppression if spermatogenesis with no mature spermatozoa and Epididymis tubules were empty with no evidence of any spermatozoa in lumen. Other secondary changes in liver and kidney were also seen.

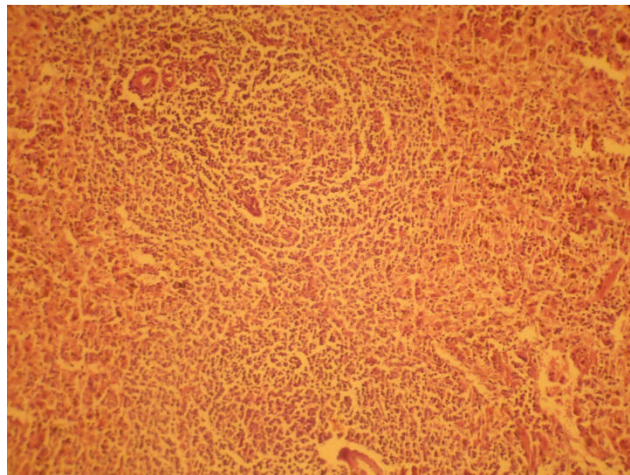


Fig.1:ovary with several corpora lutea no evidence of ovarian follicle or gravian follicles (H&E. 4 x)

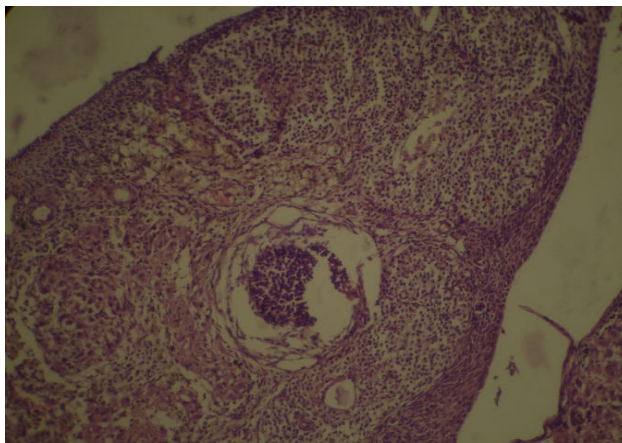


Fig.2: ovary with corpora lutea hardly any ovarian follicular tube seen (H&E 10 x)

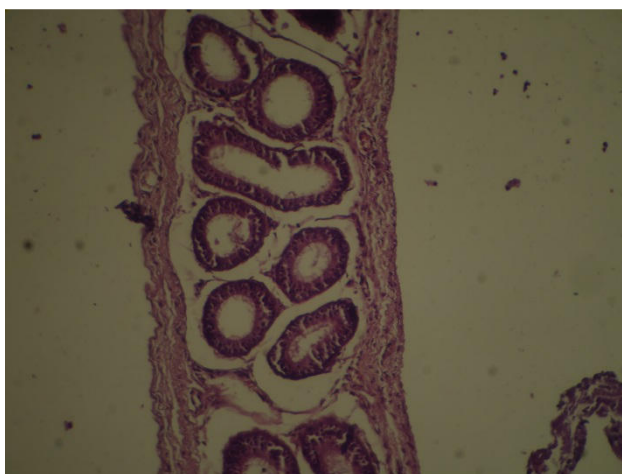


Fig.3: Epididymis with tubules empty, no spermatozoa in lumen (H&E 10x)

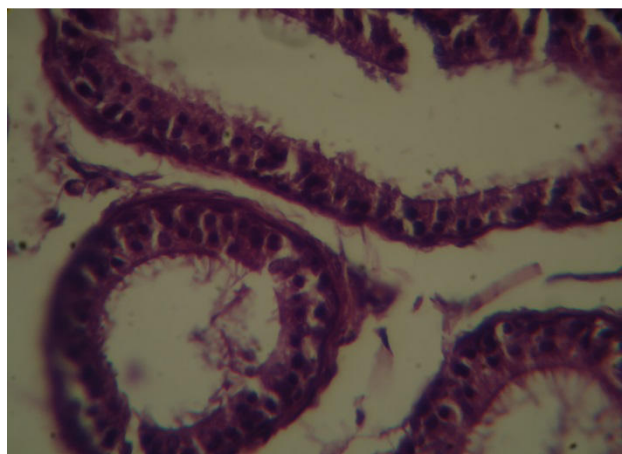


Fig.4: Epididymis with tubules empty, no spermatozoa in lumen (H&E 40x)

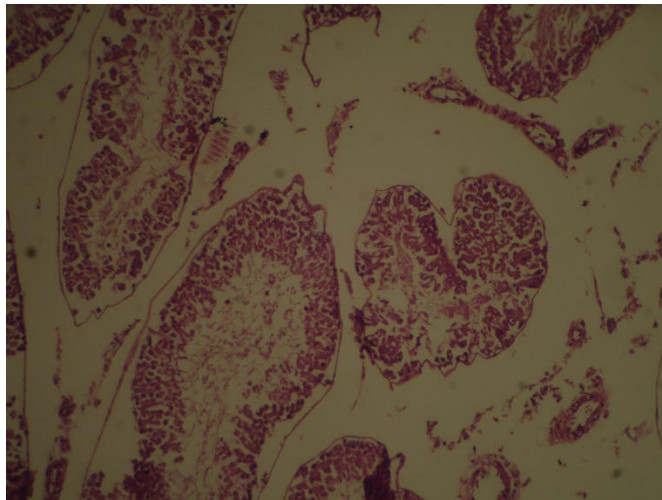


Fig.5: Testis with marked suppression of spermatogenesis, no secondary spermatocytes or spermatozoa in lumen. Evidence interstitial odema between semineverous tubules (H&E 4x)

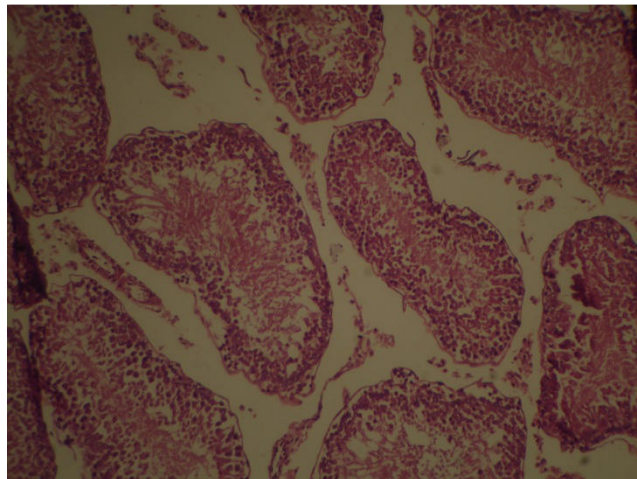


Fig.6: Testis with marked suppression of spermatogenesis, no secondary spermatocytes or spermatozoa in lumen. Evidence interstitial odema between semineverous tubules (H&E 10x)

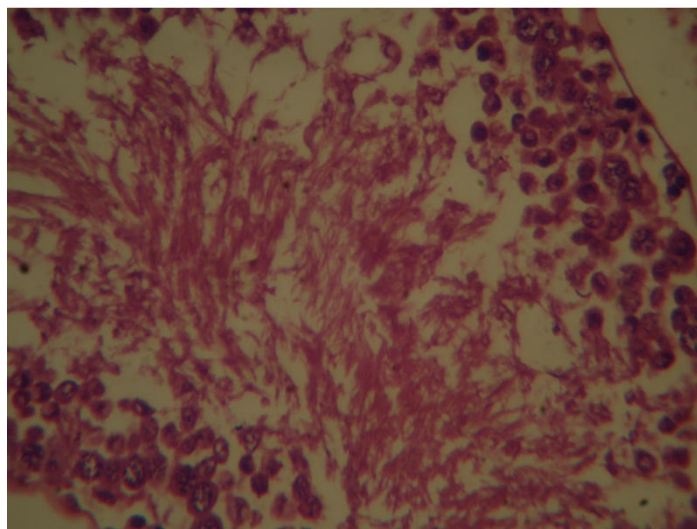


Fig.7: Testis with marked suppression of spermatogenesis, no secondary spermatocytes or spermatozoa in lumen. Evidence interstitial odema between semineverous tubules (H&E 40x)



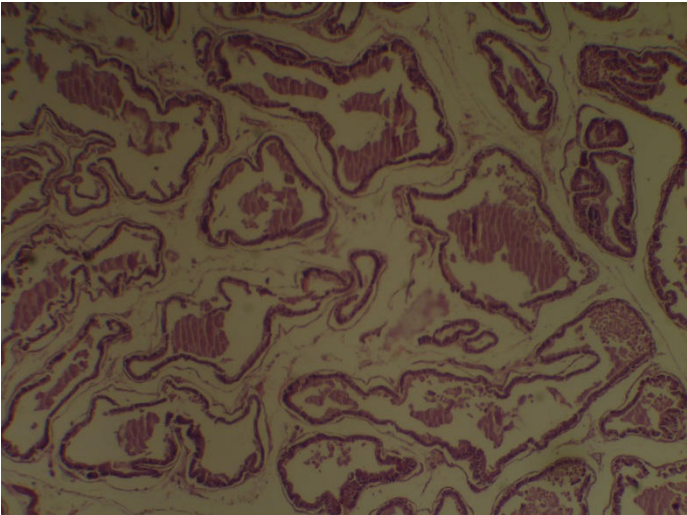


Fig.8: prostate with dilated alveoler tubules (H&E 10x)

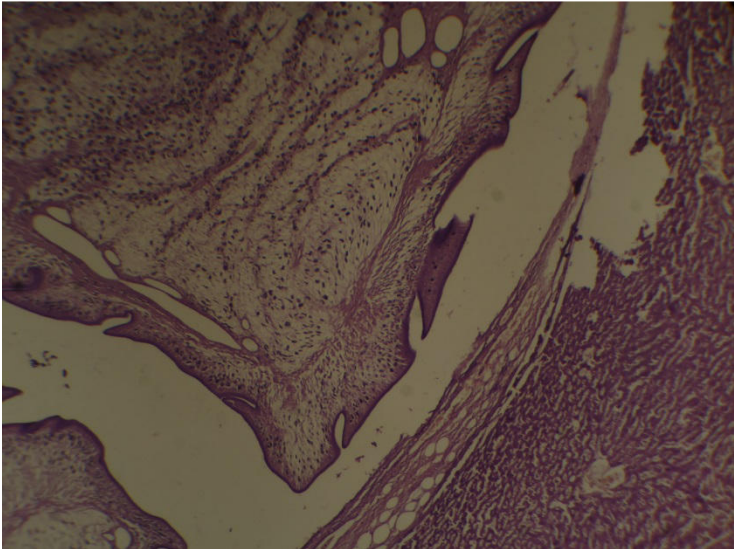


Fig.9: liver with cysticercus vesicularis (H&E 4x)

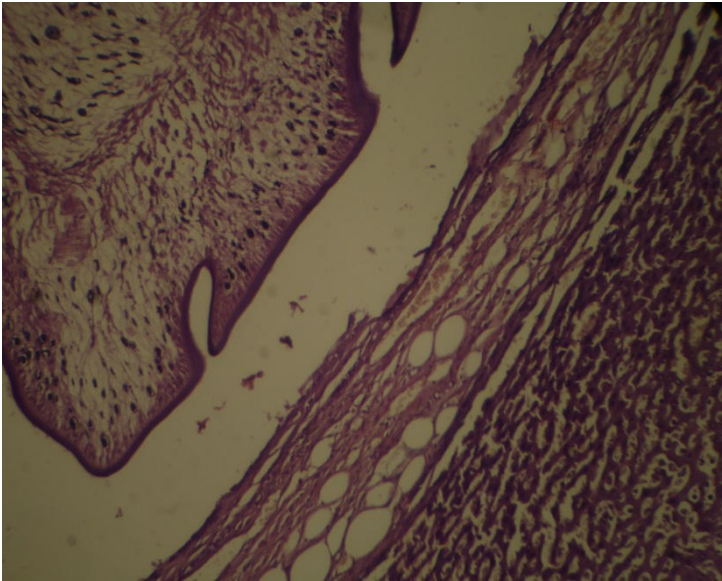


Fig.10: liver with cysticercus vesicularis (H&E 10x)

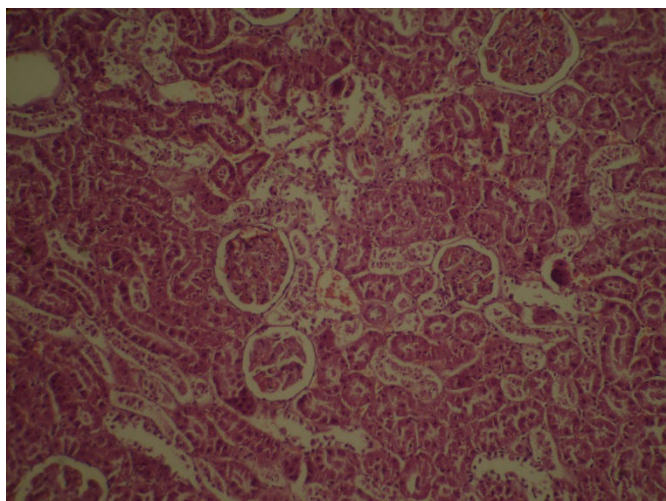


Fig.11: Kidney with areas of degenerate necrotic cortical tubules, some glomeruli with high cellularity (H&E 10x)

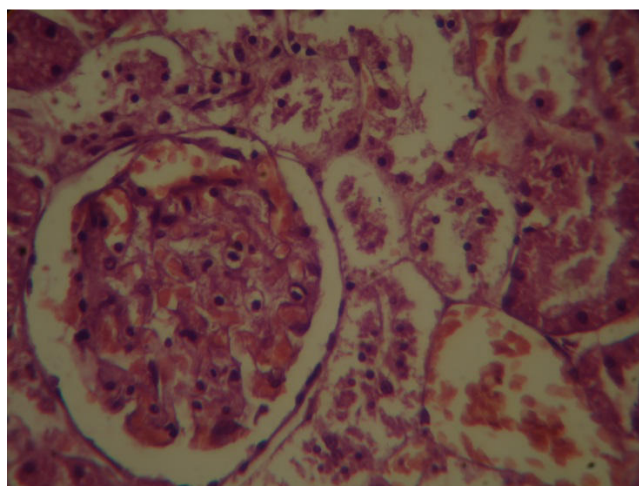


Fig.12: Kidney with areas of degenerate necrotic cortical tubules, some glomeruli with high cellularity (H&E 40x)

## Discussion

Contraceptive is very important in respect of human as it is humoral activity can result induction cardiovascular lesion, liver lesion such as stasis (colistasis) of bile duct or increase incidence of tumor especially mammary tumor and because of the above research on toxicity of contraceptive was considered very important from the health view especially for women during reproductive age.[1] during his work on effect of medroxy progesterone acetate on the rat mammary gland to carcinogenesis it was concluded this progestagenic agent didn't increase the risk of carcinoma development when administered to rat at the clinical dose use for contraception, however a 10 fold dose increase resulted in a higher tumorigenic response, in respect to the present research the high concentration of contraception only gave rise to atrophic ovary and suppression of spermatogenesis but it was not high enough to induce mammary tumor.[2] studied the cardiovascular effect of endogenous and exogenous sex hormones over a women lifetime, the above hormones effect the high density lipoprotein (HDL) concentration do not fall but low density lipoprotein(LDL) concentration usually declined, these physiological fluctuation have not been associated with increased arteriosclerosis, orally contraceptive the combine C21 progestin's and certain C19 progestin derivative with estrogen have little or no effect on (HDL). In

conclusion estrogen-progestin regimens that do not effect (LDL&HDL) cholesterol concentration are most desirable in term of term cardio vesicular risk, in our study there was some effect on the heart, kidney, reproductive organs.[3] studied the quantitative analysis of germ cells and leydig cells in rat made infertile with gossypol, the study was done in rat feed three doses levels and 10,20 or 30mg/kg per day of gossypol for nine week it was noted that germ cell depletion such as that caused by high doses of gossypol is not mediated by change in leydig cell function, the present report emphasis the important of studies to determine the minimal effective dose for gossypol antifertility activity in animals models as well as in man, our study was to analysis the histopathological effect of contraceptive in males and females while gossypol was only used as contraceptive for males[4]did comparative study of Yaz (drospirenon/Ehinyl estradio), both there are contraceptive pill used for treatment of patient of ovarian cyst, side effect was weight gain, spotting, breast tenderness, Nosit, headache, our study showed histopathological effect on liver, kidney, heart, skin and gonads.

[5]studied the effect of combined oral contraceptive which they used in ethyl estradiol/cyproteron acetate (ECPA, dine 35) on female mice in 2 group for 1 month, control and treated, the result showed significant increase in epidermal and dermal thickness and dermal vascularity, also decrease in number and size of spacious gland, while in our study we found thinning of epidermis, atrophy of spacious gland in addition to changes in liver, kidney, heart and gonads. [6] . studied evaluation of extended and continuous used oral contraceptive, they review the history and the potential uses of new continuous comined oral contraceptive, no histopathological change were done, in the present research paper his pathological study of skin, liver, kidney, heart and gonads was done with treatment related effect. [7] studied the application of H- point standard additions method for simultaneous determination of levonorgestrel and ethinylestradiol in oral contraceptive LD analyzed pharmaceutical and chemical structures of the above contraceptive while the present study did histopathological research on visceral organs of rat with histopathological changes observed in skin, liver, kidney, heart and gonads[8] studied the effect of contraceptive on the skin in respect of acne and seborrhea, our study showed contraceptive cause reduce hair follicle, atrophy of spacious gland and partial thinning of skin. [9]only on body weight gain while the present study on skin visceral organs and gonads. [10] did study on effect of different contraceptive on treatment of advanced prostate cancer, the present research did only the effect of contraceptive on visceral organs, gonads and skin only from the histopathological point view. [11]studied the effect of estrogen on skin, menopause and hormone replacement therapy on the skin, our study reported changes in the skin after treatment of rat with contraceptive in addition to other histopathological change of liver, kidney, heart and gonads. The improved organ mutinous of human spacious gland in vitro modeling, our study was on contraceptive which showed treatment related effect on spacious gland manifested us atrophy [12].

## Conclusion

The present topic was intended to study the toxic effect of contraceptive pills in laboratory white rats.

## References

- 1.Russo,L. et al. ( 1989). Effect of medroxyprogesterone acetate on the response of the rat mammary gland to carcinogenesis. Br. J. Cancer. 59(2), 210–216.
2. Knopp, R.H.( 1988). Cardiovascular effects of endogenous and exogenous sex hormones over a woman's lifetime. American Journal of Obstetrics and Gynecology. 158(6,2),1630-1643.

3. Sinha Hikim, A.P. and Hoffer, A.P.( 1987). Quantitative analysis of germ cells and leydig cells in rat made infertile with gossypol. *contraceptive* 35(4),395-408.
4. Riahinejad, S. et al. (2014). The comparative study of Yaz and Ovocept-1d on patients with simple ovarian cysts referring to Iran-Isfahan Shariati Hospital. *Adv. Biomed. Res.* , 1-8
5. Khamees, N.H., et al. ( 2012). Effects of combined oral contraceptives on the skin of mice. *Turk J Med Sci.* 48(2),1528-1537.
6. Wright, K. P. and Johnson, J. V.(2008). Evaluation of extended and continuous use oral contraceptives. *Ther Clin Risk Manag.* 4(5), 905–911.
7. Sohrabi, M.R. et al. (2010). Application of H-point standard additions method for simultaneous determination of levonorgestrel and ethinylestradiol in oral contraceptive LD. *J.of Applied Sci.* 10(16),1802-1805.
8. del Marmol, J. et al. (2004). The role of combined oral contraceptives in the management of acne and seborrhea. *Eur. J. Contracept Reprod Health Care.* 9, 107–24.
9. Edelman, A. et al. ( 2010). Combined oral contraceptives and body weight: do oral contraceptives cause weight gain? A primate model. *J. Hum. Reprod.* 4, 60–2.
10. de Voogt, H. et al.(1986). Cardiovascular side effects of diethylstilbestrol, cyproteroneacetate, medroxyprogesterone acetate and estramustine phosphate used for the treatment of advanced prostatic cancer. *J. Urol.* 2, 303–7.
11. Hall, G.and Phillips, T.(2005). Estrogen and skin: the effects of estrogen, menopause and hormone replacement therapy on the skin. *J. Am. Acad. Derm.* 53, 555–68.
12. Guy, R. et al. (1996).The improved organ maintenance of the human sebaceous gland: modeling in vitro the effects of epidermal growth factor, androgens, estrogens, 13-cis retinoic acid, and phenol red. *J. Invest. Dermatol.* 106, 454–60.