

Protective and Ameliorating Effects of Methanolic Seed Extract of *Mucuna Pruriens* on Paraquat Induced Testicular Damage

Uozie Chikere Ofoego^{1*} Ezinne Uchechi Ekwujuru² Agnes Nwakanma³ Ikechukwu Smart Mbagwu¹
Elizabeth Obioma Nweke³ Chike Ikechukwu Patrick Anibeze⁴

1.Department of Anatomy, Faculty of Basic Medical Sciences, Nnamdi Azikiwe University, Nnewi Campus, Anambra State, Nigeria

2.Department of Biotechnology, Federal University of Technology, Owerri, Imo State, Nigeria

3.Department of Anatomy, Faculty of Basic Medical Sciences, Chukwuemeka Odumegwu Ojukwu University, Anambra State, Nigeria

4.Department of Anatomy, Faculty of Basic Medical Sciences, Enugu State University, Enugu, Nigeria

Abstract

Paraquat has been known to induce damage to the testes and ovaries in different animals. This study evaluated the protective and ameliorating effects of methanolic seed extract of *Mucuna pruriens* (MSEMP) on paraquat induced testicular damage. Healthy adult male Albino Wistar rats received paraquat alone, or paraquat and MSEMP together. All substrates were administered orally. Results obtained showed that mean epididymal sperm count, sperm motility, testosterone, follicle stimulating hormone (FSH), and luteinizing hormone (LH) levels were reduced ($p < 0.05$), in addition to alterations in sperm morphologies in all rats that received paraquat alone in a duration dependent manner. However, all parameters were improved in groups treated with paraquat and MSEMP together. Histological investigations of the testes revealed necrotic testicular tissue, with testicular atrophy, loss of sperm bundles and scanty spermatocytes in all rats that received paraquat alone. However, Co- and post-treatment of the animals with MSEMP following oral administration of paraquat showed protective and ameliorative characteristics. One of the possible mechanisms that could be attributed to this observation would be the action of L-Dopa present in *Mucuna pruriens*, although complete mechanism of action of these effects is not yet clear and calls for further investigation.

Keywords: Testosterone, Sperm count, L-Dopa.

1. Introduction

The practice of plant use as an alternative source medicine today cannot be over emphasized. *Mucuna pruriens* (Velvet bean) is an annual tropical leguminous shrub notorious for the extreme itchiness it produces on contact with the hair on its young foliage and seed pods (Andersen *et al.*, 2015; Yerra *et al.*, 2005). However, it has an inestimable value in agriculture and horticulture, and has a wide range of medicinal properties (Whitbread *et al.*, 2004).

In traditional medicine, preparations from the seeds are used for the management of several free radical-mediated diseases, such as rheumatoid arthritis, diabetes, atherosclerosis, nervous disorders, male infertility, snake bites, stress and Parkinson disease (Katzenschlager *et al.*, 2004; Rajeshwar *et al.*, 2005; Suresh *et al.*, 2009; Tan *et al.*, 2009; Sekar *et al.*, 2009; Lieu *et al.*, 2010).

Mucuna pruriens has been reported to have a dose dependent effect on the concentration of reproductive hormones, increases secretion of semen and acts as a restorative and an invigorating tonic (aphrodisiac) in diseases characterized by weakness or loss of sexual power (Sundararajan *et al.*, 2013; Muthu and Krishnamoorthy, 2011; Suresh *et al.*, 2009; Kumar *et al.*, 1994).

Paraquat (N,N'-dimethyl-4,4'-bipyridinium dichloride) is an organic compound widely used as a herbicide. A variety of related compounds (1-Hexadecanaminium, N,N,N-trimethylchloride, and bis-hydrogenated tallow alkyldimethyl chlorides) are used in the textiles industry and in hair conditioners (Hamay *et al.*, 2012). As a potent herbicide, it acts by inhibiting photosynthesis, while producing destructive reactive oxygen species. It is quick-acting and non-selective, killing green plant tissue on contact (Dinis-Oliveira *et al.*, 2006). In light-exposed plants, paraquat accepts electrons from photosystem I (more specifically Fd, which is presented with electrons from PS I) and transfers them to molecular oxygen. In this manner, destructive reactive oxygen species are produced. In forming these reactive oxygen species, the oxidized form of paraquat is regenerated, and is again available to shunt electrons from photosystem I to start the cycle again (Summers, 1980).

Paraquat is often used in science to catalyze the formation of superoxide free radical, a potent reactive oxygen species (ROS). Paraquat undergoes redox cycling *in vivo*, and is reduced by an electron donor such as NADPH, before being oxidized by an electron receptor such as dioxygen to produce superoxide, a major reactive oxygen species (ROS) (Bus *et al.*, 1984).

Reports have shown its toxic effects on both human and experimental animals by its contribution to the development of neurological conditions (Kamel, 2013) as well as its effect on the reproductive systems of males (D'Souza *et al.*, 2006; Nasibeh *et al.*, 2015) and females (Vahid *et al.*, 2012). Even a single swig, immediately

spat out, can cause death from fibrous tissue developing in the lungs, leading to asphyxiation (suffocation) (Buzik *et al.*, 1997).

Testicular evaluations on experimental animals after paraquat exposure have shown significant decrease in spermatocyte, spermatids and Leydig cells (D'Souza *et al.*, 2006; Nasibeh *et al.*, 2015). In female experimental animals, exposure to paraquat showed a significant alternation in ovarian weight and blood levels of LH and FSH, with significant decrease in the number of primordial, primary and growing follicles, as well as the corpus luteum and its cells (Vahid *et al.*, 2012).

As a result of this and the widespread exposure of farmers to paraquat, this research is aimed at investigating the protective and ameliorating effects of *Mucuna pruriens* on paraquat induced testicular damage.

2. Materials and Methods

2.1. Housing and Care of Experimental Animals

Sixty (60) male albino wistar rats weighing between 115g to 230g were procured from the Animal House of Abia State University, Uturu, Nigeria and used for this research which lasted for 42 days. The rats were housed in well ventilated wooden cages and fed with normal rat chow (Guinea Feeds PLC) and distilled water *ad libitum* and allowed to acclimatize for two weeks. Their health status was closely monitored before and during the experiment. All procedures were carried out in strict accordance with the institutional guidelines on the care and use of experimental animals.

2.2. Preparation of plant extract

Mature pods of *Mucuna pruriens* growing as weed were obtained from cassava farms in Oguta and Njaba Local Government Areas, both in Imo State, Nigeria and identified by a Botanist. The pods were carefully cracked open to avoid skin contact with the hairs of the pod. The seeds obtained were shade dried under ambient temperature and grinded using Laboratory Mill. Methanol extraction was carried out. The extract was filtered with Whatman filter paper No 1 and concentrated at 40°C using a rotary evaporator. The extract obtained was stored in a refrigerator at 4°C and was later reconstituted to get the desired stock.

2.3. Procurement and Reconstitution of Paraquat

Paraquat solution in the form of Paraquat Dichloride (276g/l) (Springfield Agro LTD, Apapa, Lagos) was purchased from the Agro-allied section of New Market Owerri, Imo State, Nigeria, and reconstituted to the desired stock.

2.4. Toxicity Test for Methanolic Extract of *Mucuna pruriens* Seed and Paraquat

Acute toxicity studies of Methanolic extract of *Mucuna pruriens* seed and Paraquat were carried out by employing a modified method described by Lorke (Lorke, 1983). The LD₅₀ for the oral administration of methanolic extract of *Mucuna pruriens* seed and paraquat in Wistar rats were found to be 2.2g/kg b. wt. and 50g/kg b. wt. respectively.

2.5. Experimental protocol

35 male Albino Wistar rats weighing between 160-220g were grouped into seven (A-G) groups of five animals each. Group A (control) received feed and distilled water *ad libitum* for 42 days. Group B and C received 400mg/kg of methanolic seed extract of *Mucuna pruriens* (MSEMP) and 20mg/kg of paraquat once daily for 42 days respectively. Group D received 20mg/kg of paraquat once daily for 21 days and then were sacrificed. Group E received 20mg/kg of paraquat once daily for 21 days after which paraquat was withdrawn and rats fed with water and normal feed *ad libitum* till day 42. Group F received 20mg/kg of paraquat once daily for 21 days after which paraquat was withdrawn and rats fed with 400mg/kg of MSEMP once daily till day 42, while group G received a co-administration of 20mg/kg of paraquat and 400mg/kg of MSEMP once daily for 42 days. All substrates were administered orally.

2.6. Hormonal Assay

At the end of the experiment, blood samples were collected via ocular puncture and assayed for levels of testosterone, follicle stimulating hormone (FSH), and luteinizing hormone (LH), using the Microwell enzyme linked immunoassay (ELISA) technique, and analytical grade reagents (Syntron Bioresearch Inc., USA).

2.7. Analysis of Sperm parameters

Sperm parameters such as sperm count, sperm motility, and sperm morphology were analyzed according to methods described by World Health Organization (WHO, 1999).

2.8. Histological Analysis

The fixed testes were processed for routine microtomy, photomicroscopic observations and interpretations. The testes were fixed in freshly prepared Bouin's fluid, dehydrated in ascending grades of ethanol (50%-100%), cleared in xylene and embedded in paraffin wax. Afterwards, thin sections (5-6 mm) were made and then stained with hematoxylin and eosin dye for photomicroscopic observations and interpretations.

2.9. Statistical analysis

Results obtained from this study were analyzed using IBM SPSS Version 20. Analysis of variance (ANOVA) was used to compare means, and values were considered significant at $P < 0.05$. Post Hoc multiple comparisons for differences between groups within groups were established using least significant difference (LSD). With results presented as Mean \pm S.E.M.

3.0. Results and Discussion

3.1. Testicular weight

Table 3.1: Mean values of Testicular weights obtained at the end of the experiment

S/N	Group	Relative Testicular Weight (g) \pm S.E.M
1	A	0.79 \pm 0.07
2	B	0.79 \pm 0.07
3	C	0.56 \pm 0.05*
4	D	0.78 \pm 0.01
5	E	0.73 \pm 0.06
6	F	0.72 \pm 0.06
7	G	0.76 \pm 0.07

*= $p < 0.05$ when comparing with A (Control)

Table 3.1 shows that there was no much differences between the relative mean testicular weight values obtained in all the experimental groups except for C (administered 20mg/kg of paraquat for 42 days), that showed reduction in relative testicular weights. This loss in testicular weight resulting from a long exposure period to paraquat can be associated with a corresponding distortion of the testicular cytoarchitecture as shown in their photomicrographs. Previous studies have shown that paraquat destroys the cytoarchitecture of the testes and its associated seminal parameters (D'Souza *et al.*, 2006; Nasibeh *et al.*, 2015; Zain, 2007; Perla *et al.*, 2008; Deepananda and De Silva, 2013). Exposure of animals to paraquat has been reported to causes oxidative stress through the production of reactive oxygen species (ROS), such as free radicals and hydrogen peroxide. When the rate of production of ROS exceeds the body's ability to neutralize and eliminate, antioxidant defenses such as glutathione are overwhelmed, causing DNA damage, and cell and tissue death (Ray *et al.*, 2007).

3.2. Hormonal assay

Table 3.2: Mean values of Testosterone, Follicle Stimulating hormone (FSH), and Luteinizing hormone (LH), obtained at the end of the experiment.

S/N	Group	Testosterone (ng/ml) \pm S.E.M	FSH (Miu/ml) \pm S.E.M	LH (mIU/ml) \pm S.E.M
1	A	2.33 \pm 0.12	1.69 \pm 0.12	1.19 \pm 0.02
2	B	2.47 \pm 0.09	1.87 \pm 0.08*	1.23 \pm 0.04
3	C	0.63 \pm 0.07*	0.56 \pm 0.04*	0.91 \pm 0.02*
4	D	0.93 \pm 0.09*	0.76 \pm 0.03*	0.89 \pm 0.06*
5	E	1.27 \pm 0.07*	0.84 \pm 0.05*	0.98 \pm 0.06*
6	F	1.57 \pm 0.09*	1.63 \pm 0.04	1.08 \pm 0.01
7	G	1.90 \pm 0.10*	1.44 \pm 0.06*	1.08 \pm 0.02

*= $p < 0.05$ when compared with group A (Control)

Table 3.2 shows that animals in group B (*Mucuna pruriens* for 42 days) had the highest obtained values for testosterone, FSH, and LH. This was followed by the Control group (A), while groups that received paraquat alone (C, D, and E) had the least obtained values for testosterone, FSH, and LH.

A possible mechanism for the reduction in the hormones in groups that received paraquat alone irrespective of the duration of oral exposure can be attributed to the inhibition of 17-beta estradiol by paraquat, leading to an alteration in pathway for steroidogenesis. This is caused by oxidative stress via the production of reactive oxygen species (ROS) that overwhelms antioxidant defenses, causing DNA and mitochondrial damages, and leading to interruption of relevant biochemical processes and tissue necrosis (Ray *et al.*, 2007; Quassinti *et al.*, 2009 ;

Suntres, 2002; Cocheme and Murphy, 2009).

On the other hand, methanolic seed extract of *Mucuna pruriens* alone and its co-administration with paraquat yielded high serum levels of testosterone FSH and LH, better sperm quality in terms of count, motility and morphology as well as better histological observations. This indicates a possible salvaging effect on the oxidative stress, cell apoptosis and tissue necrosis induced by paraquat ingestion from damage thus a suggestion that methanolic seed extract of *Mucuna pruriens* possesses protective and ameliorative capacity.

Treatment of infertility with elements of psychological stress using *Mucuna pruriens* seed powder was reported to restore to normal, the levels of Super Oxide Dismutase (SOD) (an important antioxidant defense), catalase (an important enzyme that catalyses the decomposition of hydrogen peroxide to hydrogen and water), glutathione (GSH) (an important antioxidant that prevents damage to cellular components caused by reactive oxygen species such as free radicals) and ascorbic acid in seminal plasma of infertile men (Shukla *et al.*, 2009).

3.3. Sperm parameters

Table 3.3: Mean values of sperm count and sperm motility of various groups obtained at the end of the experiment.

S/N	Group	Mean Sperm Count ($\times 10^6$) \pm S.E.M	Mean Sperm Motility (%) \pm S.E.M
1	A	59.00 \pm 0.58	81.33 \pm 1.45
2	B	63.33 \pm 1.20*	80.00 \pm 1.15
3	C	27.00 \pm 0.58*	29.33 \pm 0.67*
4	D	32.67 \pm 1.45*	47.67 \pm 1.45*
5	E	36.33 \pm 0.67*	50.67 \pm 1.45*
6	F	41.67 \pm 1.20*	55.67 \pm 0.88*
7	G	49.00 \pm 1.53*	65.67 \pm 2.96*

*= $p < 0.05$ when compared with group A (Control)

Table 3.3 shows that experimental animals in group B (*Mucuna pruriens* for 42 days) had the highest mean sperm count followed by group A (control) and G (combined/co-administration of paraquat and *Mucuna pruriens* for 42 days) respectively, while the least mean sperm count values were obtained in groups that received paraquat alone (C, D, and E). Mean sperm motility was highest in group A, followed by groups B, G, and F, while least value was observed in group C.

Active constituents of *Mucuna pruriens* seeds especially L-Dopa increases testosterone levels and, as a result helps to improve spermatogenic and steroidogenic activities. It does so by enhancing testicular cells, stimulating the secretion of gonadotropin-releasing hormone (GnRH) from the forebrain and hypothalamus (Sundararajan *et al.*, 2013). High GnRH levels stimulate the anterior pituitary gland to produce the luteinizing hormone (LH) and follicle-stimulating hormone (FSH), which in turn enhances testosterone synthesis (Ahmad *et al.*, 2007). Increased testosterone levels in turn increases not only sperm count, but also improves sperm quality.

On the other hand, reductions in mean sperm count and motility obtained in groups that received paraquat alone could be as a result of oxidative stress produced by paraquat that caused interruptions in important biochemical processes, as well as cell and tissue deaths. This agrees with the findings of other authors (Ray *et al.*, 2007; Quassinti *et al.*, 2009 ; Suntres, 2002; Cocheme and Murphy, 2009).

Table 3.4: Sperm Morphology of Various Groups

S/N	Group	Normal (%) \pm S.E.M	Abnormal Head (%) \pm S.E.M	No Head (%) \pm S.E.M	Abnormal Tail (%) \pm S.E.M	No Tail (%) \pm S.E.M
1	A	80.67 \pm 1.53	6.00 \pm 1.00	4.00 \pm 1.00	7.00 \pm 1.00	2.33 \pm 0.67
2	B	80.67 \pm 0.88	6.33 \pm 0.67	3.67 \pm 0.67	7.00 \pm 0.58	2.33 \pm 0.67
3	C	61.00 \pm 3.61*	15.00 \pm 3.00*	5.67 \pm 1.15	11.00 \pm 1.00*	7.33 \pm 1.20*
4	D	72.67 \pm 2.52*	10.00 \pm 1.00*	5.00 \pm 1.00	7.67 \pm 1.15	4.67 \pm 0.33
5	E	73.00 \pm 2.65*	10.33 \pm 0.58*	5.00 \pm 1.00	8.00 \pm 1.00	3.67 \pm 0.33
6	F	75.67 \pm 1.20	8.00 \pm 0.58	5.33 \pm 0.67	8.00 \pm 0.58	3.00 \pm 0.58
7	G	79.33 \pm 1.76	6.00 \pm 1.00	4.33 \pm 0.88	6.33 \pm 1.20	4.00 \pm 0.58

*= $p < 0.05$ when compared with group A (control)

Table 3.4 also shows that experimental animals in groups that received paraquat alone (C, D, and E) had a significant reduction in the percentage of normal sperm cells, and a statistically significant increase in percentage of sperm cells with abnormal head, when compared with control. Group C (paraquat for 42 days) also had a significant increase in percentage of sperm cells with abnormal tail when compared with control. While the groups that received *Mucuna pruriens* either alone or in combination with paraquat showed a better sperm morphology.

The morphogenic alterations observed in groups that were given paraquat could be due to paraquat's interference in the normal metamorphosis of germ cells into structurally mature normal sperm cells. Though the

complete mechanism through which paraquat exerts these negative effects is not yet clear, although reports suggest that the production of reactive oxygen species (ROS) produced by paraquat causes DNA and mitochondrial damages, as well as interruptions to relevant biochemical processes and tissue necrosis (Ray *et al.*, 2007; Quassinti *et al.*, 2009; Suntres, 2002; Cocheme and Murphy, 2009).

In groups that received *Mucuna pruriens* alone or in combination with paraquat, the protective and ameliorative ability of *Mucuna pruriens* could be through the activities of L-Dopa present in *Mucuna pruriens* (Muthu and Krishnamoorthy, 2011; Sundararajan *et al.*, 2013; Shukla *et al.*, 2009; Ahmad *et al.*, 2007). L-Dopa increases testosterone levels and, as a result helps to improve spermatogenic and steroidogenic activities by enhancing testicular cells and their secretions (Sekar *et al.*, 2009).

Histological findings

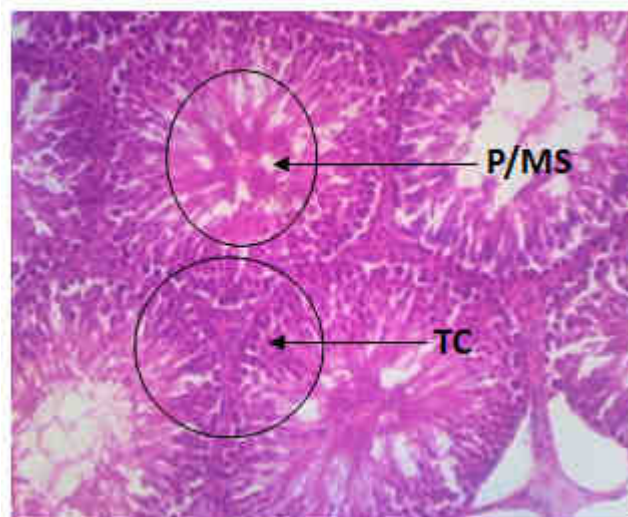


Fig. 1: Control Group (X150) (H/E)

Figure 1: Photomicrograph of the testis of Group A (control) fed with feed and water only (X150)(H/E) shows normal testicular architecture with testicular cells (TC), and production and maturation of spermatozoa (P/MS).

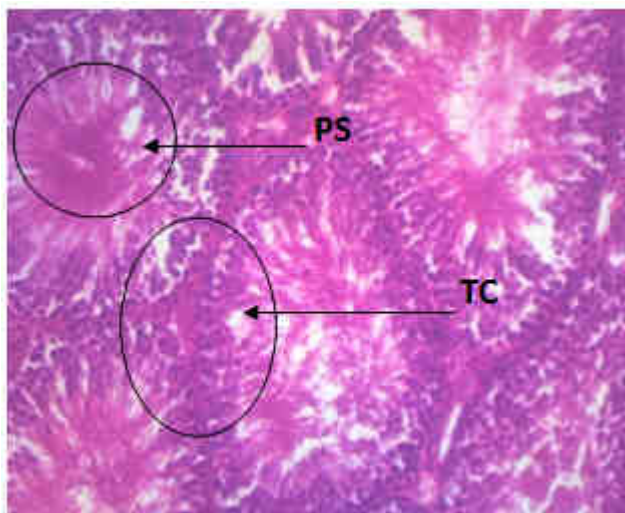


Fig. 2: Group B (X150) (H/E)

Figures 2: Photomicrograph of testis of Group B rats administered with 400mg/kg body weight of *Mucuna pruriens* for 6 weeks (X150)(H/E) shows improved testis with well enhanced testicular cells (TC), and production of spermatozoa (PS).

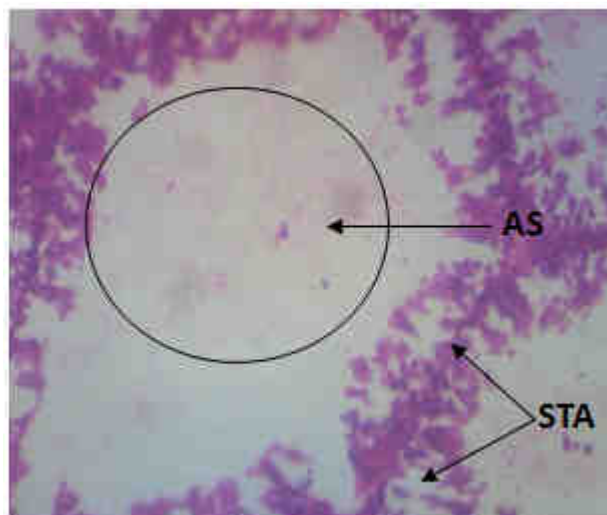


Fig. 3: Group C (X150) (H/E)

Figure 3: Photomicrograph of testis of Group C rats administered with 20mg/kg of paraquat for 6weeks (X60/150) (H/E), shows severe damage of the testicular tissue with severe testicular atrophy (STA), and arrest of spermatogenesis (AS).

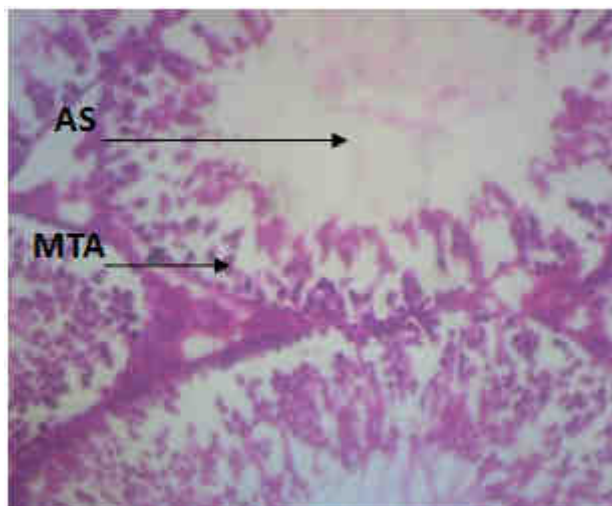


Fig. 4: GROUP D (X150) (H/E)

Figure 4: Photomicrograph of testis of Group D rats administered with 20mg/kg of paraquat for 3weeks and then sacrificed (X150) (H/E) shows moderate distortion of testicular architecture with arrest of spermatogenesis (AS) and moderate testicular atrophy (MTA).

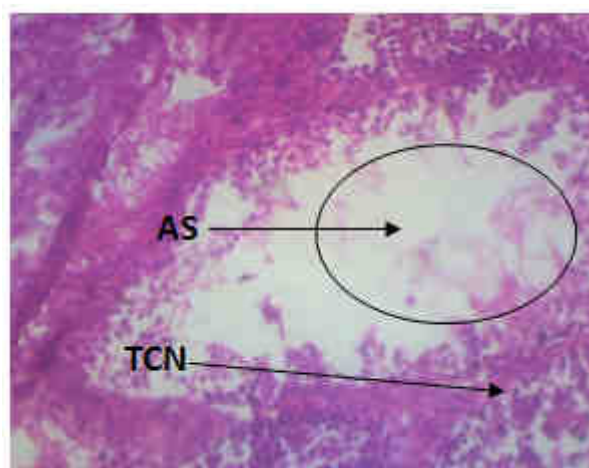


Fig. 5: GROUP E (X150) (H/E)

Figure 5: Photomicrograph of testis of Group E rats administered with 20mg/kg paraquat for 3 weeks after which paraquat was withdrawn and rats fed with feed and water for another 3 weeks shows moderate testicular damage with testicular cells necrosis (TCN), and arrest of spermatogenesis (AS).

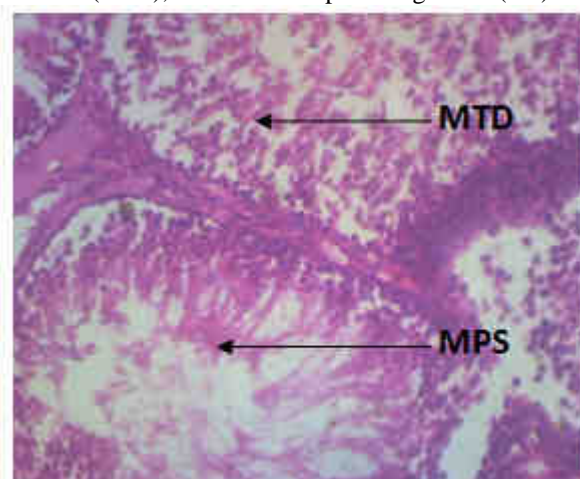


Fig. 6: GROUP F (X150) (H/E)

Figure 6: Photomicrograph of testis of Group F administered with 20mg/kg body weight of paraquat for 3 weeks after which it was withdrawn and rats treated with 400mg/kg of methanolic seed extract of *Mucuna pruriens* (x60/150) (H/E) shows mild testicular damage with mild testicular distortion (MTD). However there are areas of moderate regeneration with moderate production of spermatozoa (MPS).

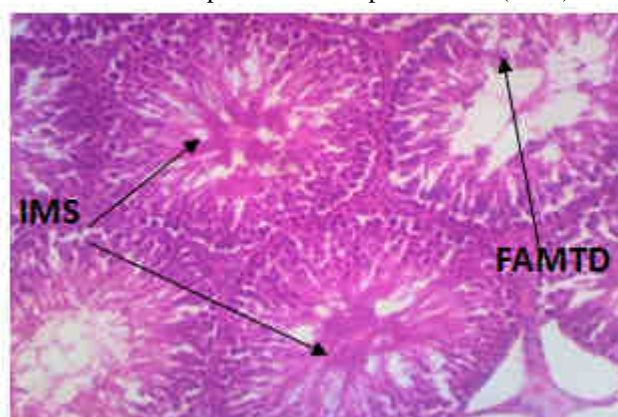


Fig. 7: GROUP G (X150) (H/E)

Figure 7: Photomicrograph of testis of Group G rats, co-administered with 20mg/kg body weight of paraquat and 400mg/kg of methanolic seed extract of *Mucuna pruriens* for 6 weeks (x60/150) (H/E) shows improved testicular regeneration with increased maturation of spermatozoa (IMS). However there are still focal areas of mild testicular distortion (FAMTD).

5.0. Conclusion

Oral administration of paraquat to male wistar rats induced moderate to severe disturbances and alterations in testicular parameters of male wistar rats such as reduced sperm count, reduced sperm motility, and sperm morphology in a duration dependent manner. Serum levels of male androgens such as testosterone, follicle stimulating hormone (FSH), and luteinizing hormone (LH) were also altered. Histopathological findings also revealed that paraquat caused marked alterations in testicular architecture, ranging from mild to severe. However, administration of graded doses of methanolic seed extract of *Mucuna pruriens* independently as well as in combination with paraquat caused marked improvements, recoveries, and protection on the testes, as most of the alterations and disturbances in male androgens and testicular architecture observed in animals exposed to oral administration of paraquat were restored to control or near normal control levels faster when compared to withdrawals. The findings of this study suggest that continual exposure to paraquat is deleterious and cause alterations in testicular parameters which could lead to reduced fertility. However, administration of extracts of *Mucuna pruriens* seed provided soothing and perhaps ameliorating effects on testicular alterations caused by deliberate, occupational, or accidental oral paraquat exposure, and by such doing improves fertility.

Acknowledgement

We appreciate the financial help rendered by Honorable Bennett and Dr (Mrs) Chinyere Ofoego. We also appreciate the help rendered by Professor CIP Anibeze, and Mr. Nwajiagu Godwin Ike towards making this research a success.

References

- Ahmad K.M., Mahdi A.A., Shukla K.K., Islam N., Jaiswar P.S., and Ahmad S. (2007), Effect of *Mucuna pruriens* on semen profile and biochemical parameters in seminal plasma of infertile men. *Fertility and sterility.*, 90(3), 627-35.
- Andersen H.H., Elberling J., and Arendt-Nielsen L. (2015), Human surrogate models of histaminergic and nonhistaminergic itch. *ActaDermatoVenereologica.*, 95(7), 771-779.
- Bus J.S., Gibson J.E. (1984), "Paraquat: model for oxidant-initiated toxicity". *Environmental Health Perspectives*; 55, 37-46.
- Buzik S.C., Schiefer H.B., Irvine D.G. (1997), *Understanding Toxicology: Chemicals, Their Benefits and Risks.* Boca Raton: CRC Press. p. 31.
- Cocheme H.M., and Murphy M.P. (2009), The uptake and interactions of the redox cycler paraquat with mitochondria. *Method Enzymol.*, 456, 395-417.
- D'Souza U.J.A., Narayana K., Zain A., Raju S., Nizam H.M., and Noriah O. (2006), Dermal exposure to the herbicide-paraquat results in genotoxic and cytotoxic damage to germ cells in the male rat. *Folia Morphol.*, 65(1), 6-10.
- Deepananda K.H.M.A., and De Silva W.A.J.P. (2013), Mechanism of Paraquat Action Shows Interference in Spermatogenesis and Epididymal Maturation of Sperm in Mice. *Journal of Biology.*, 01(03), 67-76.
- Dinis-Oliveira R.J., Remião F., Carmo H., Duarte J.A., Navarro A.S., Bastos M.L., and Carvalho F. (2006), Paraquat exposure as an etiological factor of Parkinson's disease. *Neurotoxicology.*, 27(6), 1110-22.
- Hamay A.V., Najafiyan M., Farzam M., and Kargar H. (2012), Effects of the Paraquat Herbicide on Oogenesis and Ovary Structure of Wistar Rat Strain. *Advances in Environmental Biology.*, 6(3), 1006-1012.
- Kamel F. (2013), Paths from Pesticides to Parkinson's. *Science.*, 341(6147), 722-723.
- Katzenschlager R., Evans A., Manson A., Patsalos P.N., Ratnaraj N., Watt H., Timmermann L., Van Der Giessen R., Lees A.J. (2004), *Mucuna pruriens* in Parkinson's disease: a double blind clinical and pharmacological study. *Journal of Neurology, Neurosurgery & Psychiatry.*, 75(12), 1672-7.
- Kumar K.V.A., Srinivasan K.K., Shanbhag T., and Rao S.G. (1994), Aphrodisiac activity of the seeds of *Mucun apruriens*. *Indian Drug.*, 31, 321-327.
- Lieu C.A., Kunselman A.R., Manyam B.V., Venkiteswaran K., and Subramanian T. (2010), A water extract of *Mucuna pruriens* provides long-term amelioration of parkinsonism with reduced risk for dyskinesias. *Parkinsonism & Related Disorders.*, 16(7), 458-65.
- Lorke D. (1983), A New Approach to Practical Acute Toxicity Testing. *Arch Toxicol* 54(4), 275-87.
- Muthu K., and Krishnamoorthy P. (2011), Evaluation of androgenic activity of *Mucuna pruriens* in male rats. *African Journal of Biotechnology.*, 10(66), 15017-15019.
- Nasibeh F., Mohammad H., Morteza H., and Akram R. (2015), Effects of paraquat on testicular histomorphometry of male rats. *Biological Forum.*, 7(2), 573-575.
- Perla V., Perrin N.A., and Greenlee A.R. (2008), Paraquat toxicity in a mouse embryonic stem cell model. *Toxicol in Vitro.*, 22, 515-24.
- Quassinti L., Maccari E., Murri O., and Bramucci M. (2009), Effects of paraquat and glyphosate on steroidogenesis in gonads of the frog *Rana esculenta* in vitro. *PesticBiochemPhysiol.*, 93, 91-5.

- Rajeshwar Y., Kumar G.P.S., Gupta M., Mazumder U.K. (2005), Studies on in vitro antioxidant activities of methanol extract of *Mucuna pruriens* (Fabaceae) seeds. *Eur. Bull. Drug Res.*, 13(1), 31-39.
- Ray S., Sengupta A., and Ray A. (2007), Effects of paraquat on anti-oxidant system in rats. *Ind J ExperBiol.*, 45, 432-8.
- Sekar S., Prithiviraj E., and Prakash S. (2009), Dose and time dependent effects of ethanolic extract of *Mucuna pruriens* Linn. seed on sexual behaviour of normal male rats. *Journal of Ethnopharmacol.*, 122, 497–501.
- Shukla K.K., Mahdi A.A., Ahmad M.K., Shankhwar S.N., Rajender S., and Jaiswar S.P. (2009), *Mucuna pruriens* improves male fertility by its action on the hypothalamus-pituitary-gonadal axis. *FertilSteril.*, 92(6), 1934-40.
- Summers L.A. (1980), *The Bipyridinium Herbicides*. Academic Press, New York, NY.
- Sundararajan M., Lakshmanan G.M.A., Shanmugam M., *et al.*, (2013), Screening and Evaluation of the Effect of Exogenous Application of ABA and Propiconazole on the Antioxidant potential of *Mucuna pruriens* seed Extracts. *Journal of Applied Pharmaceutical Sciences.*, 3(04), 043-047.
- Suntres Z.E. (2002), Role of antioxidants in paraquat toxicity. *Toxicology.*, 168, 65-77.
- Suresh S., Prithiviraj E., and Prakash S. (2009), Dose- and time-dependent effects of ethanolic extract of *Mucuna pruriens* Linn. seed on sexual behaviour of normal male rats. *Journal of Ethnopharmacology.*, 22, 497–501.
- Tan N.H., Fung S.Y., Sim S.M., Marinello E., Guerranti R., and Aguiyi J.C. (2009), *The protective effect of Mucuna pruriens seeds against snake venom poisoning*. *Journal of Ethnopharmacology.*, 123 (2), 356–8.
- Vahid H.A., Mahmood N., Mohammad F., and Hossin K. (2012), Effect of the Paraquat Herbicide on Oogenesis and Ovary Structure of Wistar Rat Strain. *Advances in Environmental Biology.*, 6(3), 1006-1012.
- Whitbread A.M., Jiri O., and Maasdorp B. (2004), The effect of managing improved fallows of *Mucuna pruriens* on maize production and soil carbon and nitrogen dynamics in sub-humid Zimbabwe. *Nutrient Cycling in Agroecosystems.*, 69, 59-71.
- World Health Organization (1999), *Laboratory manual for Examination of Human Semen and Semen-Cervical Mucus Interaction*. 4th ed. Cambridge University Press; pp. 1–10.
- Yerra R., Malaya G., and Upal K. (2005), "In Vitro Lipid Peroxidation and Antimicrobial Activity of *Mucuna pruriens* Seeds". *Iranian Journal of Pharmacology & Therapeutics.*, 4, 32–35.
- Zain A. (2007), The evaluation of the toxic effect of paraquat and its mechanism of action on reproductive system of male rats. Thesis.UniversitiSains Malaysia, Penang (2007).http://eprints.usm.my/9548/1/THE_EVALUATION_OF_THE_TOXIC_EFFECT_OF_PARAQUAT.