

Patient with Wolff-Parkinson-White Syndrome undergoing Non-Cardiac Surgery. Perioperative Management

Merita Zeka¹ Marsela Goga² Saimir Kuci^{2*} Alfred Ibrahim² Ervin Bejko² Krenar Lilaj³

1. Department of Anesthesia and Intensive Care., Department of Cardiovascular Surgery.

Hygeia Hospital Tirana

2. Department of Anesthesia and Intensive Care., Department of Cardiovascular Surgery.

University Hospital Center "Mother Theresa" Tirana

3. Department of Anesthesia and Intensive Care., Department of General Surgery.

University Hospital Center "Mother Theresa" Tirana

*Corresponding author: Asc. Prof. Dr. Saimir Kuci MD, Ph.D.

*saimirkuci@gmail.com

Department of Anesthesia, University Hospital Centre "Mother Teresa" Tirana, Albania

Abstract: Background: Perioperative management of patients with preexcitation may become quite challenging, especially if there is no time for adequate preoperative investigation and clinical optimization, as in emergencies, or even worse, in undiagnosed cases. It is possible that the poorly controlled or unknown underlying electrophysiological abnormality will become unmasked during anesthesia and surgery, giving rise to potentially life-threatening arrhythmias.

In the literature, pre-excitation syndromes have been mainly approached from the view of the disease (i.e., presentation, diagnosis, treatment), while anesthetic data are scarce. This case report aims to focus on the perioperative management of patients with WpW.

Conclusion; Managing such cases provides an opportunity to revisit important considerations on Wolff-Parkinson-White syndrome avoiding neuromuscular blockers may make a difference in avoiding arrhythmias when laryngeal mask airway / general anesthesia is required in patients with Wolff-Parkinson-White syndrome. sympathetic stimulation should be avoided as it may shorten the refractory period of ap and alleviate life-threatening arrhythmias.

Keywords: WpW, arrhythmias, bundle of Kent, anesthesia

DOI: 10.7176/ALST/95-03

Publication date: November 30th 2022

Abbreviations

LMA - Laryngeal Mask Airway; GA - General Anaesthesia; WPW - Wolff-Parkinson-White; ETT - Endotracheal Tube; SVT - Supraventricular Tachycardia; EPS - Electrophysiology Studies; APs - accessory pathways; ECG - electrocardiogram; RFCA - radiofrequency catheter ablation; BMI - Body Mass Index; PR - Pulse Rate; BP Blood Pressure; AV - Atrioventricular; PRKAG2 - Protein Kinase AMP-Activated Non-Catalytic Subunit Gamma 2; NMBs - Neuromuscular Blockers;

Original article, no submission or publication in advance or in parallel

Introduction

Perioperative management of patients with preexcitation may become quite challenging, especially if there is no time for adequate preoperative investigation and clinical optimization, as in emergencies, or even worse, in undiagnosed cases. It is possible that the poorly controlled or unknown underlying electrophysiological abnormality will become unmasked during anaesthesia and surgery, giving rise to potentially lifethreatening arrhythmias.

Patients with Wolff-parkinson-White (WpW) syndrome may require anaesthesia for eps/ablation or for non-ablative procedures. In diagnostic/therapeutic interventions, anaesthetics should not interfere with cardiac electrophysiology, while in non-ablative surgery, drugs should ideally prevent, or at least, not facilitate the generation of arrhythmias associated with aps.

Suspicious cases should be referred for further investigation before elective surgery. a detailed cardiac history during pre-anaesthetic evaluation is the corner stone of not missing undiagnosed patients [5]. apart from a 12lead ECG, Holter monitoring may be useful, especially in intermittent WpW. echocardiography can reveal congenital cardiac abnormalities that coexist in 7-20% of patients, such as ebstein's anomaly, valve lesions, cardiac hypertrophy, atrial aneurysms and septal defects [3, 4, 10]. an eps may also be needed; the benefit of postponing an elective surgery for eps testing should be examined. the capability of rapid anterograde ap conduction increases the risk of sudden death and is an indication for radiofrequency catheter ablation (RFCA) to

precede surgery [10]. Diagnosed patients should be carefully assessed preoperatively regarding their symptoms and current treatment, and should be clinically optimised. Cardiological consultation and close cooperation are mandatory for a safe management plan.

In the literature, pre-excitation syndromes have been mainly approached from the view of the disease (i.e., presentation, diagnosis, treatment), while anaesthetic data are scarce. this case report aims to focus on the perioperative management of patients with WpW.

Case Presentation

A 38-year-old woman, with a BMI of 25.5 presented at the clinic for plastic breast surgery. In the anamnesis the patient refers as concomitant disease, hyperthyroidism, WpW syndrome and insomnia. she reports being under chronic treatment with Methimazole 5 mg x 2 tb / day, Bisoprolol 2.5 mg, 2x 1 tb / day, and Melatonin 10 mg x 1 tb / day. the patient refers a miscarriage in 2018 and in 2019 she underwent a lower segment cesarean section under spinal anaesthesia for the delivery of her first child, during which period the patient was asymptomatic and surgery was uneventful. Further cardiological evaluation revealed WpW syndrome at admission for plastic surgery, she was asymptomatic with good exercise tolerance the general and systemic examination revealed a pulse rate (pR) of 70 beats per minute, a blood pressure (Bp) of 110/80 mm Hg. the electrocardiograph (eCG) showed normal sinus rhythm, a heart rate of 85/minute, shortened p-R interval (<0.12 seconds), a widened initial QRs complex with slurred upstroke and a normal terminal QRS deflection (Figure 1). Chest X-Ray and laboratory investigations including a haemogram, liver function tests, renal function tests, serum electrolytes and coagulation profiles were normal. 2D- echocardiogram revealed normal valvular and ventricular functions with an ejection fraction of 68%. the patient was counseled and consented for surgery. tab Bisoprolol 2.5 mg, and tab Methimazole 5 mg po were continued on the night before, and the morning of surgery.

The goal during perioperative management of anesthesia was to avoid any factor that increases sympathetic activity such as pain, anxiety, fear, stress response of intubation/ extubation, lighter plane of anesthesia, hypovolemia, and avoiding premedication with anticholinergic drugs. patient was adequately counseled and reassured. premedication with Midazolam 5 mg and omeprazole 40 mg IV was given before surgery.

In the operating room, the patient was attached to 12 lead eCG, with other routine monitoring. Drugs which were kept ready included adenosine, esmolol, lignocaine, procainamide, and defibrillator, to tackle any episode for re-entrant tachycardia and atrial fibrillation. IV catheter, and radial artery cannulation was secured. We gave inj. fentanyl 2 mcg/kg preoperatively and preoxygenated the patient with 100% oxygen for 3 minutes prior to induction with titrating dose of propofol; after induction, anesthetic depth was maintained by adding sevoflurane to the patient,

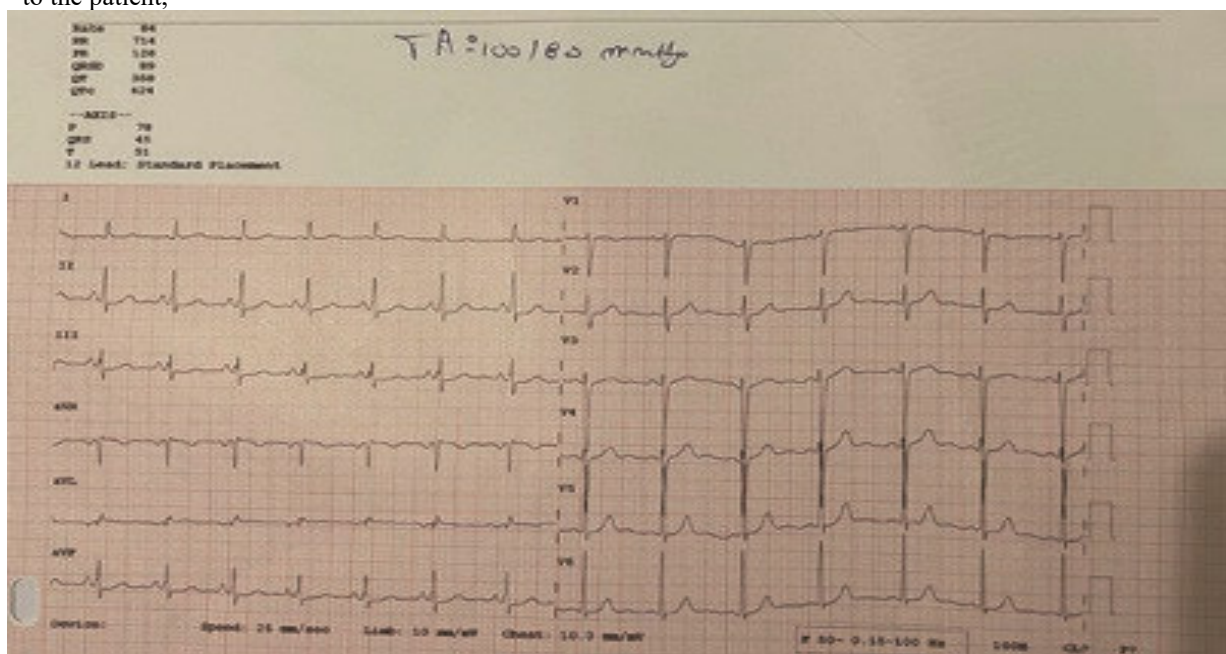


Figure 1 A normal terminal QRS deflection

prior to LMA positioning 10% lignocaine spray was used to anesthetize the airway. post LMA positioning sympathetic response was observed with rise in a heart rate and blood pressure with eCG showing prominent “delta waves” and shortened pR interval; after stabilization of vitals, we started a background infusion of propofol at the rate of 25 mcg/ kg/min and isoflurane. We observed that propofol infusion gradually reduced delta wave, with normalization of QRs complex and pR interval. the case proceeded uneventfully and after

completion of surgery, first sevoflurane and then propofol was stopped. after the return of spontaneous respiration and generation of adequate tidal volume the LMA was removed successfully and sent to recovery room for monitoring of vitals.

Discussion

The main pathophysiological characteristic of the syndrome is the existence of an accessory aV pathway, named “bundle of Kent”. It represents an abnormal fibro-muscular connection which ends up directly into the ventricular myocardium and has remained after incomplete aV separation [2, 3]. It may connect the left atrium and ventricle (type a), or the right atrium and ventricle (type B), and can conduct the stimuli bidirectionally [1, 3]. the prevalence of WpW syndrome is 0.1-3.1% in general population, higher in men [3]. Most cases are sporadic, while the rarer familial form is characterised by autosomal dominant inheritance and has been linked to chromosome 7q34- q36 and mutations in the gamma-2 regulatory subunit of aMp-activated protein kinase gene (pRKA2) [4].

The ECG pattern consists of a short pQ interval (< 120 ms), a slurred upstroke at the beginning of QRs (delta wave) and a broad QRs complex (> 120 ms). this characteristic “WpW pattern” represents an exclusively eCG feature, found 10-100 times more frequently than the actual “WpW syndrome” which refers to the combination of the eCG pattern with symptomatology [2, 5]. While many individuals with a WpW-pattern will remain asymptomatic for life, patients with WpW-syndrome usually develop arrhythmias between the ages 20-40 years [3]. the commonest symptom is palpitations, while dizziness, lightheadedness, chest pain, shortness of breath and syncopal episodes may also occur. Rarely, the first manifestation of the disorder is cardiac arrest [3].

The initial diagnosis of WpW syndrome is based on the ECG pattern combined with symptomatology. More specific examination includes Holter monitoring and exercise or pharmacological testing with procainamide [5].

In patients with WpW syndrome undergoing nonablative surgery, antiarrhythmic treatment should be continued perioperatively. additionally, sympathetic stimulation should be avoided, because it may shorten the ap refractory period and facilitate life-threatening arrhythmias [6]. anaesthetics and adjuvants that increase ap refractoriness should be preferred.

Regarding volatiles, isoflurane and sevoflurane are preferred among other volatiles due to its property to prolong the ap refractory period and decrease the likelihood of tachycardias [7,8]. although halothane could be preferred for its bronchodilator properties in selected cases [9]. Sevoflurane seems less advantageous than isoflurane, since it does not prolong the ap refractory period [11]. Nevertheless, it has been used safely for the maintenance of anaesthesia in a number of cases [12].

Among intravenous anaesthetics, propofol does not affect the ap refractory period [13]. Induction or maintenance of anaesthesia with propofol combined with fentanyl has been associated with cardiovascular stability in WpW patients [14]. Moreover, it was reported that delta waves disappeared after propofol administration and reappeared after its discontinuation [14]. similarly, a decrease of QRs duration and return of pR interval into normal ranges were observed when propofol infusion (25 µg/ kg/min) was added to sevoflurane anaesthesia [15].

Thiopental has been used in several cases, and small (50 mg) to moderate doses (4 mg/kg) did not cause conduction problems [14]. Ketamine should better be avoided due to its sympathomimetic effects. Most opioids are suitable for patients at risk for tachyarrhythmias, since they maintain haemodynamic stability with a mild reduction of HR [12]. additionally, alfentanil/midazolam anaesthesia produces no significant effects on AP conduction and the refractory period [16].

Fentanyl at doses 30-50 µg/kg was found to exert no effect on the anterograde effective refractory period of the ap [17]. It is the most popular opioid, used in the majority of reported cases, and is described as very safe [18,20]. Conversely, the atropine-like effect of pethidine renders it less appropriate for WpW patients [5].

Regarding neuromuscular blockers (NMBs), succinylcholine may act on muscarinic or adrenergic receptors of the sinus node, with bradycardia presenting more often [12]. these effects make the drug less attractive compared to modern non-depolarising NMBs, even though it has been used uneventfully in several cases [19]. among non- depolarising agents, pancuronium may not exert significant direct effects on APs [20], but enhances aV conduction, increases HR and triggers sVt; thus, it is suggested to be avoided [20, 21]. Vecuronium may cause HR reduction [12]; and have been used safely in WpW patients [20, 21]. We preferred to avoid NMBs.

Sedation with a benzodiazepine/opioid combination can be administered alone or as supplement to local anaesthesia for minor surgical procedures [22]. among benzodiazepines, diazepam is cardiovascularly stable, without effects on the ap refractory period [17]. Nevertheless, its long duration of action (half life: 43 h) is a disadvantage, especially for outpatient cases. the intermediate acting lorazepam (half life: 14 h) or the short acting midazolam (half life: 2 h) have also been found to exert no significant effects on AP conduction, and represent more attractive choices [16, 18]. they can be safely used in conjunction with fentanyl [12, 18, 22].

When LMA/Ga is provided, adequate doses of anaesthetics and opioids should be given to suppress the

sympathetic response to LMA positioning /tracheal intubation. supraglottic airway devices should be preferred whenever possible, since their insertion causes less sympathetic stimulation, but care should be taken to avoid hypercarbia during spontaneous ventilation. Intraoperatively, deep anaesthesia and sufficient analgesia reduce the stress response to surgical noxious stimuli.

It also important to consider reduced venous return and atrial filling because due to an extensive sympathetic blockade may precipitate arrhythmias. Adequate fluid loading should be considered in order to reduce – as possible – The risk and magnitude of hypotension, subsequent sympathetic activation or need for sympathomimetic drugs [21, 22]. If hypotension occurs, a pure alpha-adrenergic agonist (i.e., phenylephrine) is the vasopressor of choice [22]. the addition of epinephrine to local anaesthetics should be avoided, as it may shorten the ap refractory period and facilitate arrhythmias.

Conclusion

We took all the precautions necessary to avoid tachycardia and arranged drugs necessary to treat any complications together with stringent monitoring which is very important for favorable outcome in these patients. Management of the case offers an opportunity to relearn the important considerations on WpW syndrome. avoiding neuromuscular blockers can make the difference in avoiding arrhythmias when LMA / Ga is required in patients with WpW syndrome.

Undergoing non-ablative surgery, antiarrhythmic treatment should be continued perioperatively. additionally, sympathetic stimulation should be avoided, because it may shorten the ap refractory period and facilitate lifethreatening arrhythmias.

Anaesthetics and adjuvants that increase ap refractoriness should be preferred.

In this case we avoided pancuronium, which has a tendency to cause increased pulse rate, blood pressure, and cardiac output via interactions with muscarinic receptors in the autonomic nervous system and by inhibiting catecholamine reuptake at sympathetic nerve terminals.

COI Statement: this paper has not been submitted in parallel. It has not been presented fully or partially at a meeting or podium or congress. It has not been published nor submitted for consideration beforehand.

This research received no specific grant from any funding agency in the public, commercial, or non-profit sectors. There are no relevant or minor financial relationships from authors, their relatives or next of kin with external companies.

Disclosure: The authors declared no conflict of interest. No funding was received for this study.

Acknowledgement: We would like to thank medical staff of Department of anaesthesia, University Hospital Centre “Mother teresa” tirana, albania.

References

1. Öhnel RF. pre-excitation, cardiac abnormality, pathophysiological, patho-anatomical and clinical studies of excitatory spread phenomenon bearing upon the problem of the WpW (Wolff, parkinson, and White) electrocardiogram and paroxysmal tachycardia. *acta Med scand* 1944; 152: 1-167
2. Keating L, Morris Fp, Brady WJ. electrocardiographic features of Wolff-parkinson-White syndrome. *emerg Med J* 2003; 20: 491-493. doi: 10.1136/emj.20.5.491
3. al-Khatib sM, pritchett eLC. Clinical features of Wolff- parkinson-White syndrome. *am Heart J* 1999; 138: 403-413. doi: 10.1016/s0002-8703(99)70140-7
4. Gollob MH, Green Ms, tang as, Gollob t, Karibe a, ali Hassan AS, et al. Identification of a gene responsible for familial Wolff- parkinson-White syndrome. *N engl J Med* 2001; 344: 1823- 1831. doi: 10.1056/NeJM200106143442403
5. Bengali R, Wellens HJ, Jiang Y. perioperative management of the Wolff-parkinson-White syndrome. *J Cardiothorac Vasc anesth* 2014; 28: 1375-1386. doi: 10.1053/j. jvca.2014.02.003
6. Blomström-Lundqvist C, scheinman MM, aliot eM, alpert Js, Calkins H, Camm aJ, et al.; european society of Cardiology Committee, Naspe-Heart Rhythm society. aCC/aHa/esC guidelines for the management of patients with supraventricular arrhythmias – executive summary: a report of the american college of cardiology/american heart association task force on practice guidelines and the european society of cardiology committee for practice guidelines (writing committee to develop guidelines for the management of patients with supraventricular arrhythmias) developed in collaboration with Naspe-Heart Rhythm society. *J am Coll Cardiol* 2003; 42: 1493-1531. doi: 10.1016/j.jacc.2003.08.013
7. Chang RK, Wetzel Gt, shannon KM, stevenson WG, Klitzner ts. age- and anesthesia-related changes in accessory pathway conduction in children with Wolff-parkinson-White syndrome. *am J Cardiol* 1995; 76: 1074-1076. doi: 10.1016/ s0002- 9149(99)80303-8
8. Lustik sJ, Wojtczak J, Chhibber aK. Wolff-parkinson-White syndrome simulating inferior myocardial infarction in a cocaine abuser for urgent dilation and evacuation of the uterus. *anesth analg* 1999; 89: 609-612. doi: 10.1213/00000539-

- 199909000- 00012
9. Le Manach Y, Charbucinska K, Godet G. accessory myocardial pathway mimicking an inferior myocardial infarction after major vascular surgery. *eur J anaesthesiol* 2006; 23: 527-529. doi: 10.1017/s0265021506210755
 10. Garg R, sinha R, Nishad p. patient with Wolff-parkinsonWhite syndrome with intermittent pre-excitation under subarachnoid block for urological surgery. *Indian J anaesth* 2011; 55: 167- 170. doi: 10.4103/0019-5049.79899
 11. Irish CL, Murkin JM, Guiraudon GM. anaesthetic management for surgical cryoablation of accessory conducting pathways: a review and report of 181 cases. *Can J anaesth* 1988; 35: 634- 640. doi: 10.1007/BF03020354
 12. staikou C, Chondrogiannis K, Mani a. perioperative manage- ment of hereditary arrhythmogenic syndromes. *Br J anaesth* 2012; 108: 730-744 (doi: 10.1093/bja/aes105), and supplemental material (table s1: effects of commonly used anaesthetic drugs on cardiac electrophysiology)
 13. sharpe MD, Dobkowski WB, Murkin JM, Klein G, Yee R. propofol has no direct effect on sinoatrial node function or on normal atrioventricular and accessory pathway conduction in Wolff-parkinson-White syndrome during alfentanil/ midazolam anesthesia. *anesthesiology* 1995; 82: 888-895. doi: 10.1097/00000542-199504000-00011
 14. Hino H, oda Y, Yoshida Y, suzuki t, shimada M, Nishikawa K. Electrophysiological effects of desflurane in children with Wolff- parkinson-White syndrome: a randomized crossover study. *acta anaesthesiol scand* 2018; 62: 159-166. doi: 10.1111/aas.13023
 15. Dobkowski WB, Murkin JM, sharpe MD, Molotiu N, Guiraudon G, Yee R. The effect of enflurane (1 MAC) on the normal aV conduction system and accessory pathways. *anesth analg* 1991; 72: s50
 16. sharpe MD, Cuillierier DJ, Lee JK, Basta M, Krahn aD, Klein GJ, et al. Sevoflurane has no effect on sinoatrial node function or on normal atrioventricular and accessory pathway conduction in Wolff-parkinson-White syndrome during alfentanil/ midazolam anesthesia. *anesthesiology* 1999; 90: 60-65. doi: 10.1097/00000542-199901000-00010
 17. Gómez-arnau J, Márquez-Montes J, avello F. Fentanyl and droperidol effects on the refractoriness of the accessory pathway in the Wolff-parkinson-White syndrome. *anesthesiology* 1983; 58: 307-313. doi: 10.1097/00000542-198304000-00002
 18. sharpe MD, Dobkowski WB, Murkin JM, Klein G, Guiraudon G, Yee R. alfentanil-midazolam anaesthesia has no electrophysio- logical effects upon the normal conduction system or accessory pathways in patients with Wolffparkinson-White syndrome. *Can J anaesth* 1992; 39: 816- 821. doi: 10.1007/BF03008294
 19. Wellens HJJ, Brugada p, Roy D, Weiss J, Bär FW. effect of isoproterenol on the anterograde refractory period of the accessory pathway in patients with the Wolff-parkinsonWhite syndrome. *am J Cardiol* 1982; 50: 180-184. doi: 10.1016/0002-9149(82)90026-1
 20. Naço M, Çeliku e, Llucaçaj a, shehaj J, Kameniku R. toxic adenoma of the thyroid gland and Wolff-parkinson-White syndrome. *Hippokratia* 2009; 13: 116-118
 21. Richmond MN, Conroy pt. anesthetic management of a neonate born prematurely with Wolff parkinson White syndrome. *anesth analg* 1988; 67: 477-478 *Anaesthesia for pre-excitation syndromes* 145
 22. schmitz Jp, Holmgreen WC. outpatient anesthetic management of a patient with Wolff-parkinson-White syndrome. *J oral Maxillofac surg* 1997; 55: 175-179. doi: 10.1016/s0278- 2391(97)90239-1