

Histopathological Changes of Some Internal Organs of Mice Injected with Exotoxin a at Low Concentrations

Shatha Zuheir Majeed, M. Sc.¹ Ibtesam Ghadban Auda, Ph. D.²
Istabreq Muhammed Ali Salman, M. Sc.²Jameelah, Ghadban Auda, Ph. D.¹
1.Al-Kidney College of Medicine\ Baghdad University
2.College of Science\ Al- Mustansyriah University
E.mail of the corresponding authors: Istabreq2007@yahoo.com

Abstract

Exotoxin A is the most lethal virulence factor produced by *Pseudomonas aeruginosa*. It inhibits elongation factor-2 by ADP-ribosylation of EF2. This causes stop of the elongation of polypeptides. In recent study, the effect of low concentration of exotoxin A on some important internal organs of mice was studied. Four groups white mice were injected intraperitoneally with pure exotoxin A in the following manner 0.1, 0.2, 0.3, 0.4 ng\ animals. One mouse receives normal saline intraperitoneally as a control. After 72 hours the mice were killed and four organs were taken, liver, spleen, lung and heart from each killed mice. Histological sections were made from each organ and stained with hematoxylin and eosin stain then examined under microscope. The resultant pathological changes were included, congestion of blood vessels, degenerative and necrotic changes, and infiltration of inflammatory cells of these organs. These pathological changes increased with increase the amount of exotoxin A injection as compared with control. No mouse was dying due to injection of exotoxin A. As a conclusion, exotoxin A at low concentrations can affect important internal organs namely, liver, spleen, lung and heart, this effect increase with increasing the concentration of exotoxin A. Lethal dose₅₀ is much higher than that of the highest concentration that causes pathological changes.

Keywords: *Pseudomonas aeruginosa*, Exotoxin A, Pathological changes

Introduction

Pseudomonas aeruginosa is an opportunistic pathogen that causes serious and sometimes fatal infections in the compromised host, especially in patients with major trauma or thermal injuries. Several extracellular products from *P. aeruginosa* such as exotoxin A, exoenzyme S, phospholipase and hemolysins have been studied as potential virulence factor (Manafi *et al.* 2009). Exotoxin A is the major and most lethal virulence factor produced by this ubiquitous microorganism (El-Zaim *et al.* 1998; Driscoll *et al.* 2007). It inhibits elongation factor-2. It does so by ADP-ribosylation of EF2. This then causes the elongation of polypeptides to cease (Yates *et al.* 2004). Furthermore, Strains of *P. aeruginosa* deficient in exotoxin A production are less virulent than strains producing exotoxin A, and patients who survive infection from exotoxin A -producing strains typically have high antibody titers against exotoxin A (Murray *et al.* 2009). The aim of this study is to evaluate the effect of low concentration of exotoxin A on some important internal organs of mice.

Materials and methods

Two fold dilution of pure exotoxin A (Cusabio biotech - USA) was made from 10ng/ml stock solution. Four groups of 20 weeks age white male mice were obtained from infertility center at Al-Kadhymiah\ Baghdad. These mice were injected with pure exotoxin A intraperitoneally in the following manner 0.1, 0.2, 0.3, 0.4 ng\ animal. One mouse receives normal saline intraperitoneally as a control. After 72 hours the mice were killed and four organs were taken, liver, spleen, lung and heart from each killed mice. Histological sections were made from each organ and stained with hematoxylin and eosin stain then examined under 40X power (Stevens, A. 1982).

Results

Many pathological changes were observed in the histopathological section:

Liver pathological changes: these changes include congestion of blood vessels, hepatocytes degeneration and necrosis, kuffer cell infiltration. Severe ballooning degeneration in hepatocytes also was observed. The changes were severe in liver of mice that receive 0.4 ng, especially congestion of blood vessels as shown in figure (1).

Lung pathological changes: the alveolar walls are thickened from the presence of lymphocytes and plasma cells. Congestion of blood vessels, mucin production in the lumen of alveoli, these changes are increased with increase of concentration of the injected exotoxin A especially thickening of alveolar walls and congestion of blood vessels, figure (2) shows these changes.

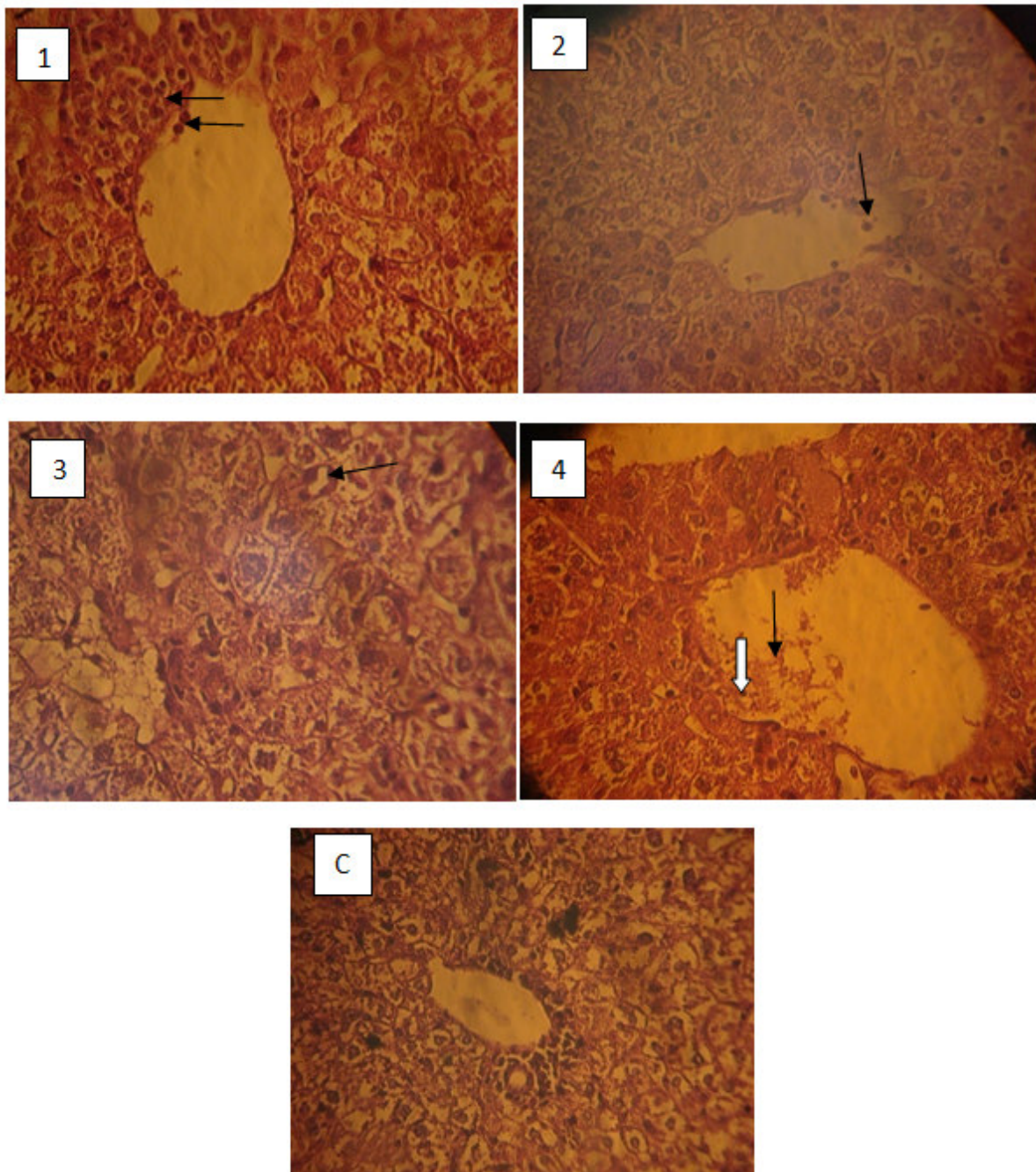


Figure 1: histological sections of mice liver

Sections 1, 2, 3 and 4 histological sections of mice liver injected with 0.1, 0.2, 0.3 and 0.4 ng respectively. C is control mouse liver. Congestion of blood vessels is obvious in section 4 (thin arrow), hepatocytes degeneration and necrosis is in section 3 (arrow), infiltration of kuffer cell is in sections 1, 2 (arrow) and 4 (thick white arrow).

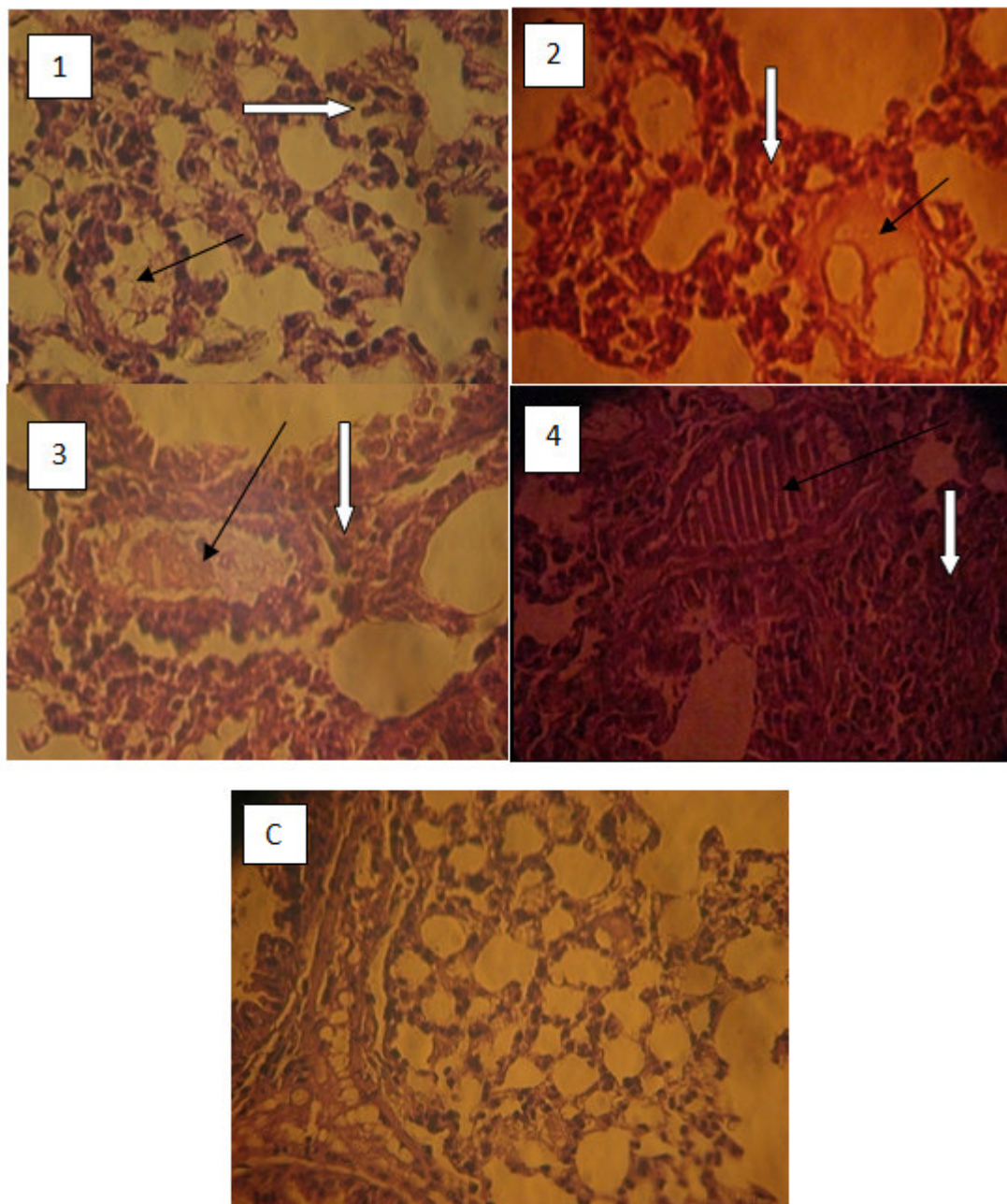


Figure 2: histological sections of mice lung

Sections 1, 2, 3 and 4 histological sections of mice lung injected with 0.1, 0.2, 0.3 and 0.4 ng respectively. C is control mouse lung. The alveolar walls are thickened (white arrows in 1, 2, 3 and 4 sections). Congestion of blood vessels is appear in section 4 (black arrow), mucin production in the lumen of alveoli is in sections 1, 2, and 3 (black arrows); the changes are increased with increase of concentration of the injected exotoxin A.

Spleen pathological changes: Spleen white pulp was enlarged, splenocytes were degenerated, phagocytes cell were infiltrated, and hyperplasia and congestion of blood vessels was observed. White pulp enlargement was obvious in spleen of mice that receive 0.3 and 0.4 ng as shown in figure (3).

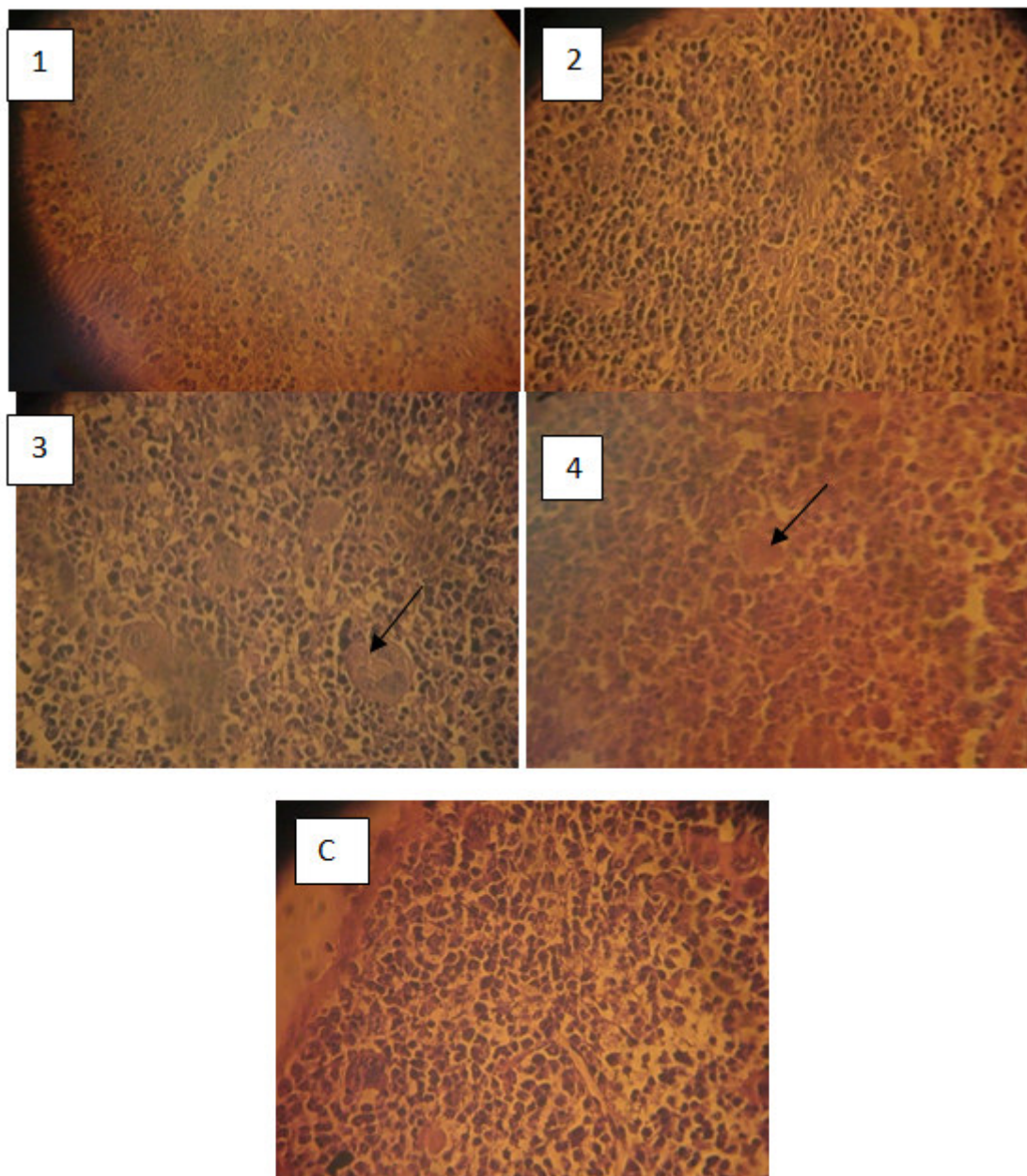


Figure 3: histological sections of mice spleen

Sections 1, 2, 3 and 4 histological sections of mice spleen injected with 0.1, 0.2, 0.3 and 0.4 ng respectively. C is control mouse spleen. White pulp enlargement was obvious in sections 3 and 4 (arrows).

Heart pathological changes: these changes include blood vessels congestion especially in heart of mice that receive 0.4 ng, degenerative changes and necrosis of cardiac cells and infiltration of inflammatory cells (figure - 4).

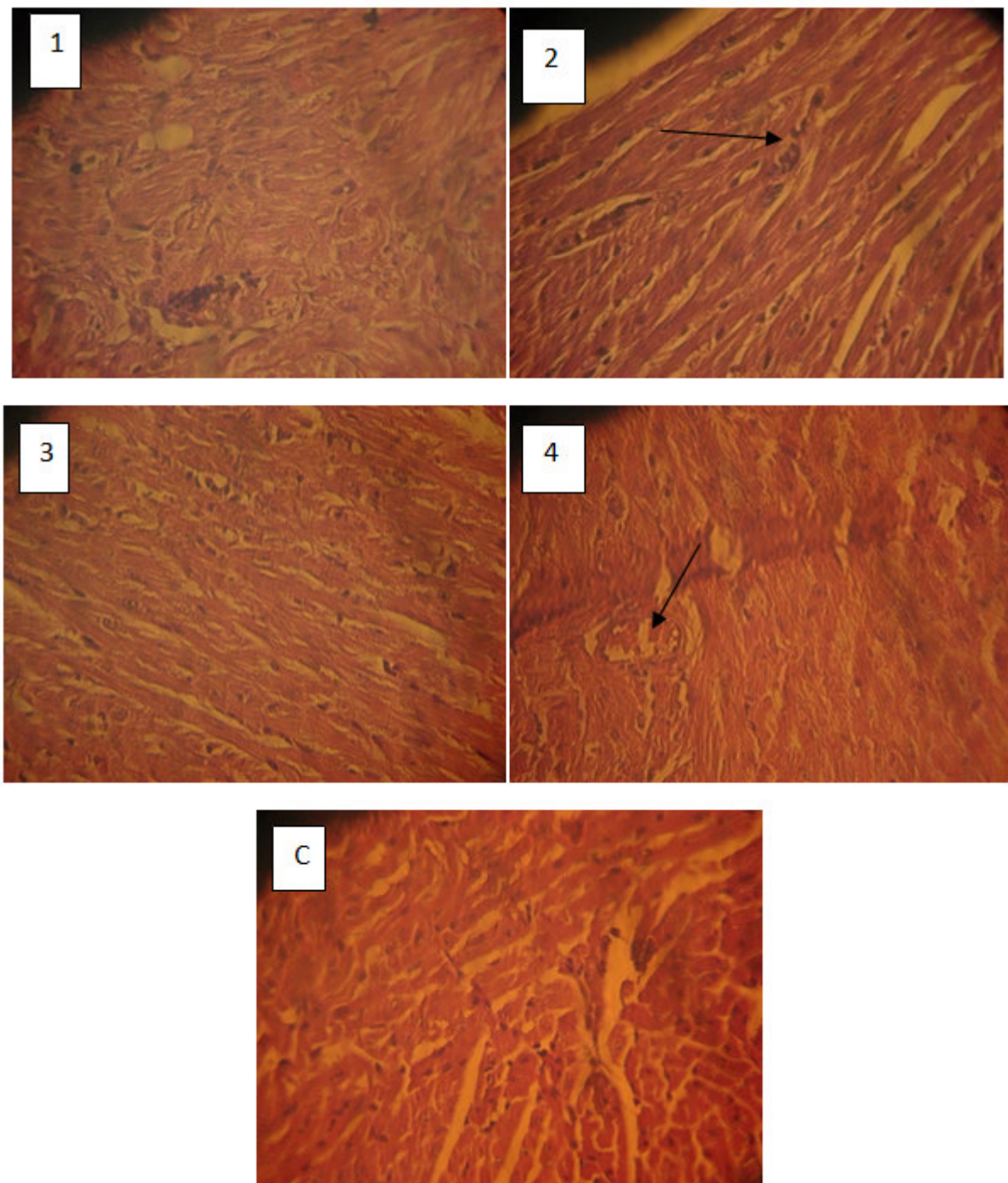


Figure 4: histological sections of mice heart

Sections 1, 2, 3 and 4 histological sections of mice heart injected with 0.1, 0.2, 0.3 and 0.4 ng respectively. C is control mouse heart. Degenerative changes are in section 2 (arrow), blood congestion in section 4 (arrow).

Discussion

Low concentration of pure exotoxin A was used to study the effect of such concentrations on certain organs. Most of previous studies used exotoxin A at higher concentrations reach to several micrograms (Al-Muhammadawi *et al.*2006; Manafi *et al.*2009). The pathological changes of four organs, liver, spleen, lung and heart were almost the same of these changes found in Al-Muhammadawi, 2006 (Al-Muhammadawi *et al.*2006) study.

The pathological changes of organs of mice that receive the highest concentration of exotoxin A were more than that of mice received lowest concentration. The blood vessels of heart and liver were severely congested in a mouse that receives exotoxin A at 0.4 ng. White pulp enlargement was obvious in spleen of mice that receive 0.3

and 0.4 ng. The pathological changes of lung are increased with increase of concentration of the injected exotoxin A especially thickening of alveolar walls and congestion of blood vessels. No mouse was died at any concentration because of that the lethal dose₅₀ (LD50) of exotoxin A is 0.5µg (Manafi *et al.*2009;Al-Muhammadawi *et al.*2006). The toxicity of *P. aeruginosa* LPS is 2000 times lowers than that of exotoxin A in mice(Miyazaki *et al.*1995). This may be the reason behind the occurrence of pathological changes in very low exotoxin A concentrations.

As a conclusion, exotoxin A at low concentrations can affect important internal organs namely, liver, spleen, lung and heart, this effect increase with increasing the concentration of exotoxin A. Lethal dose₅₀ is much higher than that of the highest concentration that causes pathological changes.

References

- 1- Manafi, A. Kohanteb, J. Mehrabani, D. Aziz Japoni, A. Amini, M. Naghmachi, M. Zaghi, A. H. and Khalili, N. Active immunization using exotoxin A confers protection against *Pseudomonas aeruginosa* infection in a mouse burn model. *BMC Microbiol.* 2009, 9: 23.
- 2- El-Zaim, H. S. Ashok, K. Chopra, A.K. Peterson, J.W. Vasil, M. L. and Heggors, J.P. Protection against Exotoxin A (ETA) and *Pseudomonas aeruginosa* Infection in Mice with ETA-Specific Antipeptide Antibodies *Infect Immun.* 1998, 66 (11): 5551-5554.
- 3- Driscoll, J.A. Brody, S.L. and Kollef, M.H. The epidemiology, pathogenesis and treatment of *Pseudomonas aeruginosa* infections. *Drugs.* 2007, 67:351–368.
- 4- Yates, S.P., Merrill, A.R. "Elucidation of eukaryotic elongation factor-2 contact sites within the catalytic domain of *Pseudomonas aeruginosa* exotoxin A". *Biochem. J.* 2004, **379** (3): 563–72.
- 5- Murray, P.R. Rosenthal, K.S. and Pfaller, M.A. eds. Medical Microbiology, 6th edn. Elsevier, Inc., Philadelphia, PA.2009.
- 6- Stevens, A. the hematoxylin in: Theory and Practice of Histological Techniques, 2nd edition. Bancroft, J.D. and Stevens, A. London, Churchill livingstone. 1982.
- 7- Al-Muhammadawi, K.J. biochemical and molecular study of exotoxin A from local isolate of *Pseudomonas aeruginosa* Ph.D. thesis. College of science. Al-Mustansiriyah University. 2006.
- 8- Miyazaki, S. Matsumoto, T. Tateda, K. Ohno, A. and Yamaguchi, K. Role of exotoxin A in inducing severe *Pseudomonas aeruginosa* infections in mice. *J Med Microbiol.* 1995, 43; 169-175.

The IISTE is a pioneer in the Open-Access hosting service and academic event management. The aim of the firm is Accelerating Global Knowledge Sharing.

More information about the firm can be found on the homepage:
<http://www.iiste.org>

CALL FOR JOURNAL PAPERS

There are more than 30 peer-reviewed academic journals hosted under the hosting platform.

Prospective authors of journals can find the submission instruction on the following page: <http://www.iiste.org/journals/> All the journals articles are available online to the readers all over the world without financial, legal, or technical barriers other than those inseparable from gaining access to the internet itself. Paper version of the journals is also available upon request of readers and authors.

MORE RESOURCES

Book publication information: <http://www.iiste.org/book/>

Recent conferences: <http://www.iiste.org/conference/>

IISTE Knowledge Sharing Partners

EBSCO, Index Copernicus, Ulrich's Periodicals Directory, JournalTOCS, PKP Open Archives Harvester, Bielefeld Academic Search Engine, Elektronische Zeitschriftenbibliothek EZB, Open J-Gate, OCLC WorldCat, Universe Digital Library, NewJour, Google Scholar

