

# Studies on the Chronic Consumption of Thermo Oxidized Palm Oil on the Histomorphology of the Cerebellum in Mice

Kebe E. Obeten<sup>1\*</sup>, Anozang, O. Igiri<sup>1</sup>, Charles C. Mfem<sup>2</sup>

1.Department of Anatomy, University of Calabar, Calabar

2.Department of Physiology, University of Calabar, Calabar

Email: [fredobeten@yahoo.com](mailto:fredobeten@yahoo.com)

## Abstract

The effect of thermoxidized palm oil (TPO) diet on the histomorphology of cerebrum was studied using mice. Thirty (30) albino mice weighing between 18-24g and aged 2-4 weeks were grouped into two groups; fifteen (15) animals each group and fed, TPO diet and normal rat chow (control diet) for 14 weeks. Body weight change was significantly lower in the TPO group compared to control ( $p < 0.01$ ). Histologic micrograph showed hyperchromasia of the granule cell layer of the cerebellum in TPO. From the results, thermoxidised palm oil diet may have adverse effects and degenerative changes in the cerebellum.

**Keywords:** Chronic consumption, Thermo-oxidized palm oil, Cerebellum, Histomorphology.

## 1. INTRODUCTION

Palm oil (also known as dendê oil, from Portuguese) is an edible vegetable oil derived from the mesocarp (reddish pulp) of the fruit of the oil palms, primarily the African oil palm *Elaeis guineensis*, (Reeves *et al.*, 1979) and to a lesser extent from the American oil palm *Elaeis oleifera* and the maripa palm *Attalea maripa*.

Palm oil is naturally reddish in color because of a high beta-carotene content. It is not to be confused with palm kernel oil derived from the kernel of the same fruit, (Poku, 2002) or coconut oil derived from the kernel of the coconut palm (*Cocos nucifera*). The differences are in color (raw palm kernel oil lacks carotenoids and is not red), and in saturated fat content: Palm mesocarp oil is 41% saturated, while Palm Kernel oil and Coconut oil are 81% and 86% saturated respectively (Harold, 2004)

Palm oil is widely used in domestic cuisines in Nigeria and other African countries and also for the preparation of a number of local products, for example, candles, soaps detergents, cosmetics, and many others, by small and even large industries. It is the most abused oil used in domestic cooking in Nigeria where it is used repetitively to fry bean-cake (*Akara*), plantain, yams, and other food items. This continual heating of the fresh oil usually causes the oil to become thermally oxidized. Studies have shown that thermally oxidized palm oil is injurious to tissues (Osim, 1994; Owu, 1988). The literature on the effects of ingestion of thermoxidized palm oil diets on the small intestine is scanty but epidemiologic studies implicated dietary fats as a major risk factor for malignant transformation of the gut in humans (Reddy, 1983).

Lipids represent a class of dietary oxidants of major nutritional and toxicological importance. These potentially toxic oxidants result from peroxidation of polysaturated fatty acids of dietary lipids. They are among the natural mutagens and carcinogens present in the human diets that can initiate degenerative processes through the generation of oxygen radicals which may ultimately lead to the damage of the digestive system (Grisham, 1994), including intestinal inflammation and cancer (Rezk, 2003).

There is also a casual relationship between toxicity of dietary polysaturated oil and the peroxide content in rats suggesting a potential cytotoxic effect associated with excessive consumption of thermoxidized palm oil with a high level of oxidation. For instance, several reports have been documented on the effect of thermally oxidized palm oil diets on various functional and structural alterations (Osim, 1994; Obembe, 2008). Furthermore, degeneration of the mucosa and submucosa reduced size of the villi which led to a general distortion in the intestinal morphology following chronic ingestion of thermoxidized palm oil have been reported (Agona *et al.*, 2011).

## 2. MATERIALS AND METHOD

Thirty (30) Albino mice obtained from the Department of Pharmacology, University of Uyo, Uyo were used for this study. The mice were grouped into two; Group 1 which served as the control group received normal rat diets while group 2 (experimental group) received thermoxidized diet. Mice were chosen because the apparatus used for the experiments were specially designed for mice. Also because they are tough, cheap to maintain and not too difficult to obtain. The mice weighed between 18-24g and aged 2-4 weeks at the beginning of the research and were randomly chosen from both sexes. They were all kept in plastic cages with wire net covers of three different groups. The ethics for the use of experimental animals were strictly adhered to. They were maintained in the animal facility of the Department of Physiology, University of Calabar, Calabar, at a room temperature of  $25^{\circ}\text{C} \pm 2^{\circ}\text{C}$ , (12 hours light and dark cycles). Each mouse was kept in a separate cage. The cages were always

kept neat on a daily basis. Food and water intake per mouse was determined on a daily basis using a weighing balance and measuring cylinder respectively.

Fifteen litres of fresh palm oil processed from oil palm tree *Elaeis guineensis* was bought from Watt Market, Calabar, Nigeria. The palm oil was certified fresh because of its low oxidation value using the method of Rossel (1983). The thermoxidation of palm oil was carried out following the methods reported by Isong *et al* (1988), Osim *et al* (1992) and Owu *et al* (1998). Fresh palm oil was heated in a stainless steel pot over a heating mantelpiece at a temperature of 190°C for five consecutive times of 20 minutes in each round. There was a 5 minutes cooling interval between two rounds, diets were later formulated from this thermoxidized oil

### 3. Result

Body weight change was determined to find out if chronic consumption of the palm oil diets affected the growth of the animals used for the study and histology of the cerebellum was also studied.

#### 3.1. Body weight

The mean body weight change was  $2.18 \pm 0.38$  and  $4.11 \pm 0.46$  grams in mice fed thermoxidized, and control diets respectively. The body weight change was significantly lower in the group of mice fed thermoxidized palm oil diets compared to control ( $p < 0.01$ ) (figure 1).

#### 3.2. Histology of cerebellum

The effect of chronic consumption of thermoxidized palm oil diet on the histology of the cerebellum of mice revealed that there was hyperchromation of the granule cell layer and thickening of the pial surface in the cerebellum of the mice fed thermoxidized palm oil diet compared to that of the mice fed with control diet. This may have been caused by the hazardous constituents of thermally oxidized palm oil like the oxygen derived free radicals and dihydroxyl esters that are destructive to tissues (O'sara *et al*, 1979; Frankel, 1980 and Meredith, 1984). The hyperchromation of the granule cell layer may also be due to glutamate toxicity.

### 4. REFERENCES

- Agona O. Obembe, Daniel U. Owu, Obem O. Okwari, Atim B. Antai, & Eme E. Osim (2010). Intestinal Fluid and Glucose Transport in Wistar Rats following Chronic Consumption of Fresh or Oxidised Palm Oil Diet. *ISRN Gastroenterol.* doi: 10.5402/2011/972838
- Frankel, E. N. (1980). Lipid oxidation. *Prog. Lipid Res.* 19: 1 – 22.
- Grisham MB. (1994) Oxidants and free radicals in inflammatory bowel disease. *Lancet.* 344(8926):859–861.
- Harold McGee. (2004). *On Food And Cooking: The Science And Lore Of The Kitchen*, Scribner, edition. ISBN 978-0-684-80001-1
- Isong, E. U. (1988). Biochemical and nutritional studies on rats of thermally oxidized palm oil (*Elaeis guineensis*). PhD. Thesis, University of Calabar, Calabar.
- Meredith, S. (1984). Free radicals; friends or foe medicine. *Digest 10 (4):* 23 – 25.
- Obembe AO, Okwari OO, Owu DU, Antai AB, Osim EE (2008). Intestinal motility and transport following chronic ingestion of different forms of palm oil diets. *Nigerian Journal of Physiological Sciences.* 23:95–99.
- Osim EE, Owu DU, Isong E, Umoh IB (1994). Influence of chronic consumption of thermoxidized palm oil diet on platelet aggregation. *Discovery and Innovation.*;4:83–87.
- Osim, E. E., Owu, D. U., Umoh, I. B. and Isong, E. U. (1992). Influences of chronic consumption of thermoxidized oil on platelets aggregation in rats. *Discovery and Innovation*, 6(4), 389 – 396.
- Owu DU, Osim EE, Ebong PE (1998) Serum liver enzymes profile of Wistar rats following chronic consumption of fresh or oxidized palm oil diets. *Acta Tropica.* 69(1):65–73.
- Poku, Kwasi (2002). "Origin of oil palm". *Small-Scale Palm Oil Processing in Africa*. FAO Agricultural Services Bulletin 148. Food and Agriculture Organization. ISBN 92-5-104859-2.
- Reddy BS (1983). Dietary fats and colon cancer. In: Antrup H, William GM, editors. *Experimental Colon Carcinogens*. Boca raton, Fla, USA: LRC Press; pp. 225–239.
- Reeves, James B.; Weihrauch, John L. (1979). Consumer and Food Economics Institute *Composition of foods: fats and oils*. Agriculture handbook 8-4. Washington, D.C.: U.S. Dept. of Agriculture, Science and Education Administration. p. 4
- Rezk JJ, Heanen GR, VaderVijgh WJ, Bast A. (2003) Tetrahydrofolate and 5 methy tetrahydrofolate are folates with high antioxidant activity. Identification of antioxidant harmacophores. *FEBS Letters.* 555:610–605.
- Rossel, J. B. (1983). Measurement of rancidity. In Allen, J. C. and Hamilton, R. J. (Eds.), *Rancidity in food* (pp 21 – 46). England: Applied Science Publishers.

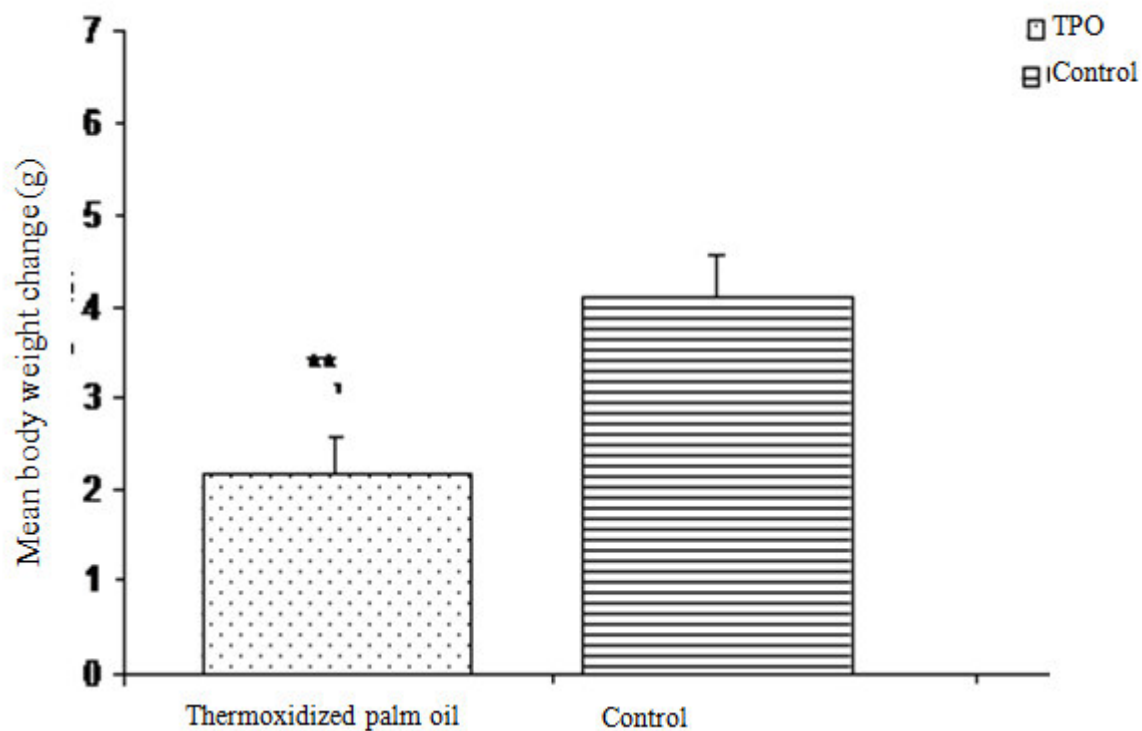


Figure 1: Mean body weight change in mice fed thermoxidized, n = 10, \*\* =  $p < 0.01$  vs control,

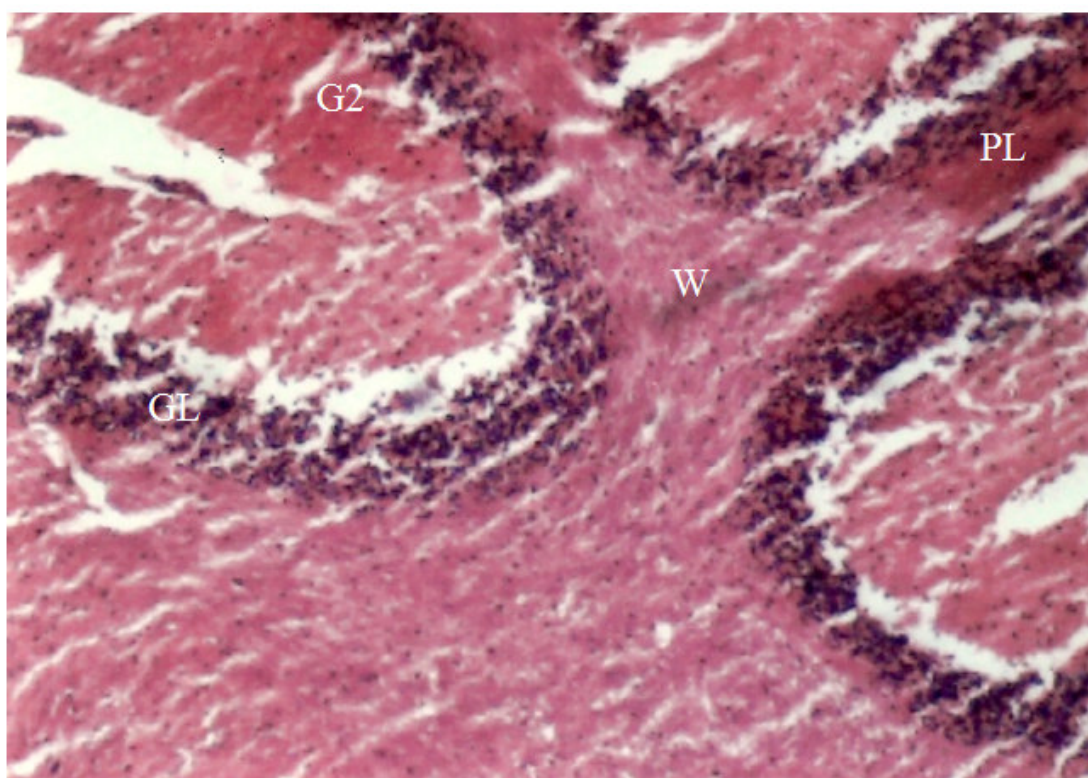
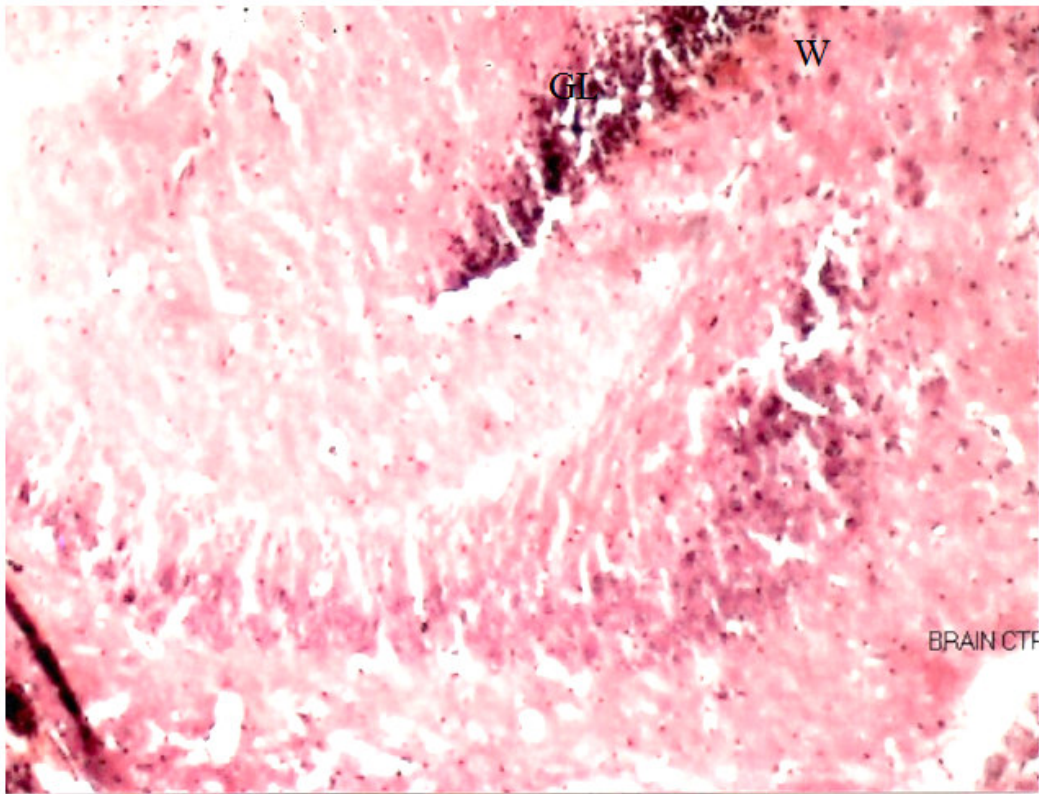


Plate 1: Photomicrographs of a section of the Cerebellum (cerebellar cortex) for mice fed control diet showing: Purkinje cell (PL), White matter (W), Golgi type II cell (G2) and Granular layer (GL)





**Plate 2: Photomicrographs of a section of the Cerebellum (cerebellar cortex) for mice fed thermoxidized palm oil diet showing: Granular layer (GL), (White matter (W))**

The IISTE is a pioneer in the Open-Access hosting service and academic event management. The aim of the firm is Accelerating Global Knowledge Sharing.

More information about the firm can be found on the homepage:  
<http://www.iiste.org>

## CALL FOR JOURNAL PAPERS

There are more than 30 peer-reviewed academic journals hosted under the hosting platform.

**Prospective authors of journals can find the submission instruction on the following page:** <http://www.iiste.org/journals/> All the journals articles are available online to the readers all over the world without financial, legal, or technical barriers other than those inseparable from gaining access to the internet itself. Paper version of the journals is also available upon request of readers and authors.

## MORE RESOURCES

Book publication information: <http://www.iiste.org/book/>

Recent conferences: <http://www.iiste.org/conference/>

## IISTE Knowledge Sharing Partners

EBSCO, Index Copernicus, Ulrich's Periodicals Directory, JournalTOCS, PKP Open Archives Harvester, Bielefeld Academic Search Engine, Elektronische Zeitschriftenbibliothek EZB, Open J-Gate, OCLC WorldCat, Universe Digital Library, NewJour, Google Scholar

