

Case Report on Cattle Pediculosis Outbreak in Jimma University on Cattle Kept for Practical Demonstration and the Control Measures Taken on Time

Assefa Kebede Eshetu Shumi

School of Veterinary Medicine, Jimma University College of Agriculture and Veterinary Medicine, P.O. Box:
307, Jimma, Ethiopia

Abstract

Lice are permanent host specific skin parasites of animals that cannot survive out of their natural host more than a few days. Cattle affected by both sucking lice and biting lice. The present case was presented to Jimma University open air clinic with chief complaint of itching and weight loss. The animal was a bull kept in Jimma University College of Agriculture and Veterinary Medicine for practical demonstration. It was bought from open market before 2 months of the occurrence of the disease and kept together with other animals in the same house. Upon detailed physical and clinical examination, the bull was rubbing against a pole in the clinic, loss of body weight, anemia, alopecia mainly in the neck region and opening of mouth during itching. During the detail clinical examination an aggregation small sized blue to black colored lice were found on the neck, face and head region of the animal. To identify the type of species of lice, sample of skin scraping was taken to Jimma University Veterinary Parasitology laboratory and the species of the parasite were identified with the consultation of Wall and Shearer (2001) *veterinary ectoparasites book and found to be Solenoptes capillatus*. The bull was treated with a single dose of 1% ivermectin subcutaneously with a dose of 0.2 mg/kg body weight and followed and responded immediately after 3 days. However; after a week, another bull kept in the same farm near to the infested one was found to be infested with the same parasite species and treated immediately with ivermectin. Following this, the farm was disinfected with diazinon and became free of lice. Lastly, this case report demonstrates that lice are among the most important health constraints of cattle in any part of the tropical countries like Ethiopia leading to important economic losses so attention should be given during diagnosis not to overlook the case and control interventions on animal and farm level should be practiced.

Keywords: Bull; Pediculosis; Case report; Jimma University

1. Introduction

Lice are permanent skin parasites of animals that cannot survive off of the host more than a few days. They are host specific and are unable to survive on the wrong host for more than a day or two. Cattle can be affected by both sucking lice and biting lice. Lice on cattle are spread by direct contact between animals within a herd (Urquhart, 1996).

Lice have an irritation nature, mainly the sucking lice. The irritation can cause the animal to bite, scratch and rub. This is directly associated with animal welfare issue. Lousy cattle rubbed against fences, yards or trees and transmit to other animals rubbed against the same posts. The coats of lousy cattle becomes rough scruffy in appearance, and at times, areas of skin are rubbed raw. This will reduce hide value at slaughter and be inconsistent with on-farm quality assurance programs. In spite of animals infested with lice show reduced weight gains and general unthriftiness, many authors believed that the effect of lice on the production and growth rate of cattle is debating issue. For this reason, it is believed that no significant economic loss is incurred on cattle unless there is poor condition or heavy infestations on it. It appears that averages of 10 or more lice per square inch are necessary to have a significant effect. However, veterinarians and producers believe that losses occur and some cattlemen frequently treat animals with lice just for the improvement of appearance. Furthermore, diseased or nutritionally stressed animals are expected to develop more severe lice infestations than healthy animals. That is why, it is recommended to look for underlying causes if only a few animals in a mob are severely affected by lice.

Patient Information

History of animals: More than 25 animals were brought Gera open market (rural area around Jimma) before 2 months of the occurrence of the outbreak.

Management of the animal: they were kept with other dairy cattle and horse and mule in the same house but with different pens.

Case 1: One bull was presented to veterinary open clinic of Jimma University. This bull was kept in Jimma University dairy farm for demonstration purpose with other animals. The attendant for this bull complained the presence of itching and hair loss around the head and neck regions. The clinician was tentatively diagnosed as

non-parasitic disease and treated it with oxytetracycline. While the first author was passing through the clinic he observed the animal rubbing itself against a post in the clinic and opened its mouth from a distant (**Fig.1**). Up on clinical examination, the animal was found to have itching, alopecia on head and neck (**Fig.2**). On detail examination of the animal for external parasites, the authors realized the presence of lice on the above indicated sites with rough scruffy coat appearance around the infested area, presence of aggregated many small sized blue to black colored lice on the neck, face and head region of the animal and a sample of skin scraping was taken for identification of the species of the lice (**Fig.3**). Up on skin scraping examination, many nits, nymphs and blood full adult lice were examined under stereo-microscope. The finding was consulted with Wall and Shearer (2001) and identified to be *Solenoptes capillatus*.



Figure 1: Rubbing against post and opening mouth to express the presence of itching



Figure 2: Alopecia as a consequence of frequent itching

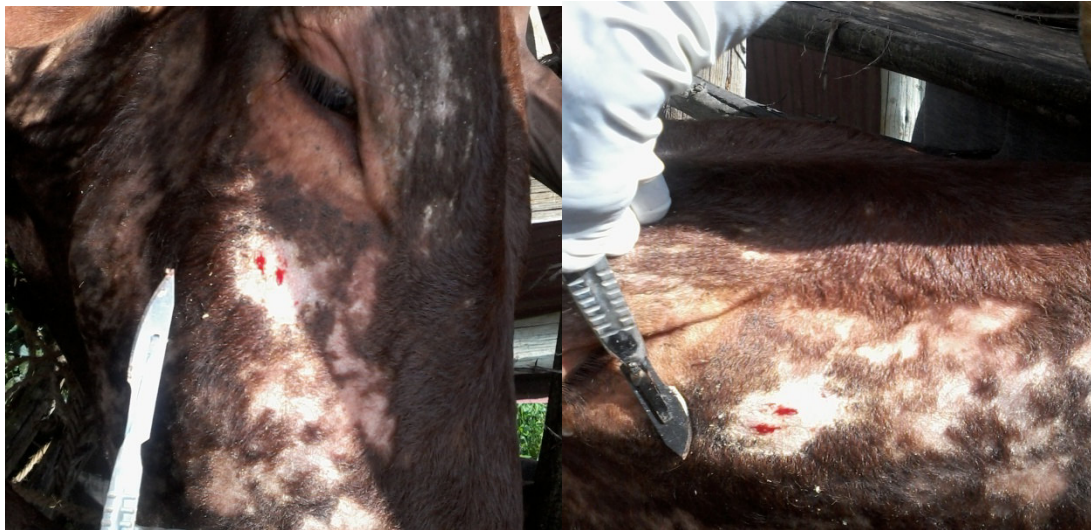

Figure 3: Procedures of sample collection (skin scarping)

Control measures

The bull was administered with single dose of 1% ivermectin subcutaneously with a dose of 0.2 mg/kg body weight and followed for the next two weeks and 3 days after treatment, all the lice were removed from the infested sites and the bull got a relief from itching; however, the alopecia remained for more than two weeks.

Case 2: A week after, another bull, placed in the diseased animal side with approximately 1 meter distance within the same house was reported to have same black dots on its head and neck regions. The cattleman came to my office and requested me to examine the animal for similar case. Up on examination, I found the same species of lice on the second animal also and treated it with single dose of ivermectin.

Measurement actions taken on this farm

Diseased animals were made to be separated from the healthy animals and then the house was sprayed with acaricides (Diazinon) after shifting the healthy animals to temporary house.

Recommendations

It was recommended that while new animals are brought in to the farm from unknown farms, the animals should be treated with an appropriate acaricides and kept separate from the herd until confirmed to be free of lice or significant evidence is established to assure the animal is free of lice. This is to avoid the spread of lice among different farms and reduce losses incurred by such parasites in the future.

Patient Perspective:

When appropriate the patient should share their perspective on the treatments they received

Informed Consent

The diagnosis, treatment and control strategies were performed upon the request from the farm manger through the attendants.

Discussion

The lice (Order: Phthiraptera) are superbly adapted and highly successful insect ectoparasites of birds and mammals. There are two forms of lice (1) Anoplura which adapted for blood sucking and occur only on mammals (2) Mallophaga which adapted to wool eating (biting lice or chewing lice) and occur on both mammals and birds (Wall and Shearer, 2001; Urquhart *et al.*, 1996). Most species of mammals and birds are infested by at least one species of louse. Some of the lice species infesting cattle are *Damalinea (Bovicola) bovis*, *Haematopinus eurysternus*, *Linognathus vituli*, and *Solenopotes capillatus* (Merck, 2008). Heavy louse infestation in human and animals is known as pediculosis and is more common in cattle than any other type of domesticated animal. This is a significant problem, as it can cause weight loss of 55 to 75 pounds per animal (Hussain, 2006). Similarly, the present case was reported in cattle (bulls) and was characterized by body weight loss. Unlike, Townsend (2000); who had reported older cattle with longer hair and bulls that have large body mass to be more prone to lice infestation than young and light body mass animals due to difficulty with self-grooming or heavy infestations are usually associated with young animals or older animals in poor health or those kept in unhygienic conditions Wall and Shearer (2001), however, in the present study the infestation was

recorded in bulls with relatively good body condition and kept under better hygienic condition. This may be associated with other underlining diseases. In the present case, the bulls were infested by *Solenopotes capillatus* which are little blue in color (Durden and Musser 1994).

The present case was characterized by rubbing against post in the clinic, opening while itching, alopecia faces, neck and head.

On detail examination of the animal for external parasites, the authors realized the presence of lice on the above indicated sites with rough scruffy coat appearance around the infested area,

Blood sucking lice associated with domestic animals have also been implicated in the transmission of disease. For example, the pig louse, *Haematopinus suis*, may spread pox virus and cattle lice may transmit rickettsial anaplasmosis. Some species of lice may act as intermediate hosts to the tape worm, *Dipylidium caninum*. However, despite this, lice are predominantly of veterinary interest because of the direct damage they can cause to their hosts, rather than as vector. Lice infestations cause the animal to scratch the areas infested, resulting in lesions or abrasions and areas of alopecia (hair loss) that can lead to bacterial or viral infections and insect infestations that cause the animal to become ill. Heavy louse infestations are known to cause an unthrifty, pruritus, alopecia, excoriation and self wounding, vigour weight loss; greasy appearance of infested animals coat, dairy animals produce less milk and calves poor weight gain, stunted growth and with sucking lice heavy infestation, animal become anaemic and may be predisposed to respiratory diseases, abortion and death. Furthermore, the disturbance caused may result in lethargy and loss of weight gain or reduced production. Severe infestation with sucking lice may cause anaemia (Nafstad and Grønstøl 2001; Wall and Shearer, 2001; Holdsworth et al. 2006). The present case also showed similar clinical signs and production loses. Transfer of lice from animals to animals or from herd to herd is usually by direct physical contact. The present case also supports this idea, this because, another bull which was kept nearby was also found diseased after about one week.

The identification of lice is complex and the features used to describe many genera are obscure. However, in contrast to most fleas or ticks; lice are highly host and site specific, in many cases information relating to the species of host and the site of infestation provides a reliable initial guide to identification. Similar to (Townsend 2000; Watson et al. 1997); in the present case, lice were aggregated mostly on faces such as muzzle and cheek, neck, shoulders, and neck. The parasite was mainly characterized by prominent abdominal tubercles bearing the spiracles project from the sides of each abdominal segment, absence of paratergal plates on the abdomen but the second and third pairs of legs are larger than the first pair and end in stout claws. The eggs were also characterized by small size, short and dark blue in color and causing hairs to bend at the point of attachment. These were characteristics of the blood sucking louse genus *Solenoptes*. These were compared to standard veterinary parasitological books such as (Soulsby, 1982, Urquhart, 1996, Wall and Shearer, 2001) and found to be similar. Only one species in the genus *Solenoptes* is of veterinary importance: the little blue cattle louse, *Solenoptes capillatus*. *S. capillatus* is the smallest of the anopluran lice found on cattle at about 1.2-1.5mm in length. Eyes and ocular points are absent.

Chemical treatments, including pour-on and dip insecticides, have historically been the primary method of louse control on cattle (Townsend 2000, Kaufman et al. 2001, White 2007). Recently, formulations administered subcutaneously have also been shown to be successful at treating lice (Cleale et al. 2004). In the present case, 1% ivermectin subcutaneously at a dose of 0.2 mg/kg body weight was given. This is one of the currently developed formulations mentioned by (Cleale et al. 2004). Many new systemic insecticides require only one treatment for long-term louse control, but organophosphates and pyrethroids require two applications (Townsend 2000). Some formulations of pyrethroids and avermectin derivative-type treatments are the current recommendations for control of lice on lactating dairy cattle (Nafstad and Grønstøl 2001).

Discussion of the strengths and limitations in your approach to this case

Discussion of the relevant medical literature

The rationale for conclusions (including assessment of possible causes)

The primary “take-away” lessons of this case report.

References

1. SOULSBY E.J. (1982): Helminthes, Arthropods and protozoa of domestic animals, 7th ed., BAILLIERE and TINDALL (eds), London,England, Pp. 357-504.Wall and Shearer, 2001
2. Soulsby, E.J.L., 1982. Helminthes, Arthropod and protozoa of Domestic Animals, 7th ed.; BaillereTindall, London, UK, Pp.????40-52.
3. Urquhart, G. M. (George M.), 1925- 1996, *Veterinary parasitology*, 2nd ed, Blackwell Science, Oxford, U.K
4. Wall and Shearer (2001)
5. Cleale RM, Lloyd JE, Smith LL, Grubbs MA, Grubbs ST, Kumar R, Amodie DM. 2004 Persistent activity of moxidectin long-acting injectable formulations against natural and experimentally enhanced populations

- of lice infesting cattle. *Veterinary Parasitology* 120: 215-227.
6. White WH, Hutchens DE, Jones C, Larry D, Firkins LD, Paul AJ, Smith LL, Snyder DE. 2007. Therapeutic and persistent efficacy of spinosad applied as a pour-on or a topical spray against natural infestations of chewing and sucking lice on cattle. *Veterinary Parasitology* 143: 329-336.
 7. Kaufman PE, Rutz DA, Doscher ME, Albright R. 2001. Efficacy of chlorfenapyr (AC 303630) experimental pour-on and CyLence® formulations against naturally acquired louse infestations on cattle in New York. *Veterinary Parasitology* 97: 123-129.
 8. Holdsworth PA, Vercruyse J, Rehbein S, Peter RJ, Letonja T, Green P. 2006. World Association for the Advancement of Veterinary Parasitology (W.A.A.V.P.) guidelines for evaluating the efficacy of ectoparasiticides against biting lice, sucking lice and sheep keds on ruminants. *Veterinary Parasitology* 136: 45-54.
 9. Nafstad O, Grønstøl H. 2001. Eradication of lice in cattle. *Acta Veterinaria Scandinavica* 42: 81-89.
 10. Watson DW, Lloyd JE, Kumar R. 1997. Density and distribution of cattle lice (Phthiraptera: Haematopinidae, Linognathidae, Trichodectidae) on six steers. *Veterinary Parasitology* 69: 283-296.
 11. Durden LA, Musser GG. 1994. The sucking lice (Insecta: Anoplura) of the world: A taxonomic checklist with records of mammalian hosts and geographical distributions. *Bulletin of the American Museum of Natural History* No. 218, 90 p.
 12. Urquhart, G. M. et al., (George M.), 1996, *Veterinary parasitology*, 2nd ed, Blackwell Science, Oxford, U.K
 13. Hussain M A, Khan M N, Iqbal Z, Sajid M S and Arshad M (2006). "Bovine pediculosis: prevalence and chemotherapeutic control in Pakistan *Livestock Research for Rural Development* 18 (145). Retrieved 2008-10-08
 14. *The Merck Veterinary Manual*. Whitehouse Station, NJ USA: Merck & Co. 2008
 15. Townsend L. (2000): Lice on beef and dairy cattle. University of Kentucky Cooperative Extension Service. <http://www.ca.uky.edu/entomology/entfacts/entfactpdf/ef512.pdf> Retrieved on December 14, 2014).

common name: little blue cattle louse

scientific name: *Solenopotes capillatus* (Enderlein) (Insecta: Phthiraptera: Anoplura: Linognathidae)

Introduction - Distribution - Description - Biology - Hosts - Economic Importance - Management - Selected References

Introduction (Back to Top)

Of the five sucking lice that feed on cattle in Florida (Kaufman et al. 2007), *Solenopotes capillatus* (Enderlein) is the smallest in size (Grubbs et al. 2007). The little blue cattle louse, as it is commonly called, is in the family Linognathidae (the pale lice) and is one of the nine currently recognized species in the genus *Solenopotes* (Durden and Musser 1994).



Figure 1. Adult little blue cattle louse, *Solenopotes capillatus* (Enderlein). Illustration by Ellen Edmonson, Cornell University Agricultural Experiment Station, Bulletin No. 832. Used with permission.

Distribution (Back to Top)

Solenopotes capillatus is found throughout the world but is generally restricted to areas with domestic livestock. *Solenopotes capillatus* was reported by Kim to be most frequent sucking louse encountered on Korea's livestock

(as cited in Price and Graham 1997), and the louse was also identified in Europe and Australia in the early part of the 20th century (Matthysse 1946). Discovered in the United States in 1917, but not reported until 1921, the little blue cattle louse is the most abundant sucking cattle louse species in Wyoming and many areas of the east and southeast (Matthysse 1946, Price and Graham 1997).

Description (Back to Top)

Eggs: The female louse lays one to two 0.7 mm eggs per day, each attached to a hair. Often the hair is bent, a feature not observed with other cattle lice.

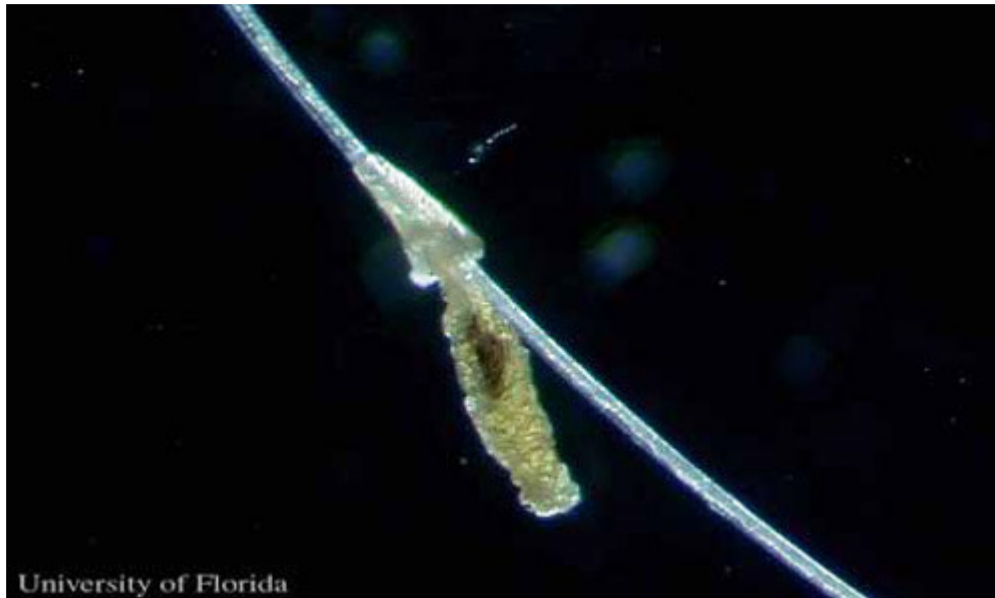

Figure 2. Egg of the little blue cattle louse, *Solenopotes capillatus* (Enderlein), cemented to a hair. Photograph by Kevyn J. Juneau, University of Florida.

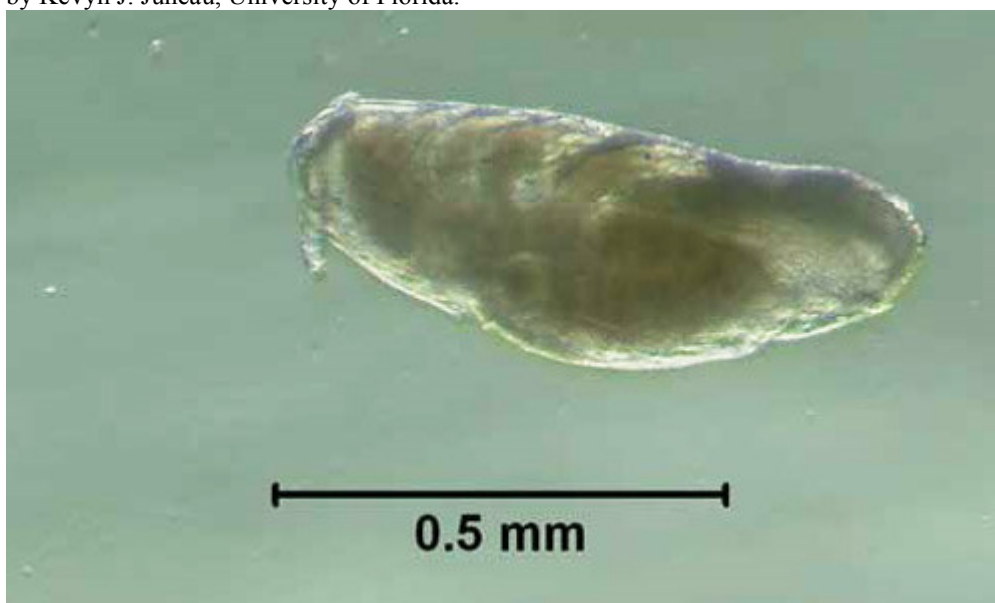


Figure 3. Egg, with embryo present, of the little blue cattle louse, *Solenopotes capillatus* (Enderlein). Photograph by Kevyn J. Juneau, University of Florida.

Nymphs: First instars are smaller than the eggs at 0.69 mm and successively grow to 1.06 mm as a third instar.

Adults: *Solenopotes capillatus* has a short broad head, broad sensoria on segments four and five of the antennae, and it has a hexagonal shaped sternal plate on the thorax (Ignoffo 1959). The front tarsal claws are the smallest of the three pairs. The middle and hind tarsal claws are approximately the same size. *Solenopotes capillatus* has prominent abdominal tubercles that bear the spiracles. Adult males measure 1.08 mm, similar to that of the third instars, while the adult females are 1.5 mm in length.



Figure 4. Ventral view of an adult little blue cattle louse, *Solenopotes capillatus* (Enderlein). Photograph by Kevyn J. Juneau, University of Florida.

Biology (Back to Top)

Solenopotes capillatus is a small louse, often confused with *Linognathus vituli* nymphs (Matthysse 1946), that feeds on the head, primarily the face and jaw regions, with sporadic occurrences on other body regions (Watson et al. 1997) of domestic livestock and captive ungulates. Once an individual establishes itself on a host, it rarely relocates on the host's body (Skogerboe et al. 2000).

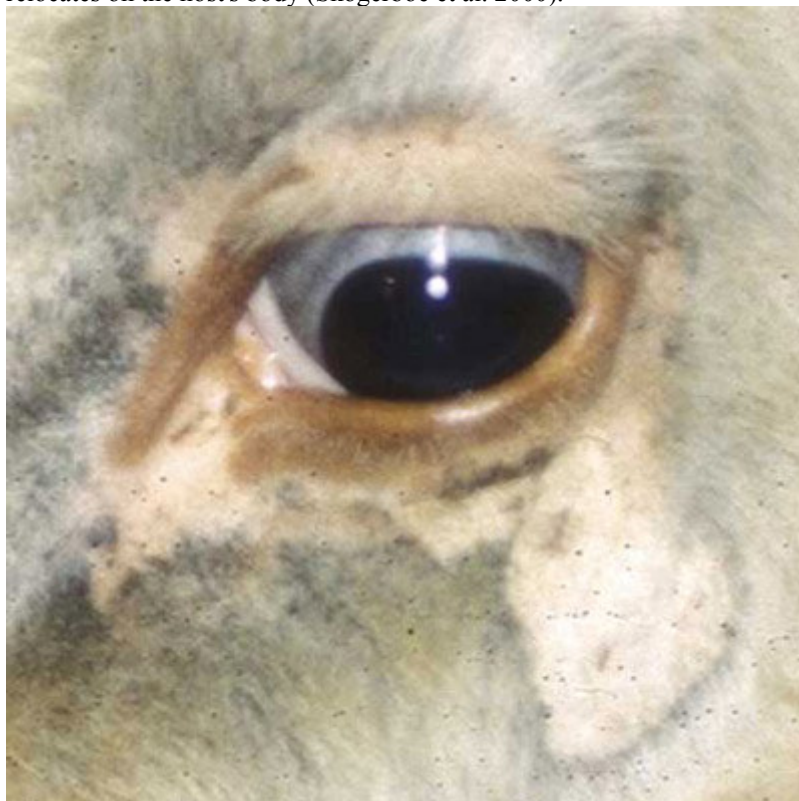

Figure 5. Infestation of the little blue cattle louse, *Solenopotes capillatus* (Enderlein), around the eye of a cow. Photograph by Phillip Kaufman, University of Florida.

The incubation period for the egg is about 12 days, and *S. capillatus* nymphs have three instars that each take approximately four to five days to develop. There is a preoviposition period of two days before the adult female begins to lay eggs. In total, it takes approximately 28 days to complete a life cycle from egg to oviposition.

Hosts (Back to Top)

Solenopotes capillatus feeds on a variety of ungulates but are most prolific on captive ungulates in zoos, such as gazelles (Yeruham et al. 1999), and those used for agriculture, specifically cattle. *Solenopotes capillatus* congregate mostly on the face and may be so plentiful that the host appears to be wearing glasses (Townsend 2000). The lice are spread through direct contact between the cattle during mating, nursing, or other interactions such as herding. Older cows with longer hair and bulls that have large body mass are more prone to infestation because of the difficulty with self-grooming (Townsend 2000).

Economic Importance (Back to Top)

Like most cattle lice, *S. capillatus* can cause irritation, restlessness, and some studies suggest lice may be linked to a decrease in milk production and poor quality hides for harvest (Nafstad and Grønstøl 2001). Lice infestations cause the animal to scratch the areas infested, resulting in lesions or abrasions and areas of alopecia (hair loss) that can lead to bacterial or viral infections and insect infestations that cause the animal to become ill. A heavy load of lice may also cause the animal to become anemic (Holdsworth et al. 2006).

Management (Back to Top)

Chemical control. Chemical treatments, including pour-on and dip insecticides, have historically been the primary method of louse control on cattle (Townsend 2000, Kaufman et al. 2001, White 2007). Recently, formulations administered subcutaneously have also been shown to be successful at treating lice (Cleale et al. 2004). Many new systemic insecticides require only one treatment for long-term louse control, but organophosphates and pyrethroids require two applications (Townsend 2000). Some formulations of pyrethroids and avermectin derivative-type treatments are the current recommendations for control of lice on lactating dairy cattle (Nafstad and Grønstøl 2001). Dust bags placed in locations where the cattle are forced to use them provide easy application of insecticides (Kaufman et al. 2007).



Figure 6. Dust bag used to apply insecticides to cows.

New cattle brought to a farm should be treated with an appropriate insecticide and kept separate from the herd until there is significant evidence that the animal is free of lice. This will eliminate the spread of lice between farms to reduce the chance of future infestations.

Non-chemical control. Clipping the animal's hair may help control the lice by rendering the microhabitat unsuitable (Allen and Dicke 1952). Providing special clothes and boots for visitors, especially veterinarians, may also reduce the chance of contaminating a louse-free farm (Nafstad and Grønstøl 2001).

For additional information on cattle lice and their control, see the following University of Florida publications:

- [External Parasites of Dairy Cattle](#)
- [External Parasites on Beef Cattle](#)
- [Cattle Tail Lice](#)

- [Management of External Parasites with Forced-Use Dust Bags](#)
- [Management of External Parasites on Beef Cattle](#)

Selected References (Back to Top)

- Allen NN, Dicke RJ. 1952. Cattle lice control by clipping. *Journal of Economic Entomology* 45: 970-973.
- Cleale RM, Lloyd JE, Smith LL, Grubbs MA, Grubbs ST, Kumar R, Amodie DM. 2004 Persistent activity of moxidectin long-acting injectable formulations against natural and experimentally enhanced populations of lice infesting cattle. *Veterinary Parasitology* 120: 215-227.
- Durden LA, Musser GG. 1994. The sucking lice (Insecta: Anoplura) of the world: A taxonomic checklist with records of mammalian hosts and geographical distributions. *Bulletin of the American Museum of Natural History* No. 218, 90 p.
- Ignoffo C. 1959. Key and notes to the Anoplura of Minnesota. *American Midland Naturalist*. 61: 470-479.
- Grubbs MA, Lloyd JE, Kumar R. 2007. Life cycle details of *Solenopotes capillatus* (Anoplura: Linognathidae). *Journal of Economic Entomology* 100: 619-621.
- Holdsworth PA, Vercruysse J, Rehbein S, Peter RJ, Letonja T, Green P. 2006. World Association for the Advancement of Veterinary Parasitology (W.A.A.V.P.) guidelines for evaluating the efficacy of ectoparasiticides against biting lice, sucking lice and sheep keds on ruminants. *Veterinary Parasitology* 136: 45-54.
- Kaufman PE, Koehler PG, Butler JF. (2007). External parasites on beef cattle. *EDIS*. <http://edis.ifas.ufl.edu/pdf/IG/IG13000.pdf> (14 November 2007).
- Kaufman PE, Rutz DA, Doscher ME, Albright R. 2001. Efficacy of chlorfenapyr (AC 303630) experimental pour-on and CyLence® formulations against naturally acquired louse infestations on cattle in New York. *Veterinary Parasitology* 97: 123-129.
- Matthyse JG. 1946. Cattle lice: Their biology and control. Cornell University Agricultural Experiment Station Bulletin No. 832, 67 p.
- Nafstad O, Grønstøl H. 2001. Eradication of lice in cattle. *Acta Veterinaria Scandinavica* 42: 81-89.
- Price MA, Graham OH. 1997. Chewing and sucking lice as parasites of mammals and birds. U.S. Department of Agriculture Technical Service Bulletin No. 1849, 309 p.
- Skogerboe TL, Smith LL, Karle VK, Derozier CL. 2000. The persistent efficacy of doramectin pour-on against biting and sucking louse infestations of cattle. *Veterinary Parasitology* 87: 183-192.
- Townsend L. (October 2000) Lice on beef and dairy cattle. University of Kentucky Cooperative Extension Service. <http://www.ca.uky.edu/entomology/entfacts/entfactpdf/ef512.pdf> (14 November 2007).
- Watson DW, Lloyd JE, Kumar R. 1997. Density and distribution of cattle lice (Phthiraptera: Haematopinidae, Linognathidae, Trichodectidae) on six steers. *Veterinary Parasitology* 69: 283-296.
- White WH, Hutchens DE, Jones C, Larry D, Firkins LD, Paul AJ, Smith LL, Snyder DE. 2007. Therapeutic and persistent efficacy of spinosad applied as a pour-on or a topical spray against natural infestations of chewing and sucking lice on cattle. *Veterinary Parasitology* 143: 329-336.
- Yeruham I, Rosen S, Hadani A, Braverman Y. 1999. Arthropod parasites of nubian ibexes (*Capra ibex nubiana*) and gazelles (*Gazella gazella*) in Israel. *Veterinary Parasitology* 83: 167-173.

The sucking lice (Anoplura) are usually small insect; adults are about 2mm long on average, but some species of Anoplura may be as small as 0.5 mm in length or as large as 8mm in length. Characteristically the head is small in relation to body size but narrow and elongated. In medical entomology, lice are most well known as vectors of important human diseases such as typhus and louse-borne relapsing fever.

The IISTE is a pioneer in the Open-Access hosting service and academic event management. The aim of the firm is Accelerating Global Knowledge Sharing.

More information about the firm can be found on the homepage:

<http://www.iiste.org>

CALL FOR JOURNAL PAPERS

There are more than 30 peer-reviewed academic journals hosted under the hosting platform.

Prospective authors of journals can find the submission instruction on the following page: <http://www.iiste.org/journals/> All the journals articles are available online to the readers all over the world without financial, legal, or technical barriers other than those inseparable from gaining access to the internet itself. Paper version of the journals is also available upon request of readers and authors.

MORE RESOURCES

Book publication information: <http://www.iiste.org/book/>

Academic conference: <http://www.iiste.org/conference/upcoming-conferences-call-for-paper/>

IISTE Knowledge Sharing Partners

EBSCO, Index Copernicus, Ulrich's Periodicals Directory, JournalTOCS, PKP Open Archives Harvester, Bielefeld Academic Search Engine, Elektronische Zeitschriftenbibliothek EZB, Open J-Gate, OCLC WorldCat, Universe Digital Library, NewJour, Google Scholar

