

# Review on Major Gastrointestinal Parasites that Affect Chickens

Abebe Belete\*

School of Veterinary Medicine, College of Agriculture and Veterinary Medicine, Jimma University, P.O. Box:  
307, Jimma, Ethiopia

Mekonnen Addis

School of Veterinary Medicine, College of Agriculture and Veterinary Medicine, Jimma University, P.O. Box:  
307, Jimma, Ethiopia

Mihretu Ayele

Department of animal health, Alage Agricultural TVET College, Ministry of Agriculture and Natural Resource,  
Ethiopia

## Abstract

Parasitic diseases are among the major constraints of poultry production. The common internal parasitic infections occur in poultry include gastrointestinal helminthes (cestodes, nematodes) and *Eimeria* species. Nematodes belong to the phylum Nematelminthes, class Nematoda; whereas Tapeworms belong to the phylum Platyhelminthes, class Cestoda. Nematodes are the most common and most important helminth species and more than 50 species have been described in poultry; the majority of which cause pathological damage to the host. The life cycle of gastrointestinal nematodes of poultry may be direct or indirect but Cestodes have a typical indirect life cycle with one intermediate host. The life cycle of *Eimeria* species starts with the ingestion of mature oocysts; and each infective oocyst is formed by four sporocysts; and in turn by which each sporocyst contains two sporozoites. Diagnosis of gastrointestinal parasites would be done by direct smear and floatation techniques for faecal samples; but to be confident none is comparable with postmortem examination since it may allow investigating the adults together with pathological lesions. Helminth infections are known to cause interference with host metabolism; and Coccidiosis induced by *Eimeria* species infection is an important parasitic disease of poultry which generates economic losses due to morbidity, mortality, reduced body weight, and the expenses related to preventive or therapeutic control and/or vaccinations. Some worms require an intermediary host, such as earthworms, snails, insects etc., and consequently preventing contact with these invertebrates is an obvious step in control and prevention.

**Keywords:** Chickens, Nematodes, Cestodes, *Eimeria* Species.

## 1. INTRODUCTION

Disease is among the major constraints of poultry production (Hunduma *et al.*, 2010). The common internal parasitic infections occur in poultry include gastrointestinal helminthes (cestodes, nematodes) and *Eimeria* species that cause considerable damage and great economic losses to the poultry industry due to malnutrition, decreased feed conversion ratio, weight loss, lowered egg production and death in young birds (Puttalakshamma, 2008). Furthermore, parasites can make the flock less resistant to diseases and exacerbate existing disease conditions (Gary and Richard, 2012; Katoch *et al.*, 2012).

Coccidiosis induced by *Eimeria* species infection is an important parasitic disease of poultry. Poultry coccidiosis generates economic losses due to morbidity, mortality, reduced body weight plus the expenses related to preventive or therapeutic control and/or vaccinations (Williams, 1999; Dalloul and Lillehoj, 2006). It is probably the most common disease in modern poultry production, where confinement rearing is practiced (Lorenzoni, 2010; and Amare *et al.*, 2012). Helminth infections are known to cause interference with host metabolism resulting in poor feed utilization and reduced growth rate as well as size and age at maturity and these have been described as common characteristics of village chickens (Permin and Hansen, 1998).

However, parasitic infestations are usually conjoint. The concurrent infestations with two or more parasites, especially those with gastrointestinal predilection, heighten their role in early chick mortality and other productivity losses among the adults. This is particularly true of conjoint infestations with helminthes and coccidia whose combined effects on host could be devastating (Nnadi and George, 2010).

As stated by CSA (2012) and Permin and Hansen (1998), improvement in veterinary services and setting-up of strategies, to prevent and control diseases; would be possible if descriptive data on prevalence of diseases, vaccinations, and treatments are available. As a result, the objective of the review was: to review and compile information related to gastrointestinal parasites (Nematodes, Cestodes and *Eimeria* Species) of chickens.

## 2. LITERATURE REVIEW

### 2.1. Background of Gastrointestinal parasites

Worms are classified as Nematodes (Roundworms) or Cestodes (Tapeworms). Some worms require an intermediary host, such as earthworms, snails, insects etc., and consequently preventing contact with these invertebrates is an obvious step in control and prevention (Leeson and Summer, 2009). Nematodes are the most common and most important helminth species in poultry. More than 50 species have been described in poultry. Of these, the majority causes pathological damage to the host (Permin and Hansen, 1998).

**Table:** Gastrointestinal helminthes and preferred sites of infection in domestic fowl.

Parasite species	Preferred site(s) of infection
<b>Cestodes</b>	
<i>Choanotaenia infundibulum</i>	Small intestine
<i>Reillietina tetragona</i>	Small intestine, Large intestine
<i>Raillietina cesticillus</i>	Small intestine
<i>Raillietina echinobothrida</i>	Small intestine, Large intestine
<i>Davainea proglottina</i>	Small intestine
<b>Nematodes</b>	
<i>Ascaridia galli</i>	Small intestine, Large intestine
<i>Heterakis gallinarum</i>	Caecum
<i>Capillaria caudinflata</i>	Small intestine
<i>Strongyloides avium</i>	Small intestine
<i>Trichostrongylus tenuis</i>	Small intestine
<i>Subulura brumpti</i>	Small intestine

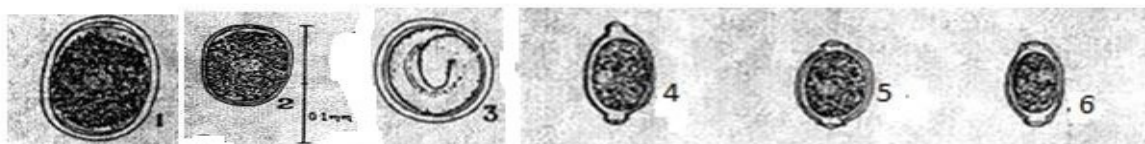
**Source:** (Ohaeri and Okwum, 2013).

Coccidiosis, caused by the protozoan *Eimeria*, is a common disease in poultry. There are nine described species of *Eimeria* infecting chickens: *Eimeria acervulina*, *Eimeria brunetti*, *Eimeria maxima*, *Eimeria mitis*, *Eimeria necatrix*, *Eimeria praecox*, *Eimeria tenella*, *Eimeria mivati*, and *Eimeria hagani*. A severe infection may lead to weight loss and sometimes high mortality, depending on the species or strain present. The severity of the disease and clinical characteristics of the infection differ among *Eimeria* species, and precise identification of the species affecting the flock is essential for monitoring and control of coccidiosis and plays a key role in selection of appropriate treatment measures (Martynova-VanKley *et al.*, 2008).

### 2.2. Characteristics of Nematodes, Cestodes, and Eimeria Species

#### 2.2.1. Nematodes

Nematodes belong to the phylum Nematelminthes, class Nematoda. The nematodes of poultry are parasitic, unsegmented worms. The shape is usually cylindrical and elongated, but the cuticle may have circular annulations, be smooth, have longitudinal striations or ornamentations in the form of cuticular plaques or spines. All worms have an alimentary tract. The sexes are separate. The life cycle may be direct or indirect including an intermediate host (Permin and Hansen, 1998). The Nematodes or roundworms are the most common internal parasites of chickens. These include *Ascaridia galli* (intestine), *Heterakis gallinarum* (ceca) and various *Capillaria species* (crop→intestine) found through the digestive. As a group, the Nematodes are characterized by being long spindle shaped worms varying in color from off-white to creamy yellow (Leeson and Summer, 2009). *Capillaria contorta* and the *Capillaria obsignata* are parasites of the crop and intestine respectively. *Ascaridia galli* occurs in the jejunum and *Heterakis gallinarum* in the cecum (Simon and Emeritus, 2005).



**Figure 1:** Eggs of some nematode parasites of fowls.

1. *Ascaridia galli*, 2. *Heterakis gallinarum*, 3. *Subulura brumpti*, and 4, 5, and 6. *Capillaria species*. Modified from Kassa, (2005).

*Ascaridia galli*: it is a parasitic roundworm belonging to the phylum Nematoda. *Ascaridia galli* is the most prevalent and pathogenic species, especially in domestic fowl, *Gallus domesticus*. It causes ascariasis, a disease of poultry due to heavy worm infection, particularly in chicken and turkeys. It inhabits the small intestine, and can be occasionally seen in commercial eggs (Griffiths, 1978). It is the largest nematode in birds. The body is semitransparent, creamy-white and cylindrical. The anterior end is characterized by a prominent mouth, which is surrounded by three large tri-lobed lips. The edges of the lips bear teeth-like denticles (Ashour, 1994). The

body is entirely covered with a thick proteinaceous structure called cuticle. The cuticle is striated transversely throughout the length of the body and cuticular alae are poorly developed. Two conspicuous papillae are situated on the dorsal lip and one on each of the sub ventral lips (Lalchhandama *et al.*, 2009 and Lalchhandama, 2010). These papillae are the sensory organs of the nematode. *Ascaridia galli* is dieocious with distinct sexual dimorphism. Females are considerably longer and more robust, with vulva opening at the middle portion (approximately midway from anterior and posterior ends) of the body and anus at the posterior end of the body. The tail end of females is characteristically blunt and straight. Males are relatively shorter and smaller, with a distinct pointed and curved tail (Ramadan, 1992). There are also ten pairs of caudal papillae towards the tail region of the body, and they are arranged linearly in well-defined groups such as precloacal (3 pairs), cloacal (1 pair), post-cloacal (1 pair) and subterminal (3 pairs) papillae. The eggs are elliptical, thick-shelled and are not embryonated at the time of deposition. They measure 73-92 x 45-57  $\mu\text{m}$  (Soulsby, 1982; Ruff, 1991; Urquart *et al.*, 1996).

*Heterakis gallinarum*: It is a small, white caecal worm having 3 small equal sized lips on the mouth and has 2 lateral membranes extending almost the entire length of its body. The worm has a distinct oesophagus, ending in a well-developed bulb containing a vulvar apparatus (Urquart *et al.*, 1996). The male is 7-13 mm long, having a well-developed preanal sucker and long alae with 12 pairs of papillae. The spicules are not equal, with the right spicule being slender and 2 mm long and the left being broad and measuring 0.37-1.9 mm long. The female is 10-15 mm long. Its vulva is prominent and is positioned slightly to the middle of the body. It has a long and narrow tail with eggs that are thick-shelled, ellipsoid and unsegmented when deposited. They measure approximately 63-75 x 36-50  $\mu\text{m}$  (Soulsby, 1982; Hall, 1985; Permin and Hansen, 1998).

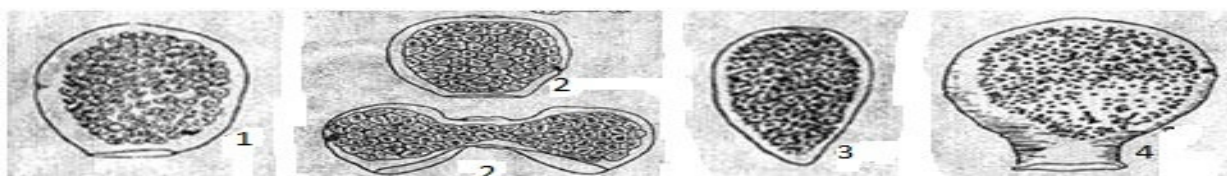
*Capillaria species*: Six *Capillaria* species are commonly found in poultry: *C. annulata*, *C. contorta*, *C. caudinflata*, *C. bursata*, *C. obsignata* (Synonym, *C. columbae*) and *C. anatis*. All six species have been reported to occur in domesticated and wild birds. Furthermore, all species are cosmopolitan in their distribution (Soulsby, 1982). The *Capillaria* species are located throughout the intestinal tract. *C. annulata* and *C. contorta* are found in the crop and in the oesophagus. *C. caudinflata*, *C. bursata* and *C. obsignata* parasitizes the small intestine, whereas *C. anatis* occurs in the caeca. The worms of this genus are small and hair like and difficult to detect in the intestinal content. The *C. annulata* males are 15 - 25 mm long and the females are 37 - 80 mm long. The characteristic eggs have bipolar plugs and measure 60 x 25  $\mu\text{m}$ . *C. contorta* males are equal in size to the males of *C. annulata*, but the females are shorter only measuring 27 - 38 mm. The eggs of *C. contorta* are app. 60 x 25  $\mu\text{m}$ . *C. caudinflata*, *C. bursata*, *C. obsignata* and *C. anatis* are all smaller only measuring 6 - 35 mm. The eggs measure 45 x 25  $\mu\text{m}$  (Permin and Hansen, 1998).

*Subulura brumpti*: It is very common in chickens, turkeys, guineafowls, ducks, pheasants, grouse and quails in North and South America, Africa and Asia (Soulsby, 1982). The adult worms occur in the lumen of the caeca. The males are 7 - 10 mm long and the females measure 9- 18 mm. The eggs are spherical and thin-shelled, 52-64 x 41-49  $\mu\text{m}$ . The adult worms are quite similar in shape and size to *Heterakis* spp. and can be differentiated by microscopical examination of the oesophagus and the spicules (Urquart *et al.*, 1996).

### 2.2.2. Cestodes

Tapeworms belong to the phylum Platyhelminthes, class Cestoda. The tapeworms of poultry are all endoparasitic, hermaphroditic worms with a flat, long segmented body without an alimentary tract or body cavity. Poultry tapeworms may reach a length of 30 - 50 cm. They have a scolex (the head) followed by a neck. The rest of the body is called the strobila consisting of a number of proglottids (segments) developing from the neck. Each segment contains a set of reproductive organs. The number of segments differs between species. The segments furthest away from the neck mature and are detached from the body. These gravid segments contain numerous eggs which are released to the environment with the faeces (Permin and Hansen, 1998).

The most commonly diagnosed Cestodes include: *Davainea progottina* - a 4 mm Cestode located in the duodenum. *Choanotaenia infundibulum* - a 25 cm Cestode located in the distal duodenum and jejunum. *Raillietina tetragona* - a 25 cm Cestode located in the distal jejunum. *Raillietina echinobothridia* - a 30 cm Cestode of the jejunum resulting in nodular granulomas and catarrhal enteritis (Simon and Emeritus, 2005).



**Figure 2:** Eggs of some cestode parasites of fowls.

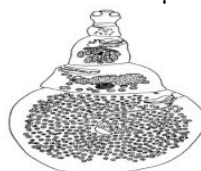1. *Raillietinma cestiocillus* 2. *Raillietina echinobothrida* 3. *Davainea progottina* 4. *Chaonotaenia infundibulum*. Modified from Kassa, (2005).

*Raillietinna cestiocillus* and *Raillietinna echinobothrida*: *Raillietina* is the name for a genus of tapeworms that

includes helminth parasites of vertebrates, mostly of birds. The genus was named in 1920 in honour of a French veterinarian and helminthologist, Louis-Joseph Alcide Railliet. Of the 37 species recorded under the genus, *R. echinobothrida*, *R. tetragona*, and *R. cesticillus* are the most important species in terms of prevalence and pathogenicity among wild and domestic birds (Cheng, 1986; McDougald, 2011)

The body of an adult Raillietina is a typical tapeworm structure, composed of a series of ribbon-like body segments, gradually enlarging from the anterior end towards the posterior. It is whitish in colour, highly elongated, dorso-ventrally flat, and entirely covered with a tegument. The entire body is divisible into 3 parts, namely the head region called scolex, followed by an unsegmented neck or growth region, and then by highly segmented body proper called strobila (Mu *et al.*, 2009). The scolex is a bulbous knob-like structure bearing suckers and a rostellum, which are the organs of attachment to the host. A defining structure from those of other tapeworms is a single prominent rostellum surrounded by four suckers (Lalchandama, 2009). Further, an important diagnostic character among the different species of the genus is the number and arrangement of hooks and spines on the scolex (Kaufmann, 1996). The suckers are poorly developed, and completely devoid of special devices or spines (Hambridge, 2011). The scolex measures approximately 134  $\mu$  in diameter and the hooks are 7-10  $\mu$  in length. Individual segments in the strobila are called 'proglottids' and are entirely covered with hair-like microtriches (Radha *et al.*, 2006). These microtriches are the absorptive structures for feeding, and there are no digestive organs. As all other cestodes, they are hermaphrodite. A set of both male and female reproductive systems is present in each proglottid (Baker, 2008).

*Davainea proglottina*: they are also called the minute tapeworm or the small chicken tapeworm, is a parasitic worm that has chicken, turkey, guineafowl, grouse, other domestic and wild gallinaceous birds but also pigeons as final hosts. The worms are buried in the mucosa of the duodenum. The adult tape worms are small, 0.5 - 3 mm, with 4 to 9 proglottids. The eggs measure 28 - 40  $\mu$ m ((Permin and Hansen, 1998)).



**Figure 3:** Adult *Davainea proglottina*. **Source:** Permin and Hansen, (1998).

*Choanotaenia infundibulum*: The worms are attached to the mucosa in the upper half of the small intestine. The mature worms reach a length of up to 23 cm and may be 1.5 - 3 mm wide. The segments are clearly wider at the posterior end of the parasite. The eggs have a distinctly long filament and measure 47 x 54,  $\mu$ m (Soulsby, 1982).

### 2.2.3. Eimeria species

Important species of Eimeria in chickens may include *Eimeria tenella*, *E. necatrix*, *E. brunetti*, *E. maxima*, *E. mitis* and *E. acervulina*. Identification can be made at microscopic level, either by examining the faeces for the presence of oocysts or by examination of scrapings or histological sections of affected tissues. In domestic poultry, coccidiosis can conveniently be divided into caecal and intestinal coccidiosis (Urquhart *et al.*, 1996). *Eimeria* is a genus of Apicomplexan parasites that includes various species responsible for the poultry form of the disease coccidiosis. Eimeria are obligate intracellular parasites with complex life cycles including sexual and asexual stages (Lorenzoni, 2010). When the oocysts are expelled in the faeces they are spheric in shape and not embryonated. They measure 16 x 42  $\mu$ m. During sporulation 4 sporocysts are formed each containing two sporozoites (Permin and Hansen, 1998). *Eimeria* species are frequently described from the morphology of the oocyst, a thickwalled zygote shed in faecal material by the infected host. Oocysts are enclosed in a thick outer shell and consist of a single cell that begins the process of sporulation to yield the infective stage in about 48 hours. Infective oocyst contains four sporocysts, which in turn contain two sporozoites. A membrane consists from three layers (one layer of lipoprotein between two layers of protein) locomotion by contraction. *Eimeria* species secretes enzymes to destroy host cell membrane and gets oxygen results from digest nutrients (Saif *et al.*, 2003).

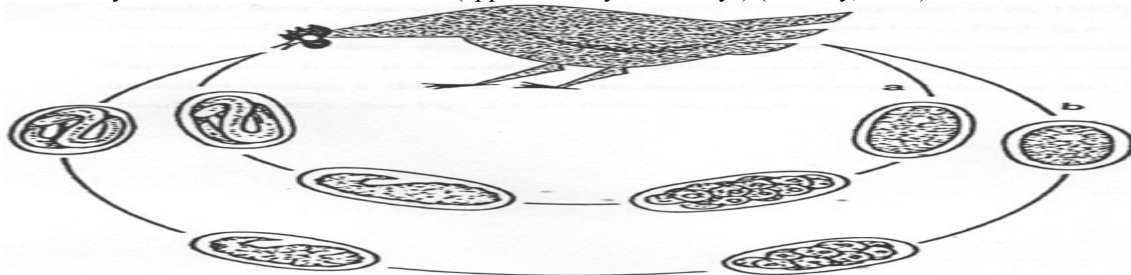
## 2.3. General Life Cycles of Nematodes, Cestodes, and Eimeria Species

### 2.3.1. Nematodes

The life cycle of gastrointestinal nematodes of poultry may have a direct, or an indirect life cycle. The nematodes of poultry that exhibit a direct life cycle; for example *Ascaridia galli* and *Heterakis gallinarum*, do not require an intermediate host to complete their life cycle of development. The infected birds pass the helminth eggs in their droppings, contaminating the litter, feed, and water. This then possess as the main way by which the infection is transmitted (Ruff, 1991). Mechanical transmission by earthworms or cockroaches has been reported by Hall (1985) and there is no development of the larval stage inside these carriers. When the susceptible fowl



ingest the infective eggs or carrier hosts, the larvae then penetrate the mucosa of the duodenum and develop to reach maturity and enter the intestinal lumen (approximately 28-30 days) (Soulsby, 1982).



**Figure 4:** Direct life cycle of nematodes.

The life cycle of *A. galli* (a) and *H.gallinarum* (b). Eggs are passed with the faeces and embryonation of the eggs takes place in the environment. Susceptible host then ingests infective eggs (with L3 larvae). Occasionally earth worms can act as transport hosts (Permin and Hansen, 1998).

The life cycle of *Ascaridia galli* can be a representative example: The life cycle of *A. galli* is direct in a single host, involving two principal populations, namely the sexually mature parasite in the gastrointestinal tract and the infective stage (L3). Larvae do not hatch but moult inside the eggs until they reach the L3 stage. This can take about two weeks but the period depends on other factors such as the weather condition. The life cycle is completed when the infective eggs are ingested by new hosts through contaminated water or feed. The eggs containing the L3-larvae are mechanically transported to the duodenum. The infective eggs are ingested by a chicken where it reaches the proventriculus and hatches (Anderson, 2000). Temperature, carbon dioxide levels and pH are thought to be triggering factors that signal the larva to hatch from its egg. The larva then burrows into the mucosal lining of the small intestine where it undergoes two additional moults. It is this phase of their life cycle where these worms cause the most damage to their host. They then re-enter the small intestine and develop into adults where they live their lives out feeding on gut content and making a vast amount of eggs that would then be excreted by a host and free to continue their life cycle. If the animal is able to mount an immune response to the larvae, i.e. from pre-exposure, the larvae do not develop into adults but hide in the mucosa of the small intestine. This is common for infection of older birds. Transport hosts such as earthworms are thought to play a role in transmission of *A. galli* and hence, free range birds tend to have a higher risk of infection (Jacobs *et al.*, 2003).

The nematode parasites of poultry that exhibit an indirect life cycle require an intermediate host to complete their life cycle of development; an example here is *Subulura brumpti* with cockroaches and beetles as intermediate hosts (Ruff, 1991). After the eggs have passed with the faeces they develop in the intermediate hosts finally encapsulating in the intestinal wall after 7-8 days. After another 7 days in the intermediate host the infective L<sub>3</sub> larvae have developed. The final host becomes infected when ingesting the infected beetles or cockroaches. The larvae migrate to the caeca and develop into adults in 6 weeks (Soulsby, 1982). Therefore, in an indirect life cycle when the infected fowl pass their droppings, the intermediate hosts feeding on the droppings pick up the embryonated eggs. The development to infective stage then occurs inside the intermediate host (i.e. cockroach, beetles, weevils, and among others, grasshoppers). Infection within a flock is then transmitted by fowl feeding on the intermediate hosts (Soulsby, 1982; Permin and Hansen, 1998).



**Figure 5:** Indirect life cycle of nematodes.

The life cycle of *Tetrameres Americana* (a) and *Subulura brumpti* (b), with embryonated eggs passed in the faeces. The eggs are ingested by the intermediate host such as cockroach, beetles, weevils among others and within which the larvae undergoes development to the infective stage (L3). When the final host ingests the intermediate hosts, the adult worms develop in the proventriculus of the host (Ziela, 1999).

The life cycles of the *Capillaria* species may be direct or indirect. The eggs are deposited with the

faeces unembryonated and develop into the first larval stage in 9 to 14 days. For *C. obsignata*, *C. anatis* and *C. contorta* the life cycle is direct, which means that the eggs are infective to susceptible hosts as embryonated L<sub>1</sub> (Ruff, 1991). After ingestion the eggs hatch at their predilection site and develop into adult worms without migration in the host. Eggs of the species *C. caudinflata*, *C. bursata* and *C. annulata* are swallowed by earthworms and develop into infective stages in 14 - 21 days. Birds are infected when ingesting the earthworms. The prepatent time for Capillaria species is approximately 3 weeks (Urquart *et al.*, 1996).

### 2.3.2. Cestodes

The typical life cycle of Cestodes is indirect with one intermediate host. With few exceptions, the adult tapeworm is found in the small intestine of the final host, the segments and eggs reaching the exterior in the faeces. When the egg is ingested by the intermediate host, the gastric and intestinal secretions digest the embryophore and activate the onchosphere. Using its hooks, it tears through the mucosa to reach the blood or lymph stream or, in the case of invertebrates, the body cavity. Once in its predilection site, the onchosphere loses its hooks and develops, depending on the species, into one of the larval stages, often known as metacestodes. When the metacestode is ingested by the final host, the scolex attaches to the mucosa the remainder of the structure is digested off, and a chain of proglottids begins to grow from the base of the scolex (Urquhart *et al.*, 1996). Mature tapeworms can be up to 25 cm in length and the continual shedding and regrowing of body segments leads to a continual drain on the nutrient reserves of the bird (Leeson and summer, 2009).

Life cycle of Raillietina species: The gravid proglottids are passed with the faeces and eggs may survive for a considerable time (years) (Urquart *et al.*, 1996). Intenuediate hosts such as ants (Pheidole and Tetramorium), beetles (Calathus, Amara) and others become infected by ingesting individual eggs. The embryo (larva) hatches from the egg in the intestine of the intermediate host. The larva changes into a cysticeroid and remains in the body cavity of the intermediate host until eaten by the final host. Activated by the bile in the final host, the cysticeroid attaches to the mucosa in the small intestine. Development of proglottids starts immediately. The prepatent perici varies between 2 to 3 weeks (Soulsby, 1982).

Life cycle of *D. proglottina*: The gravid proglottids are passed out with the faeces. The eggs hatch after being swallowed by various species of gastropod molluscs such as Limax, Cepaea, Agriolimax and Arion. Cysticeroids develop after 3 weeks and develop into adult tapeworms in 2 weeks upon ingestion by the final hosts (Ruff, 1991).

Life cycle of *Choanotaenia infundibulum*: After the eggs have been deposited with the faeces, they hatch in the gut of the intermediate hosts following ingestion. The intermediate hosts are among others beetles of the genera Tribolium, Geotrupes, Aphodius or Calathus and the house fly, Musca domestica. After development in the intermediate host the cysticeroids are infective for the final host. After ingestion of an intermediate host gravid segments are released with the faeces of the host within 2 weeks (Soulsby, 1982; Urquart *et al.*, 1996).

### 2.3.3. Eimeria species

The life cycle of *Eimeria* starts with the ingestion of mature oocysts. Each infective oocyst is formed by four sporocysts and in turn each sporocyst contains two sporozoites. Bile salts and chymotrypsin stimulate the release of the sporozoites from the oocyst. Once freed, the sporozoites invade intestinal cells beginning the asexual development stage called schizogony. After a variable number of asexual cycles, gametes are formed and the sexual stage of development begins (gamogony). The sexual phase terminates with the production and release of oocysts into the intestinal lumen. Once in the environment, oocysts must sporulate to become infective. Sporulation process usually takes from 2 to 3 days depending on environmental conditions (Waldenstedt *et al.*, 2001).

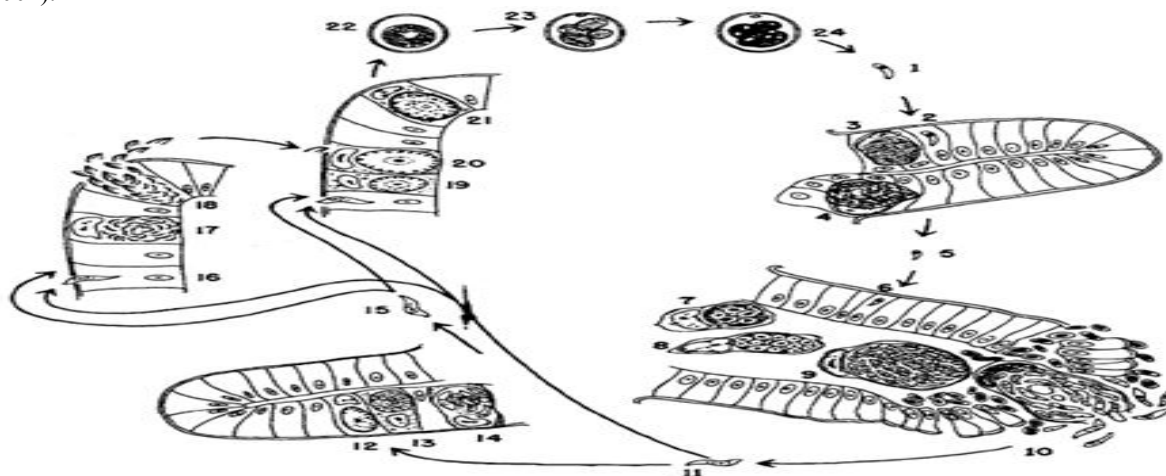


Figure 6: The life cycle of a typical *Eimeria* species.

A sporozoite (1) enters an intestinal epithelial cell (2), rounds up, grows and become a 1<sup>st</sup> generation schizont (3). This produces a large number of 1<sup>st</sup> generation merozoites (4), which break out of the host cell (5), enter new intestinal epithelial cells (6), round up, grow and become 2<sup>nd</sup> generation schizonts (7, 8). These produce a large number of 2<sup>nd</sup> generation merozoites (9, 10), which break out of the host cell (11). Some enter new host intestinal epithelial cells and round up to become 3<sup>rd</sup> generation schizonts (12, 13), which produce 3<sup>rd</sup> generation merozoites (14). The 3<sup>rd</sup> generation merozoites (15) and the great majority of 2<sup>nd</sup> generation merozoites (11) enter new host intestinal epithelial cells. Some become microgamatocytes (16, 17), which produce a large number of microgametes (18). Others turn into macrogametes (19, 20). The macrogametes are fertilized by the microgametes and become zygotes (21). The zygotes mature and become young oocysts, these break out of the host cell and pass out with the faeces (22). The oocysts begin to sporulate (23, 24). When the sporulated oocyst is ingested by a chicken, the sporozoites are released (1) (Permin and Hansen, 1998).

## 2.4. Pathogenicity and Clinical Signs of Nematodes, Cestodes, and Eimeria Species

### 2.4.1. Nematodes

*Ascaridia galli* infects fowl of all ages, but the greatest degree of damage is often found in young birds under 12 weeks of age. Heavy infection is the major cause of weight depression and reduced egg production in poultry husbandry. In severe infections, intestinal blockage can occur. It results in Unthriftiness, drooping of the wings, bleaching of the head and emaciation. It also causes loss of blood, reduced blood sugar content, increased urates, shrunken thymus glands, retarded growth and greatly increased mortality. In heavy infections, adult worms may move up the oviduct and be found in hens' eggs, and sometimes they are also found in the birds' feces (Jacobs *et al.*, 2003). Extensive *A. galli* infection may reduce egg production in floor housed breeders and commercial layers. Death may occur due to intestinal obstruction in birds which are immune suppressed or are affected by an intercurrent debilitating condition (Simon and Emeritus, 2005).

The presence of *Heterakis gallinarum* also poses the danger of enhanced transmission of *Histomonas meleagridis* to both susceptible turkeys and other poultry through shedding of the eggs in the environment (Nnadi and George, 2010). Infections with *Capillaria* species can be highly pathogenic for birds kept in deep-litter systems or in free-range systems where big numbers of infective eggs may build up in the litter or in the soil. Light infections with *C. contorta* and *C. annulata* produce inflammation and thickening of the crop and oesophagus. Heavy infections produce marked thickening of the oesophagus and crop wall with catarrhal and croupous inflammation. When infections occur in the small intestine or in the caeca (*C. caudinflata*, *C. bursata*, *C. obsignata* or *C. anatis*) the animals become emaciated, weak and anaemic. Bloody diarrhoea with haemorrhagic enteritis is seen in heavy infections. *C. obsignata* infections are very pathogenic in pigeons and may cause high mortality rates. Clinical signs due to *Subulura brumpti* are rarely seen, but the worm is important as a differential diagnosis to *Heterakis* spp. (Permin and Hansen, 1998)

### 2.4.2. Cestodes

More than 1400 tapeworm species have been described in domesticated poultry and wild birds. The pathogenicity of the majority of these tapeworms is unknown. A great number are harmless or have a mild pathogenicity. Few species cause severe reactions in the host (Permin and Hansen, 1998).

Chronic infections due to Raillietina species are characterized by reduced growth, emaciation and weakness. Of the three species *R. echinobothrida* is the most pathogenic. Nodules and hyperplastic enteritis may develop at the site of attachment. This phenomenon is named "Nodular tapeworm disease" and may occur in heavy infections. Cestodiasis results in emaciation in mature flocks, especially if severe infestation is exacerbated by malnutrition or immunosuppression (Simon and Emeritus, 2005). *Davainea proglottina*, is the most pathogenic of the poultry Cestodes, the doubly armed scolex penetrating deeply between the duodenal villi. Heavy infections may cause haemorrhagic enteritis, and light infections retarded growth and weakness (Urquhart *e. al.*, 1996). *D. proglottina* is, despite of the small size, one of the more pathogenic species, especially in young birds and particularly if it occurs in large numbers. Clinical signs include dull plumage, slow movements, reduced weight gain, emaciation, dyspnea (difficulties in breathing), leg paralysis and death. Microscopically thickened mucosal membrane with haemorrhages, fetid mucus and necrosis are seen. The presence of the Cestode, *Davainea proglottina* is noteworthy because of its association with haemorrhagic enteritis which could complicate anaemia of ectoparasite origin (Nnadi and George, 2010). The adult *Choanotaenia infundibulum* tapeworms are moderately pathogenic causing weight loss.

### 2.4.3. Eimeria species

The histopathological examination of caecal scrapings of farm birds infected with *Eimeria* oocysts revealed necrosis of villous epithelium, massive haemorrhages and infiltration of inflammatory cells in the lamina propria and submucosa (Puttalakshamma *et al.*, 2008). Coccidiosis is generally acute in onset and is characterized by depression, ruffled plumage, and diarrhea. Birds infected with *E. tenella* show pallor of the comb and wattles and blood-stained cecal droppings. Severe *Eimeria tenella* infection may show hemorrhagic ceca (Simon and Emeritus, 2005). In poultry, *Eimeria* affect the intestine making it prone to other diseases (necrotic enteritis)

and reducing the ability of this organ to absorb nutrients (Lorenzoni, 2010).

Pathological Lesions which may be attributed to the different *Eimeria* species can be listed as follows: *E. acervulina* and *E. mivati*: 1-2mm areas of hemorrhage interspersed with white foci visible through the serosa of the distal duodenum and proximal jejunum. *E. necatrix*: severe distention of the mid-jejunum with hemorrhages in the mucosa and red-stained fluid in the lumen. *E. maxima*: distention of the mid-jejunum with hemorrhages in the mucosa. *E. tenella*: hemorrhagic typhlitis (inflammation of the cecum). *E. brunetti*: hemorrhages of the mucosa of the distal jejunum and colon. Fibrinonecrotic enteritis may occur in chronic cases (Simon and Emeritus, 2005).

## 2.5. General Epidemiology of Nematodes, Cestodes, and Eimeria Species

### 2.5.1. Nematodes

In Ascaridae, adult birds are symptomless carriers, and the reservoir of infection is on the ground, either as free eggs or in earthworm transport hosts (Urquhart *et al.*, 1996). Few epidemiological studies have been carried out to investigate the infection and transmission of *A. galli*. It is generally accepted that the establishment of worms in the intestine is influenced by many factors such as the age of the chicken, the size of the infective dose, the age of the infective eggs, the sex of the chickens, and the diet of the host (Permin and Hansen, 1998).

*Heterakis gallinarum* is widespread in most poultry flocks and is of little pathogenic significance in itself, but is of great importance in the epidemiology of *Histomonas meleagridis* (Urquhart *et al.*, 1996).

### 2.5.2. Cestodes

Poultry reared under free range conditions are likely to be infected with cestodes (tapeworms). All tapeworms of poultry have indirect life cycles with intermediate hosts such as earthworms, beetles, flies, ants or grasshoppers. The intermediate hosts are essential to perpetuate the life cycle and infections are therefore rare in indoor systems. *Davainea proglottina* that is found worldwide is quite common in traditional and free-ranging poultry (Permin and Hansen, 1998).

### 2.5.3. Eimeria species

Modern poultry production practices including rearing animals in high densities facilitate the distribution of this disease within poultry houses. Between poultry houses, the disease is transmitted by mechanical carriers like insects (black beetle) and wild birds. While *Eimeria* eggs (oocysts) can be mechanically transported by wild birds, these parasites are host specific and thus wild birds do not serve as a biological reservoir (Lorenzoni, 2010). The sporulated oocyst is the infective stage of the life-cycle. Infected, recovered chickens shed oocysts representing a problem in multi-age operations. Oocysts can be transmitted mechanically on the clothing and footwear of personnel, contaminated equipment, or in some cases, by wind spreading poultry-house dust and litter over short distances. Factors contributing to outbreaks of clinical coccidiosis include:- litter moisture content exceeding 30% due to ingress of rain or leaking waterers; immunosuppression; Suboptimal inclusion of anticoccidials or incomplete distribution (poor mixing) in feed; and environmental and managerial stresses such as overstocking, inoperative feeding systems, inadequate ventilation (Simon and Emeritus, 2005). The key factors in the epidemiology of coccidiosis can be summarized as: (1) oocysts persist in the environment; (2) there is no maternally derived protective immunity in chickens; (3) the parasite has a shorter prepatent period and a high biotic potential; (4) disease is the function of oocyst dose and species; and (5) immunity is acquired by infection and maintained by continual reinfection (Jordan and Pattison, 1998).

## 2.6. Diagnoses of Nematodes, Cestodes, and Eimeria Species

### 2.6.1. Nematodes

In infections with adult Ascaridia worms, the eggs will be found in faeces, but since it is difficult to distinguish these from *Heterakis* eggs, confirmation must be made by post-mortem examination of a casualty when the large white worms will be found. In the prepatent period, larvae will be found in the intestinal contents and in scrapings of the mucosa. *H. gallinarum* infection is usually only diagnosed accidentally, by the finding of eggs in faeces or the presence of worm at necropsy. *H. isolonche* infection is diagnosed at necropsy by the finding of caecal nodules containing adult worms, and if necessary, confirmed microscopically by examination of the spicules (Urquhart *et al.*, 1996). Parasitism can be diagnosed by examination of mucosal scrapings and fecal flotation, which reveal characteristic bi-operculated ova (Simon and Emeritus, 2005). When viewed under the microscope, Nematodes have transverse grooves running across the body, but unlike the tapeworms they do not physically segment and so only the complete worms are found in the intestine or feces. Female worms produce eggs which are deposited in the feces (Leeson and Summer, 2009).

### 2.6.2. Cestodes

Numerous Cestode species may occur in the intestinal tract and can be diagnosed at postmortem or by examination of feces (Simon and Emeritus, 2005).

### 2.6.3. Eimeria species

Diagnosis is best based on postmortem examination of a few affected birds. Oocysts are detected on faecal



examination. At necropsy, the location and type of lesions present provide a good guide to the species which can be confirmed by examination of the oocysts in the faeces and the schizonts and oocysts present in scrapings of the gut (Urquhart *et al.*, 1996). Gross lesions of *E. tenella*, *E. necatrix* and *E. brunetti* are diagnostic. Microscopic examination of intestinal and cecal scrapings reveals oocysts. To confirm a diagnosis in a commercial operation, the following specimens should be submitted to a laboratory: Intestine from a sacrificed, affected bird preserved in 5% potassium dichromate for culture and identification of *Eimeria* species; intestine showing gross lesions in 10% formalin for histological examination; representative feed samples for anticoccidial assay; and litter samples for oocyst counts. Careful examination of intestinal tracts from at least 5 clinically normal sacrificed birds per flock is necessary to monitor for coccidiosis (Simon and Emeritus, 2005).

## 2.7. Treatment, Prevention, and Control of Nematodes, Cestodes, and Eimeria Species

For the treatment of *Ascaridia galli*, Piperazine is the drug of choice. Continuous medication in feed with hygromycin B is also widely employed. Piperazine may be administered to chickens in the feed (0.2-0.4%) or water (0.1-0.2%), or as a single treatment (50–100 mg/bird). However, piperazine is quite ineffective for young chickens, while tetramisole is 89-100% effective for chicken of different ages. More recent drugs such as albendazole and levamisole are also highly effective (Sharma *et al.*, 1989). Fenbendazole is also very effective, 99.2-100% and 69.0-89.6% effective at administration doses of 60.6 ppm and 30.3 ppm (Sander and Schwartz, 1994). Ivermectin was also demonstrated to be 90 and 95% effective against immature and adult worms, respectively (Sharma *et al.*, 1990).

Treatment for Nematodes can be done with Piperazine, Fenbendazole in feed or Levamisole or Ivermectin (where permitted) in drinking water (Simon and Emeritus, 2005). When birds are reared on a free-range system, and Ascariidiosis is a problem; the young birds should, if possible, be segregated and reared on ground previously unused by poultry. Since the Nematode may also be a problem in deep litter houses; feeding, and watering systems which will limit the contamination of food and water by faeces should be used. In either case treatment with Piperazine salts, Levamisole or a Benzimidazole such as Flubendazole, can be administered either in the drinking water or the feed (Urquhart *et al.*, 1996). The traditional worming compounds, used in the feed or water, have been Piperazine and Hygromycin. Hygromycin is usually used at around 750g/tonne feed, while Piperazine use is at 2-3kg/tonne feed. Birds can also be treated individually if desired, with about 100mg Piperazine. The traditional wormers are narcotics that paralyze, but do not kill the worm. The worms lose their attachment, and are passed out with the faeces. At this stage, the eggs can still be infective, and so effective treatment must involve 2 or 3 dosages of the wormer, each some 7-10 days apart (Leeson and Summer, 2009).

Control over infection simply relies upon breaking the reproductive cycle of the tapeworm, by eradicating the intermediary hosts. Slug and snail bait, usually containing metaldehyde, must therefore be applied around the perimeter of the house. Chemical treatment of infected birds is possible, but a number of these require 24 hours prior starvation of the bird, and so this naturally disrupts egg production in mature birds. Products such as Praziquantel are effective against tapeworms, while most of the common chemical treatments used for roundworms are ineffective (Leeson and summer, 2009). Niclosamide in feed was recommended as treatment option (Simon and Emeritus, 2005). Control of *Davainea* and *Raillietina* depends on the treatment of infected birds with a suitable anthelmintic such as niclosamide and butynorate and the destruction of slugs and snails when possible (Urquhart *et al.*, 1996).

Sulphonamide drugs are the most widely used and it is recommended that these are given for two periods of three days in the drinking water, with an interval of two days between treatments. Sulphaquinoxaline, sometimes potentiated with diaveridine, or sulphadimidine are the drugs of choice. Where resistance has occurred to sulphonamides, mixtures of Amprolium and Ethopabate have given good results (Urquhart *et al.*, 1996). Administration of Amprolium solution, 0.024% of the active ingredient in drinking water for 3 - 5 days. Sulfonamides (sulfamethazines), 0.1% for 2 days, 0.05% for 4 days or commercial combinations of sulfa drugs) in drinking water. Administration of water dispersable vitamin A and K supplements may enhance recovery (Simon and Emeritus, 2005).

Prevention of avian coccidiosis is based on a combination of good management and the use of anticoccidial compounds in the feed or water. Thus, litter should always be kept dry and special attention given to litter near water fonts or feeding troughs (Urquhart *et al.*, 1996). Management procedures which limit saturation of litter include: appropriate installation and management of watering systems e.g. Nipple drinkers reduce spillage of water onto litter compared to bell and trough drinkers; acceptable ventilation rate; maintaining recommended stocking density; providing adequate feeding space; inclusion of anticoccidials in diets at recommended levels will prevent clinical infection; chemical and ionophoric anticoccidials for broilers in shuttle programs; synthetic coccidiostats for breeders and floor-reared commercial egg production flocks which allow the development of premunity. Anticoccidial vaccines are appropriate for replacement breeding stock and roasters (Simon and Emeritus, 2005).

### 3. CONCLUSION AND RECOMMENDATIONS

Gastrointestinal parasites are known to cause subclinical infections in chickens and to lead to invisible production and economic losses. It is obvious that, gastrointestinal parasites can make the flock less resistant to diseases and exacerbate existing disease conditions. Helminth infections are common among village chickens. Poultry coccidiosis that generates economic losses is probably the most common disease in modern poultry production, where confinement rearing is practiced. However, parasitic infestations are usually conjoint. The concurrent infestations with two or more parasites, especially those with gastrointestinal predilection, may heighten their role in early chick mortality and other productivity losses among the adults. This is particularly true of conjoint infestations with helminthes and coccidia whose combined effects on host could be devastating. Based on the review, the following recommendations are forwarded:

- Since most of the gastrointestinal parasites have a subclinical occurrence, studies in focus of these ideas should be conducted.
- The public should be aware about occurrence and economic significance of gastrointestinal parasites.
- Better if experimental studies be conducted on the conjoint prevalence and economical effect gastrointestinal helminthes and *Eimeria* species affecting chickens.

### 4. REFERENCES

- Amare, A., Netsanet, W., and Negussie, H. (2012). Coccidiosis Prevailing in Parent Stocks: A Comparative Study Between Growers and Adult Layers in Kombolcha Poultry Breeding and Multiplication Center, Ethiopia. *Global Veterinaria*, 8: (3), 285-291.
- Anderson, R.C. (2000). Nematode Parasites of Vertebrates. Their Development and transmission, 2<sup>nd</sup> edition; CAB International, Wallingford, Oxon, UK; PP, 290-299.
- Ashour, A. A. (1994). "Scanning electron microscopy of *Ascaridia galli* (Schrank, 1788), Freeborn, 1923 and *A. columbae* (Linstow, 1903)". *J.E.S. Parasitology*, 24: 2, 349-55.
- Baker, D. G. (2008). Parasites of Lab. Animals; 2<sup>nd</sup> ed<sup>n</sup>; Blackwell Publishers; Pp. 236-237.
- Cheng, T. C. (1986). General Parasitology; 2<sup>nd</sup> edition. Academic Press, Division of Hardcourt Brace & Company, USA; Pp. 402-416.
- CSA (2012). Agricultural Sample Survey 2011/12 [2004 E.C.]: Report on Livestock and Livestock Characteristics; Volume II, *Statistical Bulletin* 532, Addis Ababa, Ethiopia.
- Dalloul, R.A., Lillehoj, H.S. (2006). Poultry coccidiosis: recent advancements in control measures and vaccine development. *Expert Rev Vaccines*, 5: 1, 143-163.
- Gary, D.B., and Richard, D.M. (2012). Intestinal Parasites in Backyard Chicken Flocks: Cooperative Extension Service, Institute of Food and Agricultural Sciences, University of Florida, Gainesville, 32611: VM76.
- Griffiths, H.J. (1978). A Handbook of Veterinary Parasitology: Domestic Animals of North America. University of Minnesota Press, Minneapolis, Minnesota, USA, Pp. 46-47.
- Hall, H.T.B. (1985). The Nematode Parasites of Poultry: Diseases and Parasites in Livestock in the Tropics, 2<sup>nd</sup> Edition. London Scientific and Technical, Longan Group, UK. Pp, 237-261.
- Hambridge, G. (2011). Diseases and Parasites of Poultry. Daya Publishing House; Pp. 148-149.
- Hunduma, D., Regassa, C., Fufa, D., Endale, B., and Samson, L. (2010). Major Constraints and Health Management of Village Poultry Production in Rift Valley of Oromia, Ethiopia. IDOSI Publications. *American-Eurasian Journal Agriculture and Environmental Science*, 9: 5, 529-533.
- Jacobs, R.D., Hogsette, J.A., Butcher, J.D. (2003). Nematode parasites of poultry (and where to find them). The Institute of Food and Agricultural Sciences (IFAS) series PS18, University of Florida, USA, pp. 1-3.
- Jordan, F.T., W., and Pattison, M. (1996). Parasitic Diseases: Poultry Diseases; 4<sup>th</sup> Edition; W.B. Saunders Company Ltd. Printed in Great Britain by the University Press, Cambridge; Pp: 261.289.
- Kassa, B. (2005). Standard Veterinary Laboratory Diagnostic Manual: Ethiopian Agricultural Research Organization National Animal Health Research Center; Volume III: Parasitology.
- Katoch, R., Anish, Yadav, R., Godara, J.K., Khajuria, S., Borkataki, S., Sodhi, S. (2012). Prevalence and impact of gastrointestinal helminthes on body weight gain in backyard chickens in subtropical and humid zone of Jammu, India. *J Parasit Dis*, 36: 1, 49-52.
- Kaufmann, H. (1996). Parasitic Infections of Domestic Animals: A Diagnostic Manual. Birkhäuser Verlag, Basel; Pp. 353-354.
- Lalchandama, K. (2009). "On the structure of *Raillietina echinobothrida*, the tapeworm of domestic fowl". *Science Vision*, 9: 4, 174-182.
- Lalchandama, K. (2010). "On the structure of *Ascaridia galli*, the roundworm of domestic fowl". *Science Vision*, 10: 1, 20-30.
- Lalchandama, K., Bishnupada, R., Biman K.D. (2009). "Anthelmintic activity of *Acacia oxyphylla* stem bark against *Ascaridia galli*". *Pharmaceutical Biology*, 47: 7, 578-583.
- Leeson, S., and Summer J.D. (2009). Internal Parasites: Broiler Breeder Production; 1<sup>st</sup> edition by Nottingham

- University Press in 2000, University Books, Guelph, Ontario, Canada; Pp. 104-106.
- Lorenzoni, G. (2010). Poultry Diseases Influenced by Gastrointestinal Health, Traditional Treatments and Innovative Solutions. First published 2010, Nottingham University
- Martynova-VanKley, A., Syvyk, A., Teplova, I., Hume, M., and Nalian, A. (2008). Rapid Detection of Avian *Eimeria* Species Using Denaturing Gradient Gel Electrophoresis; *Poultry Science*, 87: 1707–1713.
- McDougald, L. R. (2011). "Cestodes and trematodes". In YM Saif, AM Fadly, JR Glisson, LR McDougald, LK Nolan, DE Swayne. Diseases of Poultry; 12<sup>th</sup> edition, Iowa (US):
- Nnadi, P.A., and George, S.O. (2010). A Cross-Sectional Survey on Parasites of Chickens in Selected Villages in the Sub humid Zones of South-Eastern Nigeria; *Journal of Parasitology Research*, 14: 6, 18-24.
- Ohaeri, C.C., and Okwum, C. (2013). Helminth Parasites of Domestic Fowls in Ikwuano, Abia State Nigeria; *Journal of Natural Sciences Research*, 3: 11; (ISSN 2224-3186 (2225-0921)).
- Permin, A., and Hansen, J.W. (1998). Diagnostic Methods: Epidemiology, Diagnosis and Control of Poultry Parasites. FAO animal health manual, No 4. Food and Agriculture Organization of the United Nations, Rome, Italy; Pp. 33-118.
- Puttalakshamma, G.C., Ananda, K.J., Prathiush, P.R., Mamatha, G.S., and Suguna, R. (2008). Prevalence of Gastrointestinal parasites of Poultry in and around Bangalore; India. *Veterinary World*: 1: 7, 201-202.
- Radha, T., Satyaprema, V.A., Ramalingam, K., Indumathi, S.P., and Venkatesh, C. (2006). "Ultrastructure of polymorphic microtriches in the tegument of Raillietina echinobothrida that infects Gallus domesticus (fowl)". *Journal of Parasitic Diseases*, 30: 2, 153–162.
- Ramadan, H.H., Znada, N.Y.A. (1992). "Morphology and life history of Ascaridia galli in the domestic fowl that are raised in Jeddah". *J.K.A.U. Sci.*, 4: 87–99.
- Ruff, M.D., Calneck, B.W., Barnes, H.I., Beard, C.W., Reid, W.M., Yonder, Jr.H.W. (1991). Nematodes and Acanthocephalans: Diseases of Poultry; 3<sup>rd</sup> edition, Ames, Iowa State University Press; Pp. 731-763.
- Saif, M., Fadly, M., Glisson, R., McDougald, R., Nolan, K., and Swayne, E. (2008): Diseases of poultry; 12<sup>th</sup> edition, Blackwell Publishing Professional 2121 State Avenue, Ames, Iowa 50014, USA, Pp. 1067-1080.
- Sharma, R.L., Bhat, T.K., Hemaprasanth (1990). "Anthelmintic activity of ivermectin against experimental *Ascaridia galli* infection in chickens". *Veterinary Parasitology*, 37: 3–4, 307–314.
- Simon, M.S., and Emeritus (2005). Enteric Diseases: ASA Handbook on Poultry Diseases, 2<sup>nd</sup> edition, American Soybean Association; Pp. 133-143.
- Soulsby, E.J.L. (1982). Helminthes, Arthropods, and Protozoa of Domestic Animals, 7<sup>th</sup> edition, Bailliere, and Tindall, London; Pp. 83-115.
- Urquhart, G.M., Armour J., Duncan J.L., Dunn A.M., and Jennings F.W. (1996). Veterinary Parasitology; 2<sup>nd</sup> edition, Blackwell Science; Pp. 261-264.
- Waldenstedt, L., Elwinger K., Lunden A., Thebo P., and Ugglå A. (2001). Sporulation of *Eimeria maxima* oocysts in litter with different moisture content. *Poult. Sci.* 80:1412-1415.
- Williams, R.B. (1999). A Compartmentalized Model for The Estimation of the Cost of Coccidiosis in the World's Chicken Production Industry. *International Journal of Parasitology*, 29:1209-1229.
- Ziela, M. (1999). A Comparative Study of Gastrointestinal Nematode Infections in Traditional and Commercial Chickens and Effects of Anthelmintic Treatment on Production. *International Journal of Poultry Science*, 7: 12, 67-73.