

Histomorphology and Biochemical Effects of *Sida acuta* leaf

Extract on the Kidney of Wistar Rats

Kebe. E. Obeten, Amabe O. Akpantah, Kelechi C. Uruakpa, Eru. M. Eru, Gabriel Udoaffah
Department of Anatomy, University of Calabar, Calabar, Nigeria
Kebe Obeten (Corresponding author)
+2348035505856 Email: fredobeten@yahoo.com

Abstract

This study assessed the effect of ethanolic extract of *Sida acuta* leaf on the micro-anatomy of the kidney of Wistar rats. Thirty adult Wistar rats were separated into 3 groups A, B and C (n=10 per group). The Wistar rats were subjected to different doses of ethanolic extract of *Sida acuta* in order to evaluate the possible micro-anatomy/morphological changes in the kidney following the administration of the extract. The rats in group A were regarded as control and they received only distilled water throughout the period. The rats in group B and C were the treated groups and received ethanolic extract of *Sida acuta* leaves daily at doses 100 and 200mg/kgbw orally for 14 days respectively. The animals were sacrificed on the 15th day by cervical dislocation and the kidney excised. Fixed in 10% formal saline and processed for light microscopy using H&E staining methods. Finding from rats' weight that there was a significant ($P<0.05$) decrease in body weight of the treated rats compared with the control group. The histological study revealed compressed renal corpuscle, increased bowman's space and constricted collecting tubule which may adversely affect renal functions.

Key words: *Sida acuta*, Kidney, histomorphology, biochemical

Introduction

Higher plants as sources of medicinal compounds continue to play a dominant role in the maintenance of human health since antiquities. Over 50% of all modern clinic drugs are of natural plant product origin. Natural plant products play an important role in development programme of the pharmaceutical industry.¹ Investigations into the medical and biological activities of plants during the past two centuries have yielded compounds for the development of modern synthetic organic chemistry as a major route for the discovery of new and more effective therapeutic agents.² A vast knowledge of how to use plants against different illnesses may be expected to have accumulated in areas where the use of plants is still of great importance.³ Among the plants used in traditional medicine is *Sida acuta* a shrub indigenous to pan tropical areas. The aerial part of the plant is the most frequently used part to treat asthma, renal inflammation, colds, fever, ulcers and norms in Central America.^{4,5} In Nigeria, it has wide application in folk medicine some herbalist have claimed the traditional use of this plant to cure infections such as gonorrhoea, breast cancer and to procure abortion.^{6,7} Among the compounds isolated from *Sida acuta*, its alkaloids appeared to be of great interest in pharmacological studies. Cryptolepine 5-methylindolo-quinoline, the main alkaloid of the plant has been well investigated for various biological properties.^{8,9} Cryptolepine presents a larger spectrum of biological properties which includes hypotension and anti-inflammatory effects.¹⁰ This alkaloid is known to exhibit various pharmacological activities like anti trypanosomal and antifungal effect.^{11,12} The kidney is a paired retroperitoneal organ on the posterior abdominal wall that helps to secrete waste products of protein metabolism from the blood while returning nutrient and chemical to blood.¹³ The kidney is a chief regulator of all the body fluid and is primarily responsible for maintaining homeostasis or equilibrium of fluid and electrolytes of the body. The kidney main function is urine formation, regulation of acid-base balance, excretion of waste products of metabolism and toxic substances, protein conservation, secretory functions and recovery of useful metabolites which filters through.¹⁴ In view of the usage of this extract in the treat of various ailments, this paper reported the possible effect of this extract on the kidney morphology in Wistar rats.

Materials and methods

Thirty healthy Wistar rats with an average weight of 140g were procured from the animal house of the Department of Pharmacology, University of Calabar, Calabar, Nigeria. The rats were kept and maintained under standard laboratory conditions of temperature, humidity and light for a period of two weeks in the animal holdings of the Department of Human Anatomy, University of Calabar, Calabar, before the commencement of the experiments. During this course, the rats freely fed on pellets from Ettems' feed holdings, Calabar and were

given distilled water ad libitum.

Experimental design and groupings

In this study, a total of 30 adult Wistar rats were used. They were randomly separated into 3 groups of 10 rats each. Group B and C served as the experimental groups and received ethanolic extract of *Sida acuta* at varying doses. Group A served as the control group and received the same quantity of distilled water as contained in the experimental doses.

Administration of the ethanolic extract of *Sida acuta* was done orally by means of an oral canula. Group B and C received 100 and 200mg/kg body weight for three weeks. Rats in the control group (Group A) received quantity of distilled water as contained in the experimental doses.

At the end of the study, the rats were sacrificed by cervical dislocation. The abdomen of each rat was carefully dissected, the kidney removed and fixed in 10% formal saline for histological studies following the method of Carleton (1967).

Result

The kidney section from group A control rats showed a normal renal corpuscle. The bowman capsule and the glomeruli appeared to be prominent and normal (Figure 1)

The kidney section from group B treated animals showed a slightly increase in the luminal spaces of the renal tubules, Bowman's capsule, glomeruli, collecting duct, proximal convoluted tubule. The morphological features appeared to be slightly distorted with reduced Bowman's space (figure 2). The section from group C treated rats also reveals increased luminal space of the renal tubules, bowman's capsule, collecting duct, proximal convoluted tubules and distortion of the renal architecture and loss of some cellular components of this treated section (Figure 3)

Discussion

The use of plant as source of remedies for the treatment of many diseases dated back to prehistory and people of all continents have this old tradition. Despite the remarkable progress in synthetic organic chemistry of the twentieth century, over 25% of prescribed medicines in industrialized countries are derived directly or indirectly from plants.¹⁵ *Sida acuta* a shrub of the malvaceae family has been widely used as traditional medicine for the treatment of various ailments.⁵ Phytochemical evaluation of this plant has shown that it is rich in alkaloid, saponin, tannin and flavonoids.¹⁶

The results of the study shows that the ethanolic leaf extract of *Sida acuta* administered at different doses caused a significant ($P < 0.05$) decrease in the body weight of the treated rats when compared with the control. The increase in the luminal spaces in the treated rats might be an indication that the extract has adversely affected the renal clearance which may consequently lead to diuresis. This is not consistent with the work reported by¹⁷, which stated that *Sida acuta* plants ameliorate nephrototoxicity and renal dysfunction hence validates its ethno medical use.¹⁸, have noted that most waste products are poorly reabsorbed by the renal tubules and the effect of the extract will therefore be important for effective removal of waste products from the kidney. Similarly, the degeneration of the bowman's is indicative that the extract have adverse effect on the cells and tissue of the kidney may consequently impair renal function and may cause severe reduction in glomerular filtration leading to acute diffuse proliferative glomerulonephritis.¹⁹ This is not also in agreement with previous studies that have reported the presence of biological active compounds in *Sida acuta* that are capable of protecting tissues and cells from toxic effects in particular the alkaloids which have been documented to have many pharmacological properties. This disparity might be due to the differences in the methodology used and also the duration of administration and dosage may have played a vital role.

This study concluded that administration of chronic doses of ethanolic extract of *Sida acuta* to Wistar rats resulted in decreased body weight, decrease bowman space, dilation of renal tubules and cellular degeneration of the treated rats. This is an indication that the extract has adversely affected the kidney morphological features which may consequently impair renal function in the treated rats.

It is recommended from this study that further studies should be carried out particularly on the physiological and biochemical parameters in relation to renal functions with the aim of corroborating the finding from this present morphological study

References

1. Baker, J. T., Borns, P.R., Carta, B., Cordell, G.A., Gupta M.P., Iwu, and Tyler, A.V. (1995). Natural product drug discovery and development. New perspective on international collaboration. *J. Natural products*. 132s-1357.
2. Roja, G and Rao P. S (2000). Anti cancer compound from tissue culture of medicinal plants. *J. Herbs species. Med. plants* 7:71-102.
3. Diallo, D., Hveem, B., Mahmoud, M. A., Berge, G., Paulsen, B. S and Maiga, A. (1999). An ethnobotanical survey of herbal drugs of Gourma district, Mali. *Pharmaceutical Biology*, 37:80-91
4. Caceres A, Ginon LM, Martinez AM (1987) Diuretic activity of plants used for the treatment of urinary ailment in Guatemala. *J. Ethnopharmacol* 19:233-245.
5. Coe F G, Anderson GJ (1996). Ethnobotany in the Garifuna of Eastern Nicaragua. *Econ. Bot.* 50:71-107.
6. Kayode J, (2006). Conservation of indigenous medicinal botanicals in Ekiti State, Nigeria. *J. Zhejiang University Sci B*: 713-718.
7. Edeoga H O, Okwu DE, Mbaebia BO (2005). Phytochemical Constituents of some Nigerian medicinal plants. *Afr. J. Biotechnol*, 4:68-688.
8. Clinquart E (1929). Sur la composition de *Cryptolepis triangularis* plante congolaise. *Bull. Acad. Roy. Med. Belg* 9:627-635
9. Dwuma-Badu D., Ayin JKS, Fiagbe NIY, Knapp J. E., Schiff PL, Slatkin DJJ, 1978. Quinodoline from *cryptolepis sanguinolenta*. *J. Pharm. Sci.* 67:433-635.
10. Bonjean, K, M. C. De pawn –Guillet, Mop-Defrens, P. Colson and C. Houssier *et al*; 1998. The DNA intercalating Alkaloid *cryptolepine* interferes with topoisomerase II and inhibits primary DNA synthesis in B16 melanoma cells. *Biochemistry*. 37.5136-5146.
11. Ablordepey S Y, Fan P, Clark Ani, Nimrod A (1999). Probing the N-5 region of the indoloquinoline alkaloid *cryptolepine* for anticryptococcal activity. *Bioorg med-chem* 7 (2); 343-349.
12. Arzel E, Rocca P, Grellier P, Labeaid M, Frappier F, Grueitte F, Godard A, Queguiner G (2001) New synthesis of Δ^1 -Carbolines, *cryptolepines*, and their salts: in vitro cytotoxicity, antiplasmodial and antitrypanosomal activities of Δ^1 . *Carbolines, benzo (Δ^1)-carbolines and Cryptolepines*, *J med chem* 44:949-960.
13. Moore KL, Dalley AF (2006) *Clinically oriented Anatomy*, 5th Ed 309-318 Lippincott Williams and Wilkins.
14. Williams PI, Bannister IN, Berry MM, Dussex JI (1998). *Gray's Anatomy*, 38th ed. Churchill Livingstone, Harcourt Publisher, 1895-1826, 1753-1762.
15. Newman DJ, Cragg GM, Snadder KM (2000). The influence of natural products upon drug discovery. *Nat. Pro. Rep.* 17:175-285.
16. Jang D S, Park E J, Kang Yh, SU BN, Hawthorne ME, Vigo Crahan JG, Cabieses F, Fong HH, Mehta RG, Pezzuto JM. Kingdom AD (2003). Compounds obtained from *Sida acuta* with the potential to induce quinone reductase and to inhibit 7,12-Dimethyl[a]anthracene-induced preneoplastic lesions in a mouse mammary organ culture model. *Arch-pharmacol. Res.* 26:585-590.
17. Menaka C. Thounaojam, Ravirajsinh N. Jadeja, Umed V. Ramani, Ranjitsinh V. Devkar, and A. V. Ramachandran. *Int. J. Mol. Sci* 2011; 12(7): 4661-4677 published online July 19
18. Brenner BM, Troy JL, Dougherty TM. On the mechanism of inhibition in fluid re-absorption by the renal proximal tubule of the volume expanded rat. *J. Clin Invest* 1971; 50:1596
19. Muri's textbook of pathology (2008) 14th Ed. Edward Arnold publishers Ltd. 847-848.

Figure 1: Section of the kidney (cortex and medulla) control group showing normal renal tubule (RT), Bowman's space (BS), Bowman's capsule (BC), Glomeruli (G), Collecting duct (CD) and proximal convoluted tubules (PT) H&E (x 400).

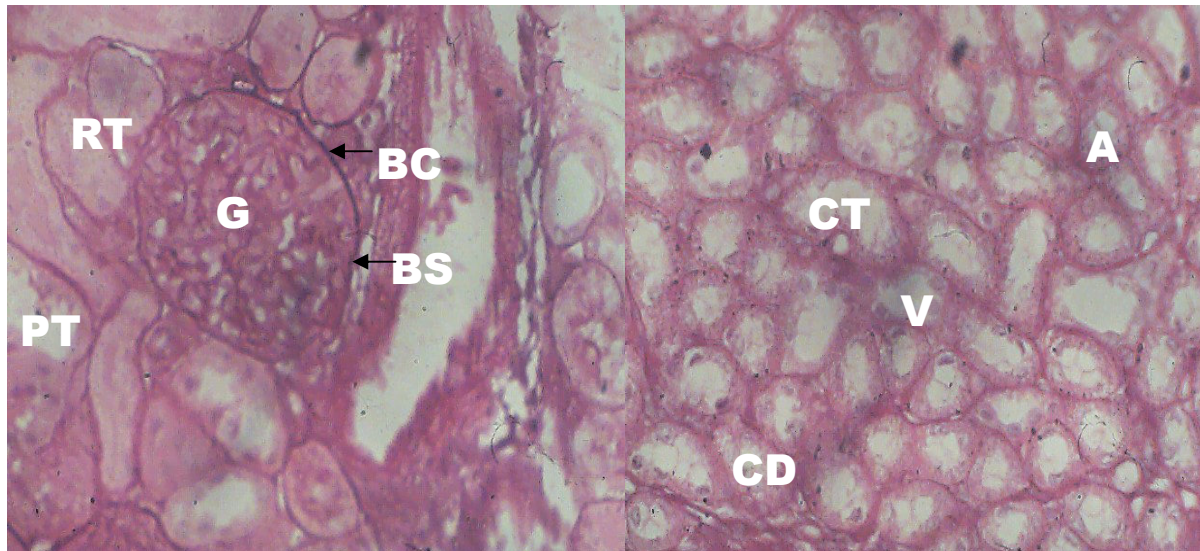


Figure 2: Section of rat kidney (cortex and medulla) treated with 100mg/kgbw of extract showed slight increase in the luminal space of the Renal tubules (RT), Bowman's capsule (BC), Bowman's space (BS), Glomeruli (G), Collecting duct (CD), Collecting tubule (CT), Proximal convoluted tubule (PT), Ascending limbs (A) and Vasa recta (V) H&E (x 400)

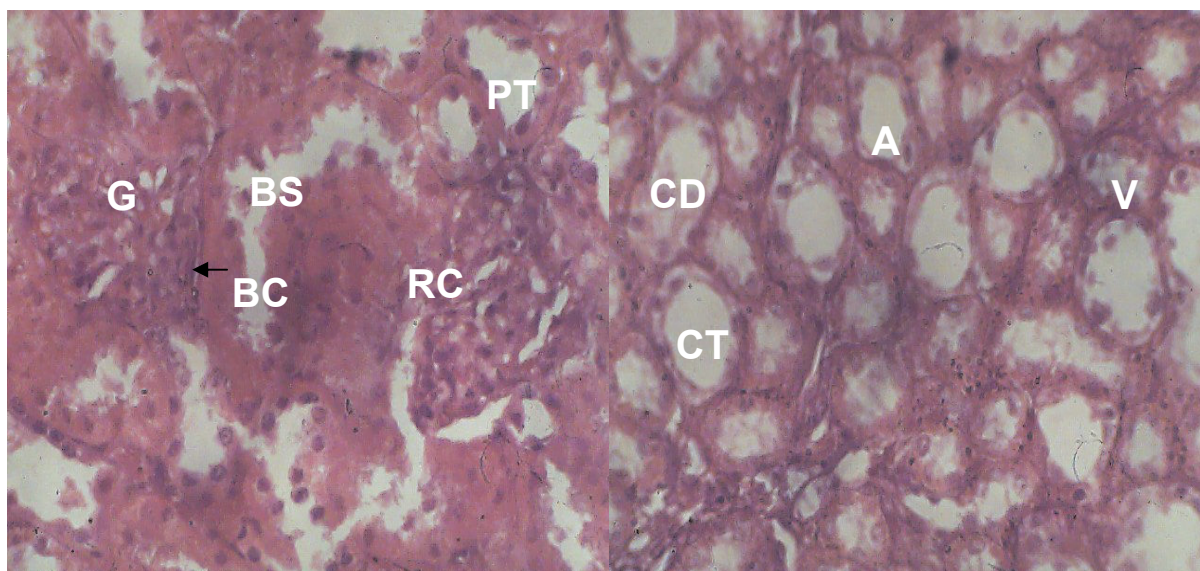


Figure 3: Sections of the rat kidney (cortex and medulla) treated with 200mg/kgbw of extract showed increased Bowman's capsule (BC), Bowman's space (BS), Glomeruli (G), Collecting duct (CD), Proximal convoluted tubule (PT), Ascending limbs (A), Vasa recta (V) and constricted Collecting tubule (CT). H&E (x 400)

