

## Histological Integrity of the Frontal Cortex of Rat Model Treated with Aqueous Extract of Neem Leaf and Oil

ARIYO .I.A<sup>1</sup>, DARE.B.J<sup>2</sup>, OYEWOPO.A.O<sup>1</sup>, HAMMED.A.M<sup>1</sup>

1. Department of Anatomy University of Ilorin, P.M.B 1515, Ilorin, Nigeria

2. Department of Anatomy Bingham University, P.M.B 005, Karu, Nigeria

### Abstract

The study was carried out to investigate some of the effects of Aqueous Extract of Neem leaves and Neem Oil on the histological integrity of the Frontal Lobe of Male Adult Wistar Rats Brain. Thirty Adult Male Wistar Rats were used weighing between 190-200 g. They were randomly divided into three groups. Group A control; received 1ml of Phosphate buffered saline, Group B received 0.6 ml of neem oil and Group C received 300 mg/kg of aqueous extract of neem leaves once daily for 30 days of experimental period. The animals were sacrificed by cervical dislocation. The frontal lobes was excised and fixed in 10 % formal calcium for histological processing using Haematoxylin and Eosin for histo-architectural study and Cresyl violet for Nissl body. The Neurons and Nissl substances in the experimental groups were larger and hyper chromic to H&E and CFV stains while the Nissl bodies in the neurons of the control group were normochromic to H&E and CFV stains. The nissil bodies in the experimental groups stained more than nissil bodies in the control group. Neurons of group B are larger and pyramidal in shape while neurons of group C are stellate while that of control group A are pyramidal. Increase in the size and density of the neurons as shown by the densely stained photomicrograph in the treated rat as compared with the control is an indication of increased cellular activities in the frontal cortex.

**Keywords:** Neem oil, aqueous extract, frontal lobe and Wister rat.

### INTRODUCTION

The neem is an ancient India cure all due to its antibacterial, antifungal, antiviral, antihistamine and antiseptic properties. The Neem leaves, flowers, seeds, roots, bark and fruits are utilized to treat inflammation, infections, skin diseases and for dental cure. (Biswas, et al, 2002) For thousands of years ago, the beneficial properties of neem (*Azadirachta Indica*) have been recognized in the India traditional, each part of the neem tree has same medicinal properties (Biswas et al, 2002). Each part of neem is used in the cultural medicine; it has been used in Ayurvedic Medicines for more than 4000 years (Biswas et al, 2002). Neem oil extracted from its seeds is used in Medicines, pest control and cosmetics etc. its leaves are used in the treatment of chicken pox. According to the Hindus, it is believed that the goddess of the chicken pox, Sithala lives in the neem tree. Neem tea is taken to reduce headache and fever. Its flowers are used to cure intestinal problems (Ganguli, 2002) Neem bark act as an analgesic and can cure high fever as of malaria. Even the skin diseases can be cured from the neem leaves. India believes a lot that the neem can purify all diseases. (Biswas et al, 2002) The frontal lobes are considered as our emotional control center and home to our personality (Kolb and Wishaw, 1990). The frontal lobes are involved in motor function, problem solving, spontaneity, memory, language, initiation, judgment, impulse control and social and sexual behaviour. (Snell, 2006) A person's personality can undergo a significant changes after an injury to the frontal lobes, especially when both are involved. (Sembulimgam and Prema, 2007) Sexual behaviour can also be affected by frontal lesion. Orbital frontal damage can introduce abnormal sexual behaviour, while dosolateral lesions may reduce sexual interest. (Sembulimgam and Prema, 2007) This study is conducted to investigate the effect of aqueous extract of neem and its oil on the cytological integrity of the frontal cortex of adult male Wister rat.

### MATERIALS AND METHODS

#### LEAF EXTRACT

Fresh leaves of *Azadirachta Indica* (neem) were collected from the Anatomy Department, University of Ilorin Mini Campus, Kwara State. The leaves were air dried at room temperature, 2 kg of air dried leaves was blended into fine powder in a blender. The fine powder of 200 g was dissolved in 1.5 litres of distilled water and left at room temperature for 24 hours for proper soaking, after which it was filtered. The residue was discarded and the filtrate was evaporated at 70 °C in the ovum. The residue gotten from evaporation of filtrate weighing 24 g was use for dosage preparation.

#### NEEM OIL

The neem oil was obtained from the National Agricultural Research Institute, Zaria, Kaduna

#### ANIMAL MATERIALS

Thirty adult male rats, were used weighing between 190 -200 g These rats were reared in the Animal house of

Anatomy Department, University of Ilorin, under normal room temperature, light and humidity. They were fed with Rat pellets from Beendel feed and water was given ad libitum.

### ADMINISTRATION

Group A served as control experiment and was administered phosphate buffered saline (1 ml), Group B was administered 0.6 ml of neem oil, While group C was administered 300 mg/kg per day oro-gastrically for 30 days of experimental period.

### HISTOLOGICAL ANALYSIS

Frontal cortex were carefully excised following fracture of the skull, fixed in 10% formol calcium and processed routinely for paraffin embedding. 5 $\mu$  sections were obtained with rotator y microtome and processed for Heamatoxylin and Eosin Stain (H & E) and cresyl violet. Sections were observed with light microscope and photomicrograph was taken for further analysis.

### RESULT

#### NEUROHISTOLOGICAL ANALYSIS

The following histological observations were made from the micrographs:

1. For the Heamatoxylin and Eosin stain, there are more neurons in the experimental groups when compared with the control group.
2. The neurons in the experimental groups are more stained than the control group.
3. The neurons in the experimental groups are more larger than the neurons in the control group.
4. The neurones in group B are bigger than the control group and they are pyramidal in shape, while neurons of the group C are smaller than the control and stellate in shape. The neurons of the control group are pyramidal in shape.
5. The neurons in experimental groups are intensively stained (hyperchromic to cresyl fast violet) than the control group, which is normochromic to cresyl fast violet.  
The nissl bodies are deeply stained in the experimental groups than the nissl bodies of the control group

### DISCUSSION

The present study investigated the cellular integrity of frontal lobe of adult male wistar rats, after treatment with 0.6 ml of neem oil and 300 mg/kg of aqueous extract of neem leaves per day for 30 days of experimental period. There were cytoarchitecture changes between the experimental groups and the control group. The neurons in the experimental groups B and C were hyperchromic than neurons in control group which are normochromic to cresyl fast violet as shown from the micrograph. This is an indication of increased cellular activities of the frontal cortex in the experimental groups as compared with the control. The nissl bodies and nuclei in the experimental groups B and C stained more than nissl bodies and nuclei of the control. The neurons in experimental group B are pyramidal in shapes, those of experimental group C are stellate in shape, while that of the control group A are pyramidal in shape also.

Histological Analysis showed that both Neem oil and aqueous extract of neem leaves changed the cellular architecture of the frontal lobe, while the nuclei and nissl bodies of the experimental groups (B and C) stained intensely than that of the control.

### REFERENCES

- Biswas, Kausik, Ishita, C., Ranaji K.B. and Uday B. (2002). Biological activities and Medical properties of Neem (*Azadirachta Indica*). *Current science* 82 (11) 133 6-1345.
- Beutter, E., Villainy, T., and Luzzatto, L., (1996) Hematologically important Multilations; glucose-6-phosphate dehydrogenase. *Blood cells molecules Dis.* 22(1), 49-76.
- Biswas, Kausik, Ishita, C., Ranaji K.B. and Uday B. (2002). Biological activities and Medical properties of Neem (*Azadirachta Indica*). *Current science* 82 (11) 133 6-1345
- Chopra R.N, Nayer S.L. and Chopra I.C. (1956) *Glossary of Indian Medicinal plants* CSIR, New Delhi. P 15-20.
- Cranner C.T, Cooker, S., Ginsberg, L.C., Kletzien, R.F, stapleton, S.R., child, R. and Rammathan (1936) *J.Soc. chem. Ind.*, 55, 124.
- Ketkar, A. Y. and Ketkar, C.M (1995) *In the Neem Tree: Source of Unique Natural Products for integrated pest Management, Medicine, Industry and other purposes* (ed. Suchmutterer H.) pp 518-525.
- Khan, M. and Wassilew S. W. (1987). *In Natural pesticides from the Neem Tree and other Tropical plants* (eds Schmutterer H and asther K.R.S) GTZ Eschborn Germany pp 645-650.

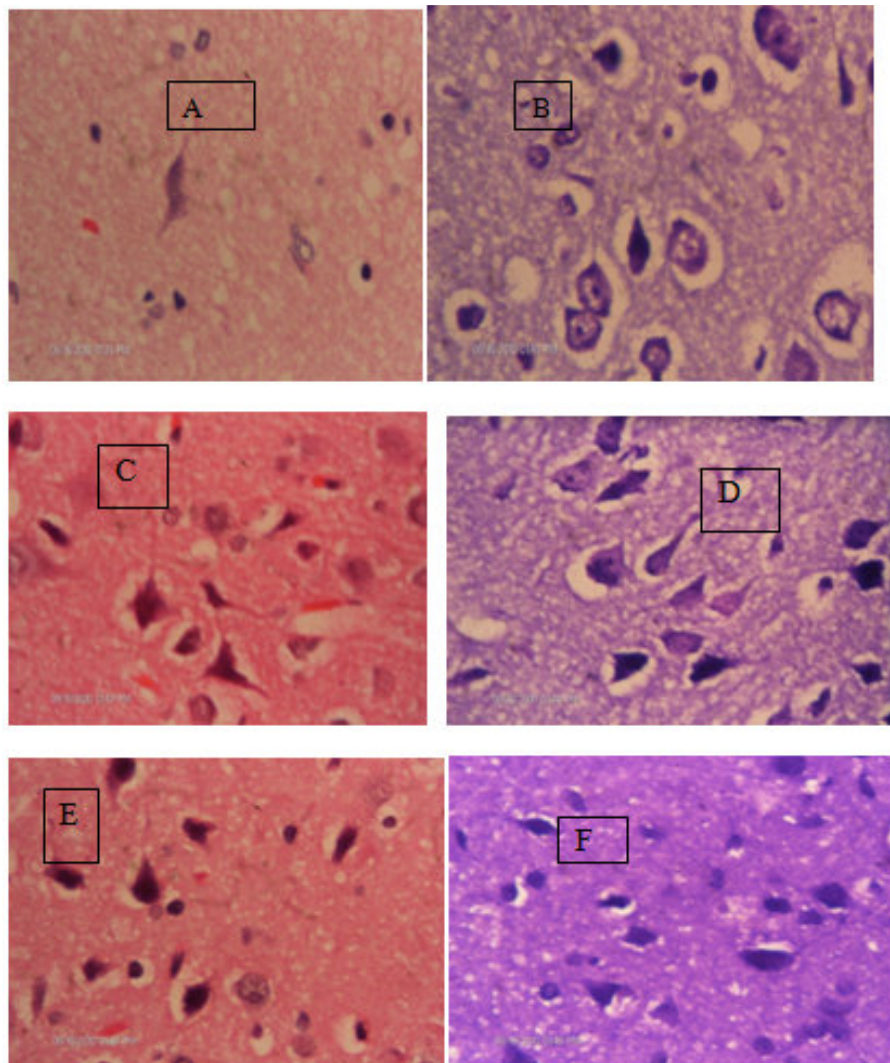


Figure1; Photomicrograph of Frontal Lobes of the Cortex Showing A Nucleus and Nissil Body Control A And B, Neem Etract Cand D Neem Oil E And F Using H/E And Crv

This academic article was published by The International Institute for Science, Technology and Education (IISTE). The IISTE is a pioneer in the Open Access Publishing service based in the U.S. and Europe. The aim of the institute is Accelerating Global Knowledge Sharing.

More information about the publisher can be found in the IISTE's homepage:

<http://www.iiste.org>

## CALL FOR JOURNAL PAPERS

The IISTE is currently hosting more than 30 peer-reviewed academic journals and collaborating with academic institutions around the world. There's no deadline for submission. **Prospective authors of IISTE journals can find the submission instruction on the following page:** <http://www.iiste.org/journals/> The IISTE editorial team promises to review and publish all the qualified submissions in a **fast** manner. All the journals articles are available online to the readers all over the world without financial, legal, or technical barriers other than those inseparable from gaining access to the internet itself. Printed version of the journals is also available upon request of readers and authors.

## MORE RESOURCES

Book publication information: <http://www.iiste.org/book/>

Recent conferences: <http://www.iiste.org/conference/>

## IISTE Knowledge Sharing Partners

EBSCO, Index Copernicus, Ulrich's Periodicals Directory, JournalTOCS, PKP Open Archives Harvester, Bielefeld Academic Search Engine, Elektronische Zeitschriftenbibliothek EZB, Open J-Gate, OCLC WorldCat, Universe Digital Library, NewJour, Google Scholar

