

Radiological Findings in Sputum Positive and Sputum Negative Tuberculous Infected Patients: A Comparative Study

Ahmed Hussein Jasim*

Dept. of Medicine/ College of Medicine /Babylon University/ Babylon, Iraq
Department of Medicine College of Medicine/Babylon University
Hilla /Babylon Governorate/ Iraq

Abstract

Background: Tuberculous infection is a long term chest spoiling which is initiated by mycobacterial bacilli. Tuberculosis implants in higher than the one third from all cases of passing in the nineteenth and twentieth centuries, and it causes infection in about one third over the world. Those best and the majority conclusive system in the finding from claiming lung tuberculous infection is sputum sample, also Ziehl Neelsen staining for a few successive samples. For smear negative furthermore actually smear positive cases, radiographic features would supportive clinched alongside illness finding.

Aim of this study: This study need been carried to look at radio-logical findings done for sputum positive, also sputum negative tuberculosis patients.

Patients and Methods: This cross sectional ponder might have been conveyed out in Baghdad teaching hospital in respiratory specialized clinic in about 1st of January to September of 2016 .there are 79 patients were enrolled in this study that diagnosed as pulmonary tuberculosis according to WHO criteria for diagnosis of pulmonary TB in which 52 patients were diagnosed as sputum positive TB and 27 patients diagnosed as sputum negative but culture positive all the participant in this study should have postero-anterior chest x-ray and should be interpreted by at least two specialized radiological professional independently and sputum smear examined by bacteriologist expert .

Results: In our study the chest x-ray finding (calcification, hilar lymphadenopathy, apical infiltrations, mediastinal widening, bronchiectasis and cavity) more visible findings in sputum positive patients than sputum negative pulmonary TB, which are statistically significant P value <0.05. While (reticulonodular infiltrations, lung fibrosis, pleural effusion and miliary shadowing) are more visible findings in sputum negative patients than sputum positive lung TB patients which are statistically insignificant P value >.05.

Conclusions: the chest x-ray finding (calcification, hilar lymphadenopathy, apical infiltrations, mediastinal widening, bronchiectasis and cavity) more visible findings in sputum positive patients than sputum negative pulmonary TB, While (reticulonodular infiltrations, lung fibrosis, pleural effusion and miliary shadowing) are more visible findings in sputum negative.

Keywords tuberculosis (TB), sputum negative, sputum positive.

Introduction

Tuberculosis is a long term chest spoiling which is initiated by mycobacterial bacilli. Tuberculosis implants in higher than the one third from all cases of passing in the nineteenth and twentieth centuries, and it causes infection in about one third over the world. Tuberculous infection makes 9 million new diagnoses furthermore 2 million passing every year ⁽¹⁻³⁾. The prevalence for tuberculosis diminished with 5% yearly until 1995⁽⁴⁾, Right now tuberculous infection for association with procured immunodeficiency disease. (AIDS) may be those greater public health issues on latin America, Africa Furthermore Asia. Tuberculous infection might have been called a crisis by WHO over 1993^(4,5). Tuberculous infection is a major cause of death and a major health issues over the world. Tuberculous infection was revealed that 9 million new infection and 1.5 million deaths happened in 2013⁽⁶⁾. Those best and the majority conclusive system in the finding from claiming lung tuberculous infection is sputum sample, also Ziehl Neelsen staining for a few successive sample ⁽¹⁻³⁾. for smear negative furthermore actually smear positive cases, radiographic features would supportive clinched alongside illness finding. Despite exactly midsection X-ray findings, including nodular or patchy infiltration in the posterior parts of the superior lobes or anterior segments of the inferior lobes bilateral involvement and associated with cavity, are not particular to pulmonary tuberculosis, clinical. Manifestations Furthermore epidemiologic discoveries would extremely helpful to reach the diagnosis ^(7, 8). Generally, as common radiologic discoveries in secondary pulmonary tuberculosis need aid exhibited as takes after: bronchiectasis, consolidation, patchy, cavitary, and miliary tuberculosis ^(9, 10).

Patients and Methods

This cross sectional ponder might have been conveyed out in Baghdad teaching hospital in respiratory specialized clinic in about 1st of January to September of 2016 .there are 79 patients were enrolled in this study that diagnosed as pulmonary tuberculosis according to WHO criteria for diagnosis of pulmonary TB in which 52

patients were diagnosed as sputum positive TB and 27 patients diagnosed as sputum negative but culture positive all the participant in this study should have postero- anterior chest x-ray and should be interpreted by at least two specialized radiological professional independently and sputum smear examined by bacteriologist expert . WHO criteria for diagnosis of TB there are at least two sputum smear positive and clinical feature suggestive of TB , where smear negative depend on clinical finding suggestive TB ,radiological features and sputum culture.

Statistical Analysis: The collected data analyzed by using SPSS version 22 for window where Continuous variables presented as means with standard deviation while discrete variables presented as numbers and percentages .The T paired test was used to test the significance of cooperation between discrete variables. P value <0.05 might have been regarded as statistically significance.

Results

This study is cross sectional descriptive –analytic study there are 79 patients were enrolled for this study where divided in two groups sputum positive TB (53 patients) and sputum negative but culture positive TB (27 patients) .in sputum positive group the mean age (47.15± 17.49 years) ,and sputum negative group the mean age (44.59± 16.36 years) (P value =0.076).

When we compare the radiological findings between the smear positive group and smear negative group respectively we find the calcification in both groups respectively are about (19/52 (36.5%)), (6/27(22.2%)) (P value= .000). see table 1, figure 1.

The hilar lymph adenopathy (16/52 (30.8%)), (3/27(11.1%)) respectively, (P value=.030).see table 1, figure 2.

The Apical infiltrations (17/52 (32.7%)), (5/27(18.5%)) respectively (P value=.04). see table 1, figure 3.

The Widening mediastinum (5/52 (9.6%)), (1/27(3.7%)) respectively (P value=.032). see table 1.

The Bronchiectasis (8/52 (15.4%)), (2/27(7.4%)) respectively (P value=.034). see table 1.

The Reticulonodular infiltration (22/52 (42.3%)), (13/27(48.1%)) respectively (P value=.057). see table 1.

The Lung fibrosis(10/52 (19.2%)), (3/27(11.1%)) respectively (P value=.11). see table 1.

The cavity (24/52 (46.2%)), (6/27(22.2%)) respectively (P value=.034). see table 1, figure 4.

The Pleural effusion (12/52 (23.1%)), (7/27(25.9%)) respectively (P value= .074). see table 1.

The Miliary finding (1/52 (1.9%)), (1/27(3.7%)) respectively (P value=.072).see table 1.

Table 1.chest x-ray findings in sputum Positive and sputum Negative patients

Radiographic features	Sputum positive TB	Sputum negative TB	P value
Age	47.15± 17.49	44.59± 16.36	.076
Calcification	19/52 (36.5%)	6/27(22.2%)	.000
Hilar lymph adenopathy	16/52 (30.8%)	3/27(11.1%)	.030
Apical infiltrations	17/52 (32.7%)	5/27(18.5%)	.04
Widening mediastinum	5/52 (9.6%)	1/27(3.7%)	.032
Bronchiectasis	8/52 (15.4%)	2/27(7.4%)	.034
Reticulonodular infiltration	22/52 (42.3%)	13/27(48.1%)	.057
Lung fibrosis	10/52 (19.2%)	3/27(11.1%)	.11
cavity	24/52 (46.2%)	6/27(22.2%)	.034
Pleural effusion	12/52 (23.1%)	7/27(25.9%)	.074
Miliary TB	1/52 (1.9%)	1/27(3.7%)	.072

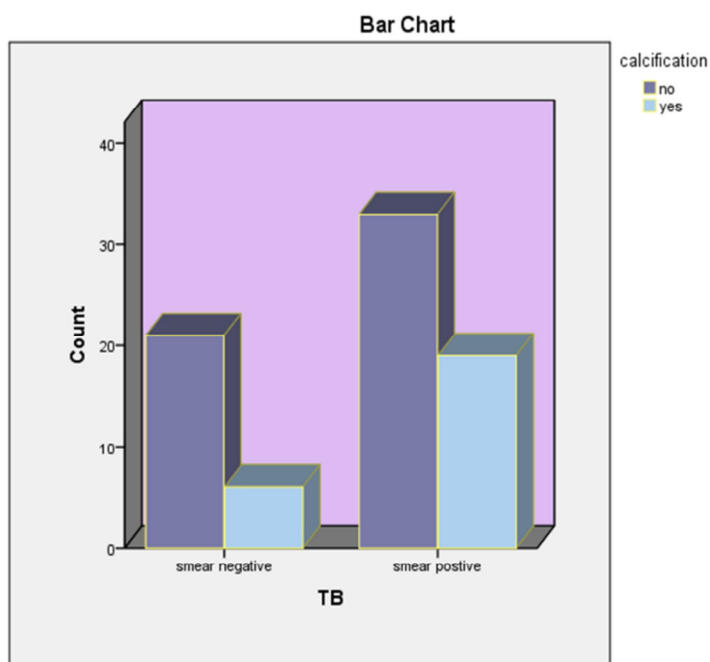


Figure 1 show calcification in the PTB sputum negative and positive

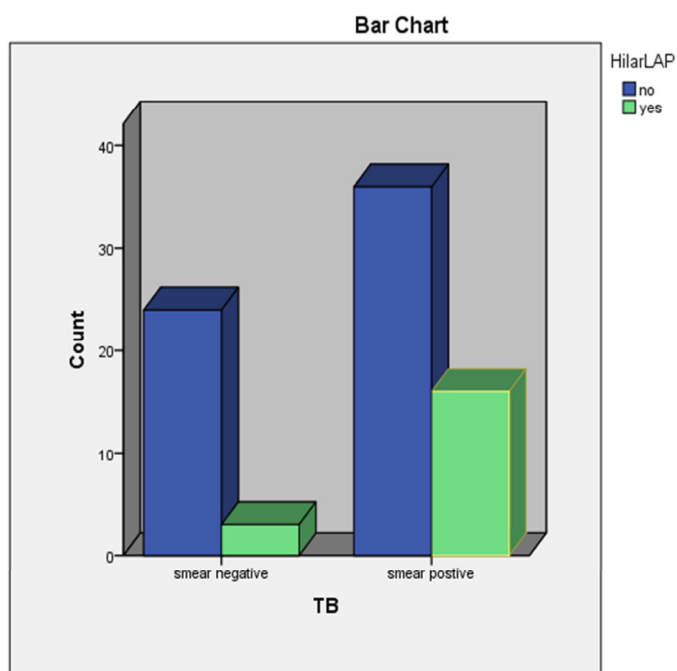


Figure 2 show hilar lymph adenopathy in the PTB sputum negative and positive

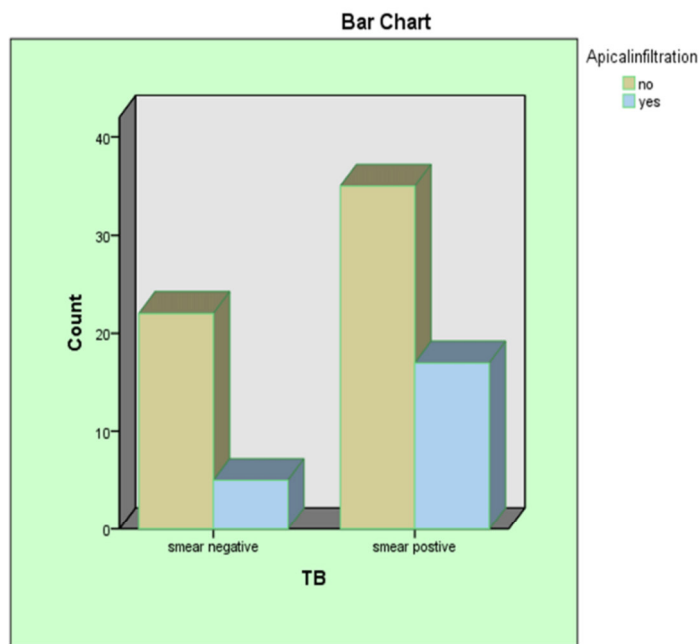


Figure 3 show apical infiltration in the PTB sputum negative and positive.

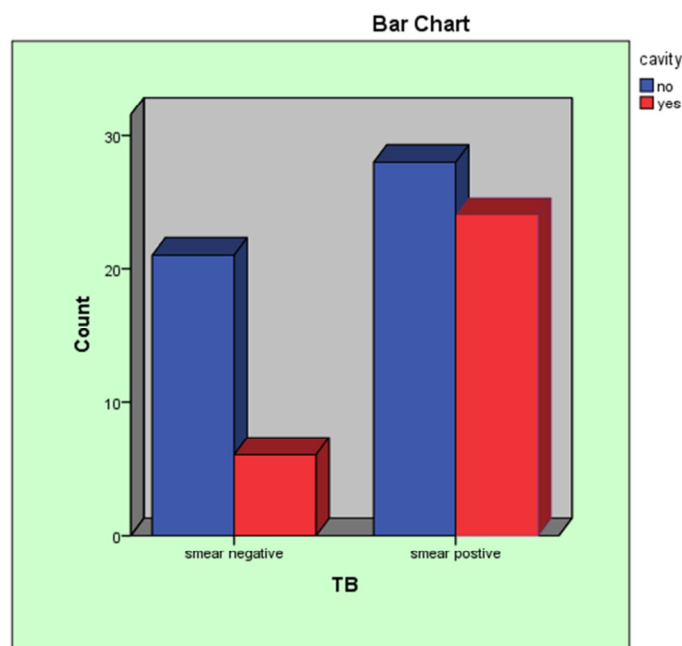


Figure 4 show cavity in the PTB sputum negative and positive.

Discussion

It's important to know and practicing the differences which are noticed in the sputum negative and sputum positive TB as appropriately 10–20% of those intimate contacts of patients with sputum-positive lung TB and 2–5% of those with sputum-negative but culture-positive disease have chance of developing TB infection⁽¹¹⁾ Something like that ID number of possible cases from claiming sputum-positive alternately negative AFB camwood takes part on accomplishing the objective from claiming WHO. which will be dedicated should diminishing those frequency from claiming tuberculosis since 2015 by supporting the improvement from claiming lab Also health-care benefits on enhance identification the active and latent tuberculosis which may be a paramount part from this objective⁽¹¹⁾.

Therefore over our study, those patients who needed been affirmed Hosting pulmonary tuberculosis were compared in the expression about radiologic characteristics furthermore lab discoveries What's more here our discoveries would compared with other studies.

In our study the chest x-ray finding (calcification, hilar lymphadenopathy, apical infiltrations, mediastinal widening, bronchiectasis and cavity) more visible findings in sputum positive patients than sputum negative pulmonary TB, which are statistically significant P value <0.05 see table 1. While (reticulonodular infiltrations, lung fibrosis, pleural effusion and miliary shadowing) are more visible findings in sputum negative patients than sputum positive lung TB patients have been acknowledged statistically significance. P value $>.05$ see table 1.

In other studies van Cleef et al. they found that pleural effusion (15%); cavity (30%) and reticulonodular infiltration (55%) Were more incessant to sputum negative over sputum positive conditions (P < 0.001). Whilst, calcification (45%), bronchiectasis (22%), lymph nodes (30%). and patchy infiltration (45%) were more visible in sputum positives in compare to the sputum negative patients (P = 0.001)⁽¹²⁾.

Rathman et al. They observed the cavity in sputum positive patients higher than sputum negative patients (40% vs. 25%), (P < 0.001). In addition, calcification was fundamentally higher findings in sputum positives than sputum negatives patients (P < 0.001)⁽¹³⁾.

Gartner et al. the radiological lesions compatible with sputum negative TB, diffuse reticulonodular infiltration, pleural effusion and hilar or mediastinal adenopathy were more findings⁽¹⁴⁾.

Bakhshayeshkaram et al. on one hundred sputum positive pulmonary tuberculosis, the practical radiological features were:, the cavity (60%), Adenopathy (36%) , pleural thickening (45%), fibrosis (30%) , and reticulonodular infiltration (98%)⁽¹⁵⁾.

In previous ponder the sputum-positive TB (fifty patients), cavity with or without infiteration in the upper lung lobes (78%), pleural effusion (45%) and hilar and mediastinal lymph nodes (65%), were prominent chest x-ray findings as with our findings⁽¹⁶⁾.

Miller et al. the radiological finding in sputum positive TB were calcification cavitation, and patchy infiltration⁽¹⁷⁾

In previous ponder of 518 tuberculous cases, 14.8% of all cases with sputum negative had prominent radiological features that similar with lung tuberculosis⁽¹⁸⁾.

Razaghi et al. on one hundred pulmonary tuberculosis cases, the visible radiological findings were, bronchiectasis (13%), reticulonodular infiltration (18%) and atelectasis (3%)⁽¹⁹⁾.

Reference

1. Raviglioni MC, O' Brein RJ. Tuberculosis. In: Fauci A, Braunwald E, Kasper D, Hauser S, Longo D, Jameson J, et al editors. Harrison's Principles of Internal Medicine. 17th ed: Mcgraw-hill; 2008. pp. 1006–21.
2. Harper C, Watt Y, Raviqlion ML. Infectious Diseases, Tuberculosis. In: Cecil RLF, Goldman LW, Ausiello DA editors. Cecil Medicine. 23th ed: W.B. Saunders Elsevier; 2008. pp. 2292–307.
3. Fitzqeraid DW, Sterling TR, Haas DW. Tuberculosis. In: Mandell GL, Bennett JE, Dolin R editors. Mandell, Douglas, and Bennett's principles and practice of infectious diseases. 7th ed: Churchill Livingstone/Elsevier; 2010.
4. Dye C, Watt CJ, Bleed DM, Hosseini SM, Raviglione MC. Evolution of tuberculosis control and prospects for reducing tuberculosis incidence, prevalence, and deaths globally. JAMA. 2005; 293(22):2767–75.
5. Harper ME, Hill PC, Bah AH, Manneh K, McAdam KP, Lienhardt C. Traditional healers participate in tuberculosis control in The Gambia. Int J Tuberc Lung Dis. 2004; 8(10):1266-8.
6. Resaii AR, Hendesi F, Rezvani SM, editors. Epidemiology of tuberculosis in Gillan (1996- 2006); 18th national congress on tuberculosis; 2007; Sanandaj, IR Iran. p. 1.
7. Van Cleeff MR, Kivihya-Ndugga LE, Meme H, Odhiambo JA, Klatser PR. The role and performance of chest X-ray for the diagnosis of tuberculosis: a cost-effectiveness analysis in Nairobi, Kenya. BMC Infect Dis. 2005; 5:111.
8. Rafii S, Sedaghat M, Anvari R, Hessam H, Nosrati HR, Mofidi AM, editors. Smear positive pulmonary tuberculosis in Golestan; 18th national congress on tuberculosis; 2007; Sanandaj, IR Iran. p. 5.
9. McCray E, Weinbaum CM, Braden CR, Onorato IM. The epidemiology of tuberculosis in the United States. Clin Chest Med. 1997; 18(1):99–113.
10. Martin G, Lazarus A. Epidemiology and diagnosis of tuberculosis. Recognition of at-risk patients is key to prompt detection. Postgrad Med. 2000; 108(2):42-4–53-4.
11. P.T. Reid J.A. Innes. Davidson's principle and practice of medicine. Respiratory disease-tuberculosis, 22nd edition: Nicki R Colledge; 2014.pp.694-5.
12. Van Cleeff MR, Kivihya-Ndugga L, Githui W, Nganga L, Odhiambo J, Klatser PR. A comprehensive study of the efficiency of the routine pulmonary tuberculosis diagnostic process in Nairobi. Int J Tuberc Lung Dis. 2003; 7(2):186–9.
13. Rathman G, Sillah J, Hill PC, Murray JF, Adegbola R, Corrah T, et al. Clinical and radiological presentation of 340 adults with smear-positive tuberculosis in The Gambia. Int J Tuberc Lung Dis. 2003; 7(10):942–7.

14. Gardner EM, Burkhardt KR. Correlation of the results of X-ray and sputum culture in tuberculosis prevalence surveys. *Tubercle*. 1980; 61(1):27–31.
15. Bakhshayesh KM, Masjedi MR, Ashanti H, Kiani F. Chest X-ray findings in smear positive pulmonary tuberculosis patients. *J Trop Infect Dis*. 1996; 1:24–8.
16. Cohen R, Muzaffar S, Capellan J, Azar H, Chinikamwala M. The validity of classic symptoms and chest radiographic configuration in predicting pulmonary tuberculosis. *Chest*. 1996; 109(2):420–3.
17. Miller WT, MacGregor RR. Tuberculosis: frequency of unusual radiographic findings. *AJR Am J Roentgenol*. 1978; 130(5):867–75.
18. Hernandez-Garduno E, Cook V, Kunimoto D, Elwood RK, Black WA, FitzGerald JM. Transmission of tuberculosis from smear negative patients: a molecular epidemiology study. *Thorax*. 2004; 59(4):286–90.
19. Razaghi R, Talari HR, Akbari H, Lotfi A, editors. Chest X-ray findings in elderly pulmonary tuberculosis patients that referred to Kashan center control of disease 1996-2006.; 18th national congress on tuberculosis; 2007; p. 20.