

Gynecological Disorders and the Management of Interventional Radiology

Dr. Sultan Ali Saleh Alsaleh Dr. Ayman Jehad Abed Abutaima
Dr. Nada Saleh Ahmed Qaid Dr. Amal Ali Ahmad Dehbash
Dr. Abeer Mohammed Al-Nagri Dr. Alsharari Yazeed Mohammed Q

Abstract

This study aimed at exploring the management of interventional radiology in gynecological disorders, by highlighting the importance of interventional radiology in treating a comprehensive range of obstetric and gynecological pathologies. The study concluded that laparotomy should be performed if the woman is not stable enough to wait for the embolization procedure or for completion of a difficult procedure. If the time permits, angiographic occlusion balloon catheters can be placed to temporarily occlude the hypogastric or common iliac arteries (or even in the aorta) while end route to the operating room or during the surgery.

Acknowledgment

This research has been prepared through cooperation and concerted efforts of the researchers in collecting and compiling the necessary data; each researcher with a certain role. Hence, this research was conducted with the joint efforts of the researchers; Dr. Sultan Ali Saleh Alsaleh and Dr. Ayman Jehad Abed Abutaima as main authors, and Dr. Nada Saleh Ahmed Qaid, Dr. Amal Ali Ahmad Dehbash, Dr. Abeer Mohammed Al-Nagri and Dr. Alsharari Yazeed Mohammed Q as co-authors.

The researchers thank everyone who contributed to providing the data and information that helped to accomplish this research.

Introduction

Image guided procedures have played an important and helpful adjunct in the diagnostic evaluation and treatment of the gynaecological patient. Since the 1970's, a number of vascular and non-vascular procedures have been developed and refined to provide solutions to some of the most difficult problems facing the gynaecological patient and their doctors.

Interventional radiology is continuing to reshape current practice in many specialties of clinical care. It is a relatively new and innovative branch of medicine in which physicians treat diseases non-operatively through small catheters guided to the target by fluoroscopic and other imaging modalities. The aim is to provide image-guided, minimally invasive alternatives to traditional surgical and medical procedures in suitable cohorts of patients. Procedures which previously required major surgery can now be performed by interventional radiologists, sometimes on an outpatient basis, with little patient discomfort. In this review, the researchers highlight the importance of interventional radiology in treating a comprehensive range of obstetric and gynecological pathologies (Ganeshan, Nazir, Hon, Upponi, Foley, Warakaulle & Uberoi, 2010).

Gynecological disorders (*see figure 1*) are conditions which affect the female reproduction organs, namely the breasts and organs in the abdominal and pelvic area including the womb (uterus), ovaries, fallopian tubes, vagina and vulva. Virtually every woman will suffer a gynecological condition at some point in her life. For most, it will be minor and easily treatable, but for others their condition may have devastating consequences - impacting their ability to have children and even, with some illnesses, threaten their life (Lawrence, Lukacz, Nager, Hsu & Lubner, 2008).

Percutaneous transcatheter interventional procedures are increasingly being employed in the management of obstetric and gynecological disorders (Gooding, D'Agostino & Plaxe, 1999).

This technology offers a minimally invasive and potentially cost effective alternative for management of several common obstetrical and gynecological problems. It is most commonly used for managing fibroids and postpartum hemorrhage. However, these procedures have not been evaluated against other treatment modalities in large randomized trials.

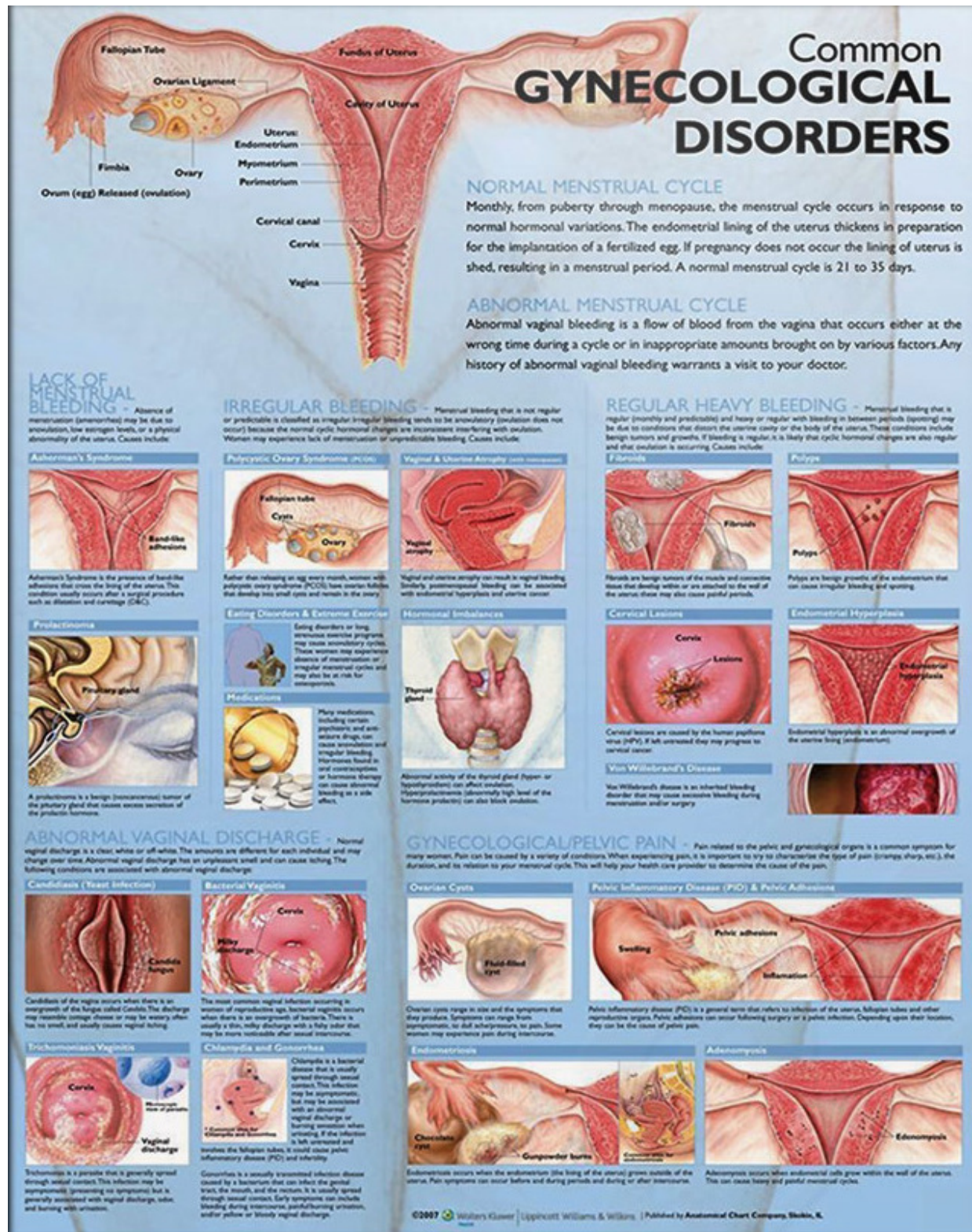


Figure (1): Common Gynecological Disorders: source: ClinicalPosters, <https://clinicalposters.com/anatomy/body/074.html>

Transcatheter Embolization Procedure

Percutaneous transcatheter embolization (PTE) procedures are typically performed under fluoroscopic guidance in the radiology suite. Intravenous conscious sedation and narcotics, local anesthetics, non-opioid analgesics, or nonsteroidal anti-inflammatory agents are administered for management of anxiety and pain. Many radiologists give intravenous broad spectrum antibiotic prophylaxis (eg, cephalothin 1 to 2 g plus metronidazole 1.5 g,

levofloxacin 500 mg or gentamicin 80 mg plus clindamycin phosphate 900 mg) to reduce the risk of infection, although randomized controlled clinical trials have never validated the use of antibiotics in this setting for reduction of postoperative morbidity (Ryan, Ryan & Smith, 2004).

The Seldinger technique is used to introduce a catheter into the femoral artery (*see figure 2*).

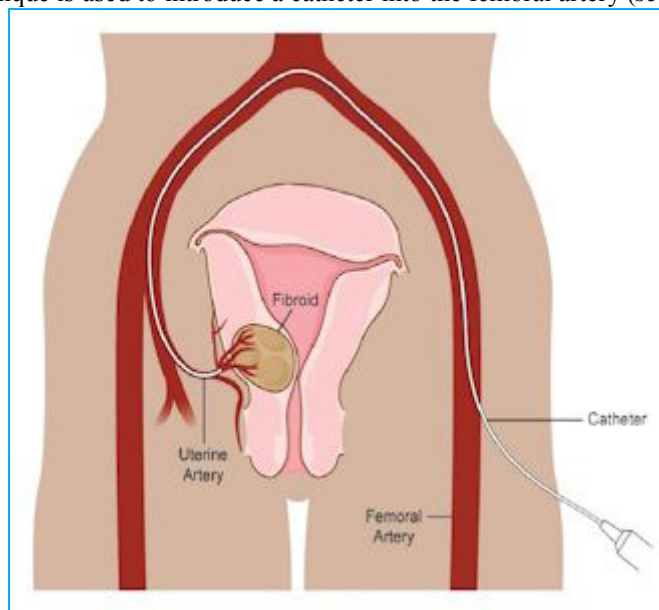


Figure (2): Diagram showing super-selective catheter position in the right uterine artery via left femoral arterial approach.

The catheter is then advanced into the hypogastric or uterine artery, depending upon the indication for the procedure. After sub-selective catheterization, diagnostic angiography of the artery is obtained to confirm proper position, look for extravasation suggestive of acute bleeding, and evaluate for abnormal vascularity associated with chronic bleeding. Transcatheter embolization of one or more arteries can then be performed.

Tiny particles or microspheres (polyvinyl alcohol particles, 500 to 700 and/or 700 to 900 microns in size or tris-acryl gelatin microspheres, 500 to 700 and/or 700 to 900 microns in size) are used to embolize hyper-vascular lesions, such as leiomyomas or Adenomyosis, associated with multiple large feeding vessels. However, particulate embolic agents should be avoided when iliac or uterine or ovarian arteriovenous malformation/fistula are targeted because inadvertent pulmonary embolization may result. Gel foam, coils, and glue are more effective than microspheres for embolization of large arteries associated with acute obstetrical hemorrhage, arteriovenous malformation, or some fistula.

Uterine Fibroids

Uterine fibroid embolization (UFE) is based upon the hypothesis that reduction of myometrial arterial blood flow will result in infarction of fibroids and control symptoms (Ravina, Herbreteau & Ciraru, 1995).

It is an option for symptomatic premenopausal women who wish to retain their uterus, escape side effects associated with prolonged medical therapy, and avoid surgical treatment (eg, hysterectomy, myomectomy) (Goldberg, Pereira & Berghella, 2002).

UFE is rarely indicated in postmenopausal women. Other relative contraindications to UFE include current use of GnRH analogs, submucosal fibroids, and, possibly, plans for future pregnancy. The procedure is discussed in detail separately.

Adenomyosis

Adenomyosis refers to the presence of endometrial glands and stroma within the uterine musculature (uterine adenomyomatosis). Approximately 50 percent of affected women have co-existent fibroids and the symptoms of the two conditions often overlap. As a result, uterine artery embolization's (UAE) have been performed in many women with both fibroids and adenomyosis without a clear understanding of what proportion of the patient's symptoms were related to one condition or the other. Nevertheless, UAE has generally led to relief of symptoms (eg, bleeding, pain) in these patients and follow-up imaging has documented morphologic regression (*see figure 3: a,b*) (Siskin, Tublin & Stainken, 2002).

These observations led to investigation of UAE for treatment of symptomatic adenomyosis in women without coexistent fibroids. Over 90 percent of patients had resolution or significant reduction of dysmenorrhea and menorrhagia over short-term follow-up (Pelage, Jacob & Fazel, 2005).

However, limited data suggest these benefits may not be durable: the frequency of recurrent adenomyosis after UAE (up to 44 percent) was greater than the reported frequency of recurrent fibroids after UFE (10 to 15 percent).

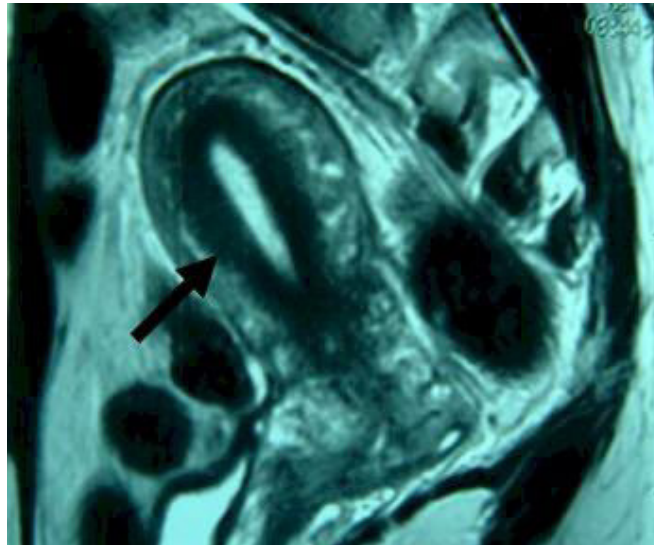


Figure (3a): Sagittal fast spin-echo T2-weighted MR image obtained before embolization shows global uterine enlargement and diffuse adenomyosis. Junctional zone thickness (arrow) is 14 mm.

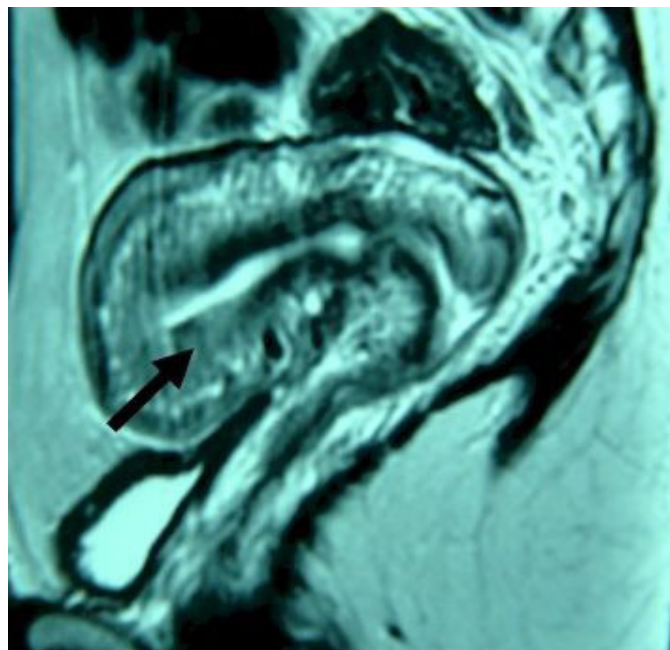


Figure (3b): Sagittal spin-echo T2-weighted MR image obtained three months after embolization shows normal junctional zone thickness (arrow). The patient's symptoms improved significantly after uterine fibroid embolization. Follow-up MR of the pelvis one year later showed no changes from 3-month follow-up study and no evidence of recurrence.

UAE for management of adenomyosis related symptoms is a nonsurgical option for patients who did not respond to other therapies and want to avoid hysterectomy, the only definitive therapy. While the preliminary experiences presented in literature appear encouraging, larger prospective studies are needed to establish the safety and efficacy of this procedure for patients with adenomyosis.

Arteriovenous Malformation

Arteriovenous malformation (AVM) of the uterus is rare, but can be a life-threatening condition (Ghai, Rajan & Asch, 2003).

This lesion has been variably described as a cirroid aneurysm, arteriovenous aneurysm, arteriovenous fistula, and cavernous hemangioma. Approximately one-half are congenital and present with sudden uterine

bleeding without any prior history of surgical instrumentation (*see figure 4*).

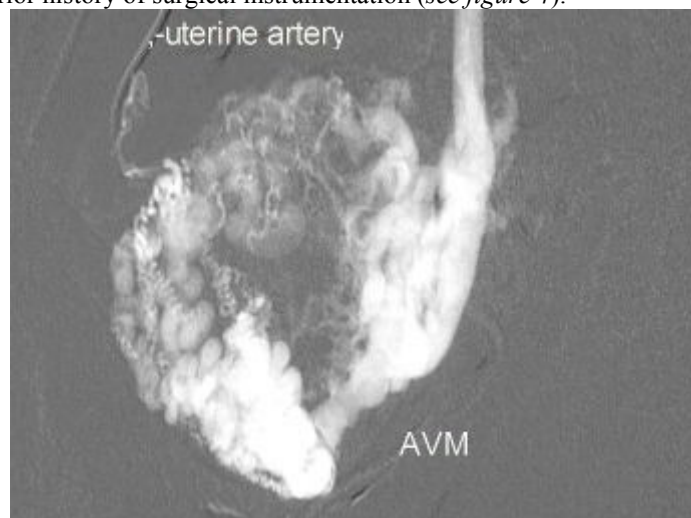


Figure (4): Right uterine angiography on a 42-year-old woman who presented with sudden uterine bleeding. Angiogram shows very dilated uterine artery and veins with nidus of dilated tangled blood vessels within the uterine wall consistent with arteriovenous malformation (AVM).

By comparison, acquired AVMs occur after uterine instrumentation (eg, curettage) or associated with disorders such as gestational trophoblastic disease, endometrial adenocarcinoma, or maternal diethylstilbestrol exposure.

The most prominent clinical manifestation is a history of refractory uterine bleeding during the reproductive years. It is not unusual for patients with AVMs to present with severe episodes of bleeding, hypotension, and anemia, which tend to be intractable to medical and hormonal treatment. The bleeding presumably occurs when the vessels erode through or about the endometrium, becoming exposed or shedding.

If an AVM is suspected, imaging studies should be performed before any potentially hazardous diagnostic or therapeutic instrumentation is done. Options include Doppler ultrasound and MR imaging with angiography; consultation with a radiologist is suggested (Nasu, Fujisawa, Yoshimatsu & Miyakawa, 2002).

Initial treatment consists of hemodynamic stabilization with intrauterine Foley bulb for tamponade, methylergonovine (0.2 mg intramuscularly), and intravenous estrogen. Hysterectomy is the definitive therapy, but if the patient desires preservation of her uterus, then UAE appears to be an effective option (*see figure 5a-b*).

Laparoscopic bipolar coagulation of uterine vessels has also been successful in case reports. More than 70 cases of embolization of uterine AVM have been reported. Overall, the embolization procedure was effective in controlling bleeding in 96 percent of patients. Complications occurred in 4 percent, and included transient paresthesia/paralysis of the left arm, difficulty inserting a second coil, and persistence of blue coloration of the cervix and vaginal wall due to ischemic changes. Restoration of normal menstrual cycles and successful pregnancies have been reported. Thus, embolization for uterine AVM can be an effective alternative treatment to hysterectomy.

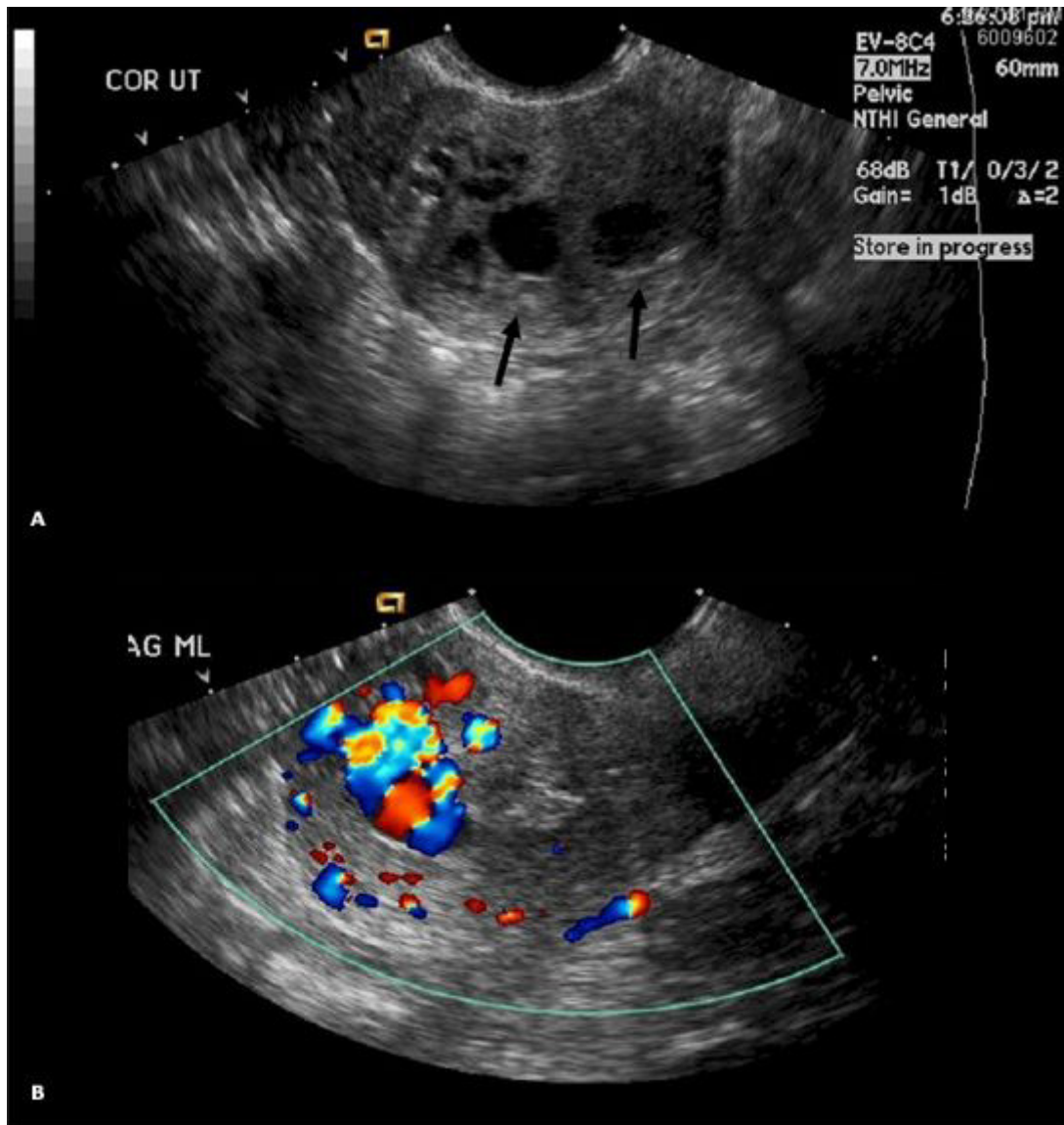


Figure (5a): Ultrasound of the pelvis demonstrates hypoechoic regions (arrows). (B) Duplex color Doppler ultrasound shows a hypervascular lesion within the fundus that measures 2.6x2.3x1.3 cms, consistent with arteriovenous fistula or malformation. She was s/p TAB at 14 weeks, 5 months.

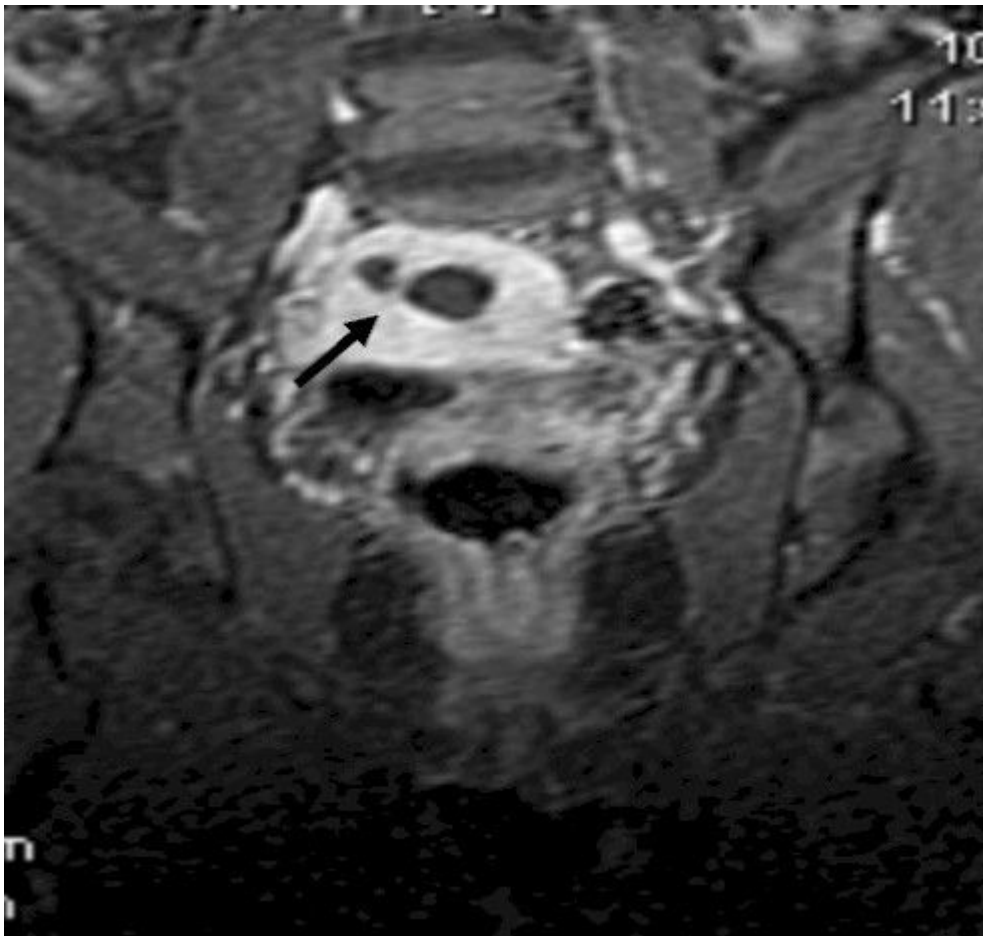


Figure (5b): Coronal view of pelvic MR shows flow void (arrow) in the uterine fundus suggesting a rapid arteriovenous connection.

Pelvic Congestion Syndrome

Up to 15 percent of premenopausal women have pelvic varicosities and venous stasis, as demonstrated by pelvic venography (*see figure 6*), but few experience symptoms. Pelvic congestion syndrome is the term used to describe the subset of these women who have pain and other symptoms in the uterus, ovaries, and vulva that cannot be attributed to any other cause.

Gynecologic examinations are frequently normal in these women. Routine imaging studies may miss ovarian varicosities since the studies are performed in supine position when the veins are flaccid.

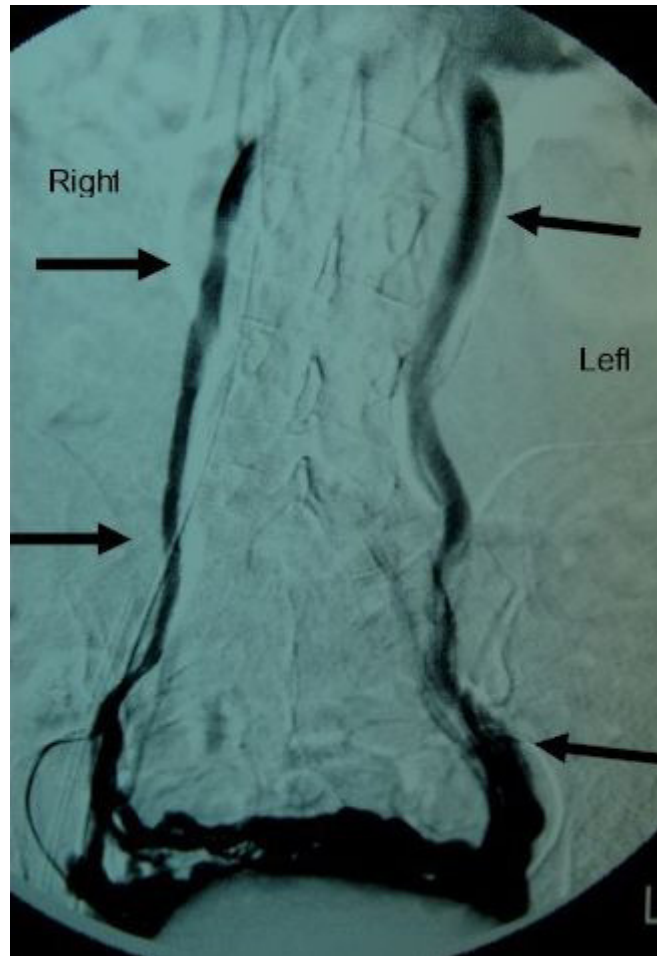


Figure (6): Left ovarian venogram on a 44-year-old woman with chronic pelvic congestion syndrome. There is filling of both markedly dilated ovarian veins (arrows) via venous reflux and interconnecting uterine venous plexus.

Ovarian venography may be considered to confirm the suspected diagnosis since it can be performed in the upright or semi-upright position with a tilting table.

Venography involves catheterization of the right and left ovarian veins via a percutaneous femoral or jugular approach. Ovarian venograms in patients with pelvic congestion syndrome usually demonstrate abnormally dilated ovarian veins (>10 mm in diameter), reflux causing congestion of the ovarian venous plexus, uterine venous engorgement, and filling of pelvic veins across the midline. After these diagnostic studies, a therapeutic procedure may be done by embolizing the ovarian vein with coils or a sclerosing agent.

Fallopian Tube Recanalization

Tubal abnormalities account for a significant proportion of female infertility. Selective salpingography is a diagnostic procedure in which a catheter is placed in the tubal ostium and contrast media is injected directly into the fallopian tube (Unuane, Tournaye, Velkeniers & Poppe, 2011).

This technique helps to differentiate spasm from true obstruction and to clarify discordant findings from other tests. If persistent proximal tubal occlusion is documented, fallopian tube recanalization may be attempted using a micro-catheter and guidewire system to reanalyze the occlusion (*see figure 7*).

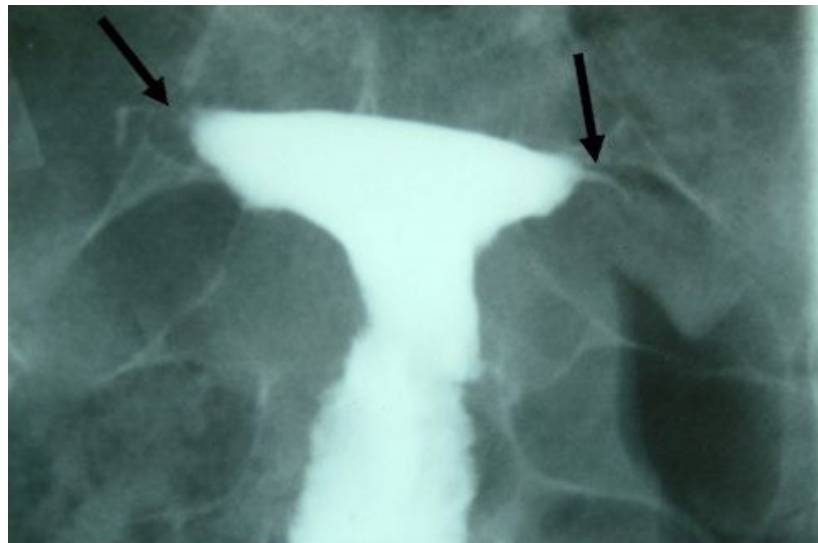


Figure (7): Hysterosalpingogram on a 29-year-old woman with infertility demonstrates occlusion of both fallopian tubes (arrows).

There are no randomized controlled trials evaluating this technique. In observational studies, pregnancy rates after the procedure are difficult to compare because of the multifactorial causes of infertility, but are reported to range from 9 to 56 percent (average 30 percent). The optimum treatment for woman with tubal occlusion is discussed separately.

Complications of fallopian tube recanalization are uncommon and include tubal perforation (2 percent), ectopic pregnancy (3 to 9 percent) percent, pelvic infection (1 percent).

Ovarian exposure to radiation is approximately 1 rad (10 mGy), a dose that is considered within acceptable limits for women of reproductive age. The procedure is performed in the follicular phase of the ovulatory cycle to try to ensure that the woman is not pregnant. Although selective salpingography and tubal catheterization under fluoroscopic guidance has been endorsed by professional societies such as the American Fertility Society in 1993 and Royal College of Obstetricians and Gynaecologists in 1998, it is still only offered by a few tertiary reproductive medicine units (Cheong & Stones, 2006).

The reasons for this might be due to concern about the technical difficulty of the procedure and the consequences of irradiation of ovaries in premenopausal women, as well as being a method relevant only to infertile women with proximal tubal blockage, a relatively infrequent presentation.

A wider role for selective salpingography and tubal catheterization in the management of infertility has been advocated since the technique is relatively simple, requires only modest equipment, and appears to be effective. Its use may reduce the utilization of more expensive diagnostic and therapeutic interventions.

Summary and Recommendations

Percutaneous transcatheter embolization procedures are performed under fluoroscopic guidance in the radiology suite with intravenous conscious sedation, analgesics, and antibiotic prophylaxis. Gel foam, coils, and glue are preferred for embolization of large arteries and tiny particles or microspheres are preferred for small arteries. Uterine fibroid embolization is a nonsurgical option for management of fibroid related symptoms that has shown excellent technical and clinical success. It is an effective option in women who wish to preserve their uterus, although the risks associated with subsequent pregnancy are unclear.

Postpartum hemorrhage in hemodynamically stable patients can be managed with percutaneous transcatheter embolization. Consultation with an interventional radiologist should be obtained early to facilitate decision making. The physician needs to consider that if embolization is unsuccessful, uterine artery ligation can be attempted subsequently. In contrast, embolization may be extremely difficult, or even impossible, after an unsuccessful uterine artery ligation.

The patient's physician should monitor her status in the angiography suite at the time of an embolization procedure and be ready to proceed to surgical intervention if the patient becomes hemodynamically unstable. A prolonged embolization procedure should be avoided if there appears to be little chance of therapeutic success because the patient's condition may deteriorate and increase the risk of surgical intervention.

Laparotomy should be performed if the woman is not stable enough to wait for the embolization procedure or for completion of a difficult procedure. If the time permits, angiographic occlusion balloon catheters can be placed to temporarily occlude the hypogastric or common iliac arteries (or even in the aorta) while end route to the operating room or during the surgery.

References

- Cheong, Y., & Stones, R. W. (2006). Chronic pelvic pain: aetiology and therapy. *Best Practice & Research Clinical Obstetrics & Gynaecology*, 20(5), 695-711.
- Ganeshan, A., Nazir, S. A., Hon, L. Q., Upponi, S. S., Foley, P., Warakaulle, D. R., & Uberoi, R. (2010). The role of interventional radiology in obstetric and gynaecology practice. *European journal of radiology*, 73(2), 404-411.
- Ghai S, Rajan DK, Asch MR, et al. Efficacy of embolization in traumatic uterine vascular malformations. *J Vasc Interv Radiol* 2003; 14:1401.
- Goldberg J, Pereira L, Berghella V. Pregnancy after uterine artery embolization. *Obstet Gynecol* 2002; 100:869.
- Gooding JM, D'Agostino HB, Plaxe SC. Transcervical metallic stents for drainage of uterine collections. *J Vasc Interv Radiol* 1999; 10:629.
- Lawrence, J. M., Lukacz, E. S., Nager, C. W., Hsu, J. W. Y., & Lubner, K. M. (2008). Prevalence and co-occurrence of pelvic floor disorders in community-dwelling women. *Obstetrics & Gynecology*, 111(3), 678-685.
- Nasu K, Fujisawa K, Yoshimatsu J, Miyakawa I. Uterine arteriovenous malformation: ultrasonographic, magnetic resonance and radiological findings. *Gynecol Obstet Invest* 2002; 53:191.
- Pelage JP, Jacob D, Fazel A, et al. Midterm results of uterine artery embolization for symptomatic adenomyosis: initial experience. *Radiology* 2005; 234:948.
- Ravina JH, Herbreteau D, Ciraru-Vigneron N, et al. Arterial embolisation to treat uterine myomata. *Lancet* 1995; 346:671.
- Ryan JM, Ryan BM, Smith TP. Antibiotic prophylaxis in interventional radiology. *J Vasc Interv Radiol* 2004; 15:547.
- Siskin GP, Tublin ME, Stainken BF, et al. Uterine artery embolization for the treatment of adenomyosis: clinical response and evaluation with MR imaging. *AJR Am J Roentgenol* 2001; 177:297.
- Unuane, D., Tournaye, H., Velkeniers, B., & Poppe, K. (2011). Endocrine disorders & female infertility. *Best Practice & Research Clinical Endocrinology & Metabolism*, 25(6), 861-873.