

# The Value of Ultrasonography in Diagnosis of Acute Appendicitis in Pediatric Age Group

Dr.Ahmed kadhum mohammed FJMC( RAD)  
fellowship of jordanian medical council (radiology)AL-karama teaching hospital

Dr.Haider Ibraheem Khaleel  
Pediatric surgery Central Child Teaching Hospital of Baghdad

Dr. Hussein Ali Abed Ahmad  
Teacher in Wassit medical collage M. B. Ch. B- F.I.C.M.S AL-karama teaching hospital Iraq –wasit province

## Abstract

### BACKGROUND

*Acute appendicitis* is one of the most common surgical emergency condition in pediatric age group that need admission to pediatric surgery unit for emergent operation of appendectomy . Any delayed in the diagnosis and operation lead to very serious outcome ,including perforation , abscess formation and appendiceal mass formation and other complications which may lead to high mortality and morbidity rate in case of absence timely performed operation of appendectomy .

Ultrasound (USG)is one of the most helpful and informative tool in diagnosis of acute appendicitis in children.it is simple , fast , available and with less complications of ionizing radiation that may associated with other modality of radiological methods , like CT .

### Aims of the study

Evaluate the role of USG examination in :-

- 1-diagnosis of children with suspected appendicitis
- 2-defining the sensitivity , specificity and the accuracy rate of acute appendicitis in pediatric age group.
- 3-Decreasing the normal appendectomy in pediatric age group/.

### patients and method

This prospective study has been achieved in the central child teaching hospital in Baghdad during the period from February 2015 to December 2015, that enrolled 110 patients that were admitted pediatric surgery Center in Central Child Hospital in Baghdad who were complained from right lower abdominal pain and acute appendicitis was highly suspected at time of examination .USG examination had been done to these patients.

### Result

Clinical presentation and USG criteria of acute appendicitis had been found in 57 cases out of 110 patients , and those underwent appendectomy operation in the Central Child Teaching Hospital in Baghdad .

Unvisualization of appendix or normal ultrasonography criteria had been found in 53 patients.

6 patients out of the those of 53 patients with negative USG finding underwent appendectomy operation due to persistence of clinical finding, 3 of them were with normal appendix while the 3 others were with inflamed appendix according to histopathological examination.

The other 47 patients from 53 cases who were complain from right lower abdominal pain, but with negative USG findings , kept for observation for 24 hours and then discharged home with follow up these cases by clinical examination and USG once weekly for 2 weeks.

The overall result of a study is as follow :-

Specificity = 100%

Sensitivity = 95%

Accuracy rate =97.27%

Positive predictive value =100%

negative predictive value = 50%

### conclusion

ultrasonographic examination have effective role in diagnosis of acute appendicitis in pediatric age group.

**Keywords:**Acute appendicitis , ultrasonography in acute appendicitis , sensitivity , specificity , accuracy rate.

**DOI:** 10.7176/JHMN/73-06

**Publication date:** April 30<sup>th</sup> 2020

## INTRODUCTION

Acute appendicitis is the most common condition that necessitates acute abdominal surgery in children.[1].It is acute inflammation and infection of the vermiform appendix, which is most commonly referred to simply as the appendix. The appendix is a blind-ending structure arising from the cecum. Acute appendicitis is one of the most

common causes of abdominal pain and is the most frequent condition leading to emergent abdominal surgery in children. The appendix may be involved in other infectious, inflammatory, or chronic processes that can lead to appendectomy [2]. Due to atypical clinical presentation of acute appendicitis, the diagnosis is difficult and may be delayed. Perforation occurs in 23%–73% of children with acute appendicitis [3]. The majority of children with acute abdominal pain, however, have self-limited disease that does not necessitate surgery [4]. A negative appendectomy rate of 15%–25% has been reported.[3,5,6]. Despite considerable recent expansion of knowledge concerning appendicitis, accurate diagnosis remains suboptimal, especially in children.[7]. Initial misdiagnosis rates range from 28% to 57% for children 12 years old or younger, to nearly 100% for those 2 years or younger despite the multiple diagnostic modalities now available to clinicians[7,8]. Importantly, delay in diagnosis lead to increased morbidity and mortality and risk of malpractice litigation [9,10].

### AIMS OF THE STUDY

In the scope of this study we aimed to evaluate the role of ultrasound examination in:-

1. The diagnosis of children with suspected appendicitis.
2. Defining the sensitivity, specificity and the accuracy rate of acute appendicitis in pediatric age group.
3. Decreasing the of normal appendectomy in pediatric age group

### PATIENTS AND METHODS

It is a prospective study done in The Pediatric Surgery Center in collaboration with the department of Radiology in CCTH in Bagdad over a period of 10 months, from February 2015 to December 2015. All patients with suspected acute appendicitis underwent complete evaluation including proper history, clinical examination and laboratory investigations. All patients in the present study underwent USG examination by single pediatric radiologist. The ultrasound operator was GE.Voluson E6, Graded compression with small probe of 5-16 MHZ. A total number of 110 patients with age range from 3 years to 15 years old were included in the present study .Clinical diagnosis of acute appendicitis had been done based on symptom of pain on the right lower quadrant of abdomen, nausea ,vomiting and with other signs of peritoneal irritation including tenderness , rebound tenderness ,cough sign and others . The USG examination applied to all those patients with RLA pain and RIF tenderness who included in the present study .

**Inclusion Criteria:-** □□All patients with age range from 3 years to 15 years old. □□All patients who presented with pain in the right lower abdomen, in whom acute appendicitis was suspected, were included in this study. Patients with a history suggestive of recurrent appendicitis were also included in the study.

**Exclusion Criteria:-** □□Patients with abdominal pain referred or need admission to PCS in CCTH at evening or night due to unavailability of ultrasound at this time . Decreasing the of normal appendectomy in pediatric age group.

Patients with USG from outside of the CCTH when the USG doesn't match with our finding.

**Study protocol :** Clinical diagnosis was done by consultant in PSC in CCTH , based on a pain in the right lower abdomen, nausea ,vomiting and fever. All patients underwent USG examination by single specialist pediatric radiologist. All the patients in present study were kept in the hospital for 24-48 hours with repeated clinical examination in order to prove the diagnosis of acute appendicitis or to exclude it. The patients were kept on nil by mouth, on intravenous fluid and broad spectrum of antibiotic. Depending on clinical finding and USG features, a final surgical management was planned. All the patients in this study had been sent for laboratory investigations. The patients in this study with positive USG findings of A.A. underwent surgical exploration. Those patients with negative finding of USG examination were kept in PSC for 24-48 with repeated clinical evaluation . The patients in this study received intravenous fluid and broad spectrum antibiotics . **The following accepted criteria were considered for the diagnosis of an inflamed appendix:**

- 1) Total diameter of cross section of appendix =5 millimeters or more.
- 2)Visualization of non-compressible tube like structure of blind end.
- 3) Presence of fecolith inside the lumen of appendix which appear as calcified lesion .
- 4) Presence of hypoechogenisty of the appendix.
- 5) Presence of free fluid collection around the appendix or in the pelvis cavity.
- 6) phlegmon sign which is an increase of echogenicity of omentum and periappendiceal fat.
- 7) Wall thickness more than 2 millimeters.
- 8) Distension of the lumen of the appendix due increase appendicullar pressure, mostly due to obstruction
- 9) Mecentric lymph nodes hypertrophy was associated in some patient.
- 10) Loss of continuity of the wall the appendix , which is a sign of perforation. The inquiry form which is applied for all the patients in this study is showed below including clinical, laboratory, radiological and histopathological findings.

## RESULT

During 10 months i.e. the period of our study from February 2015 to December 2015, a total number of 110 patients with right lower abdominal pain had been followed up and admitted to PSC in the CCTH in Baghdad. All of them send for USG examination after taking proper history and full examination according to inquiry formula .Table (1 a,b) analyses the clinical findings of the patients in the study. The patients who carried the radiological features of appendicitis (simple, complicated) were 57 patients and all of them were prepared for surgical exploration under general anesthesia. The remaining 53 patients were kept in the ward of pediatric surgery until the symptoms and signs of abdominal acuity had been resolved. All the remaining 53 patients improved , apart from 6 patients with nonvisualization of appendix on USG examination who continue to suffer from the same symptoms and signs of acute appendicitis and even the pain localized in the right lower abdominal area with deterioration of clinical picture which necessitates exploration under general anesthesia . Those patients are considered as negative result for the present study. The remaining 47 patients were kept in the PSC for 24 -48 hours, treated conservatively and reevaluated clinically and by another USG examination, then transferred to pediatric ward or discharged home according to their condition. Follow up of these 47 patients had been done once weekly after discharged for 2 successive weeks by clinical and USG examination. None of those 47 patients need second admission due to A.A. Those patients with USG findings other than A.A. such as gynecological, urological or other pathology are treated according to their conditions either in CCTH or in refereed to other hospital. All of the patients in the present study who had been explored were divided in to 4 groups as shown in table ( 2 )and fig.3 ,each group of 3 years intervala preschool , early school , late primary school and post primary school age group . The number, gender, age and percentage of distribution as show in the table(3) and fig 4

**Table 1, a, symptoms of acute appendicitis in present study**

Symptoms	Number
Right lower abdominal pain	110
Nausea	98
Vomiting	88
Fever	47
Dysurea	12
Diarrhoea	7

**Table 1, b ,Signs of acute appendicitis in present study**

Signs	Number
RIF. Tenderness	110
Tackycardia	80
Rebound tenderness	70
Cough sign	70
Cuarding	25



	Age	Number of patients	Male	Female	Percentage
Group A	3-6	12	7	5	19.0%
Group B	6-9	24	15	9	38.1%
Group C	9-12	21	13	8	33.3%
Group D	12-15	6	2	4	9.5%
	Total	63	37	26	100%
$\chi^2 = 1.825, df = 3, p\text{-value} = 0.609$ (not significant at 0.05)					

Fig. 3 age distribution of the patients

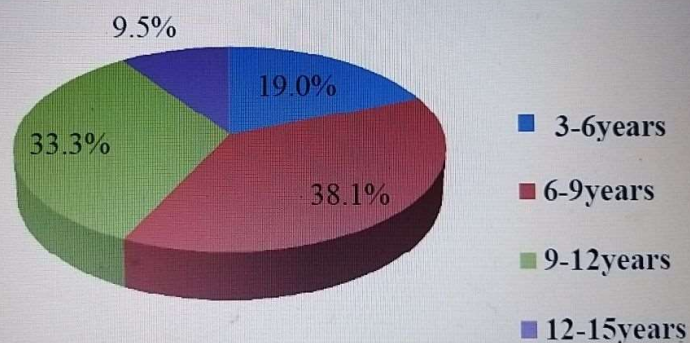


Table 3 show gender and number with percentage of distribution

gender	No. of patients	percentage
Male	68	61.9%
Female	42	38.1%
Total	110	100%

the USG criteria's findings of the explored and improved with acute appendicitis show in table 4. □ Phlegmon :- ultrasound finding of acute appendicitis which represent the increase of perappendiceal echogenicity occur due to

inflammation and perforation of the appendix

Ultrasound signs	Number of cases	Percentage
diameter of cross section of appendix= 5 or more	57	100%
non compressible appendix	50	87.71%
Hypoechogenesi ty of the appendix	50	87.71%
Wall thickness more than 2 millimeters	40	70.17%
free fluid collection	38	66.66%
Mesenteric lymph nodes hypertrophy	25	43.85%
Increase periappendiceal echogenicity (phlegmon)*	42	73.36%
Fecolith	14	24.56%

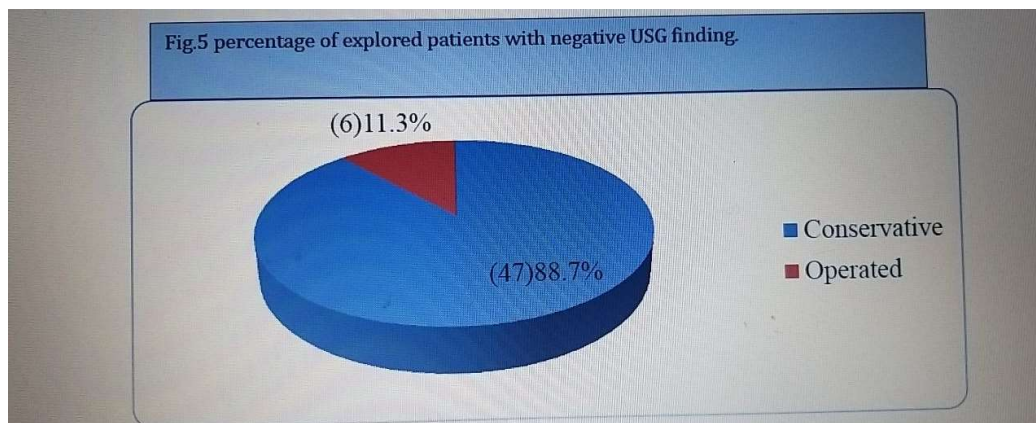
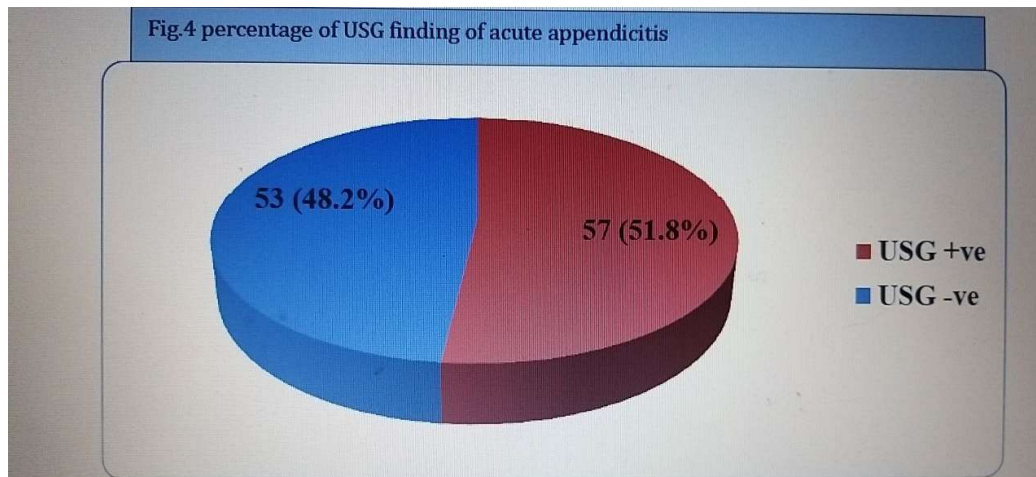
USG examination found that 5 of total patients have a diameter of appendix of less than 5 mm. The operative finding of the patients who explored under general anesthesia in the present study analyzed as shown in table

Category	Number of patients	Male	Female	Percentage
Simple inflamed appendix	22	12	10	34.9%
Suppurative appendicitis	12	6	6	19.047%
Perforated appendix	13	7	6	20.63%
Appendicular lump	3	1	2	4.8%
Appendicolith	10	6	4	15.8%
Normal appendix	3	1	2	4.8%
<b>Total</b>	<b>63</b>	<b>35</b>	<b>28</b>	<b>100.0%</b>

We sent the appendix for those 57 patients( simple, complicated appendicitis) for HPE to prove the clinical and USG examination finding of acute appendicitis which support the diagnosis. Also we send those patients(6) with negative USG examination finding(non visualization of appendix) for HPE which prove 3 of them as acute

In present study we found that 57 patients show positive radiological findings of acute appendicitis while USG show normal appendix in 53 patients. Fig. 4 and 5





## DISCUSSION

In this study we observed that the males were more commonly affected than females, with a male: female ratio of 1.2:1. These results were compared to the study done by Lewis et al[49] who observed that less than 10% of patients were affected in the age group of 1-10 years with male: female ratio of 2:1. Our study showed that highest number of acute appendicitis occurred in the age group of 6-9 years followed by age group of 9-12 years which is consistent with the findings shown by Addis et al[50] that it is most common in 10 to 19 year old age group. This difference in age group in presentation is not so significant according to the statistical analysis of data in the present study (p value =0.609). All patients in this study were complained from right lower abdominal pain followed by nausea and vomiting. Tenderness was present in almost all patients associated with vomiting which was in about 88% , rebound tenderness , cough sign and guarding signs although less frequent . In Tauro LF et al[51] tenderness in the RIF was the most common sign elicited in all patients (100%), while irrespective of the pathology , vomiting was found to be present in 91% of the patients which was the same result of the current study. In this study USG could visualize 57 appendices out of 110 patients who had clinical presentation of a condition mimic acute appendicitis, from which true positive patients of appendicitis were found after surgery and HPE. George et al[43] could diagnose 70 out of 140 patients as acute appendicitis

In this study we observed that the males were more commonly affected than females, with a male: female ratio of 1.2:1. These results were compared to the study done by Lewis et al[49] who observed that less than 10% of patients were affected in the age group of 1-10 years with male: female ratio of 2:1. Our study showed that highest number of acute appendicitis occurred in the age group of 6-9 years followed by age group of 9-12 years which is consistent with the findings shown by Addis et al[50] that it is most common in 10 to 19 year old age group. This difference in age group in presentation is not so significant according to the statistical analysis of data in the present study (p value =0.609). All patients in this study were complained from right lower abdominal pain followed by nausea and vomiting. Tenderness was present in almost all patients associated with vomiting which was in about 88% , rebound tenderness , cough sign and guarding signs although less frequent . In Tauro LF et al[51] tenderness in the RIF was the most common sign elicited in all patients (100%), while irrespective of the pathology , vomiting was found to be present in 91% of the patients which was the same result of the current study.

In this study USG could visualize 57 appendices out of 110 patients who had clinical presentation of a condition mimic acute appendicitis, from which true positive patients of appendicitis were found after surgery and HPE. George et al[43] could diagnose 70 out of 140 patients as acute appendicitis by USG. From these 2 different studies in different locations, we may said nearly 50% of all patients complaining from right lower quadrant pain have acute appendicitis. In present study we identified 5 normal appendices accounting for 4.4 % of the total number of patients. The normal appendix was compressible, less than 5mm in diameter and appeared ovoid in cross-section. In this case we confidently excluded the diagnosis of acute appendicitis. This finding was similar to that of Thomas Rettenbacher et al [53]. The outer diameter of the appendix was greater than 5 mm or more in all the 57(100%) patients. It is similar to the criteria laid down by Thomas Rettenbacher et al[53]and by Jeffrey et al[54]. However recent reports with high frequency transducers are used to show normal appendix in a small percentage of patients (5 out of 250 patients) as reported by Jeffrey et al[54]. Similar findings were shown by Rioux et al[55]. More recently Lee et al[56] reported that with the use of additional operator dependent techniques, detection rates of normal and abnormal appendices have greatly increased. We identified inflamed appendix in 50 patients (87.71%) of the total number of patients where we , they were non-compressible and spherical in shape in all the patients. It is in accordance with Grebeldinger[57] who had concluded that the most relevant criteria for USG evaluation was non-compressibility (97.67%). The overall accuracy of sonography in the diagnosis of acute appendicitis in this study was 97.27 %. The sensitivity, specificity, positive predictive value and negative predictive value of ultrasound scanning with reference to HPE confirmation was 95%, 100%, 100% and 50% respectively which showed that USG has a high specificity and sensitivity in diagnosing appendicitis. The overall specificity and sensitivity rates were comparable to the studies and results of Skanne et al[58], Hahn et al[59] , Tarjan Z et al[60] and Puylaert et al[61] whose specificity values varied from 90- 100% and sensitivity ranges varied from 70-95%. The table below (8) summarizes the results of the present study compared with the results of similar studies done in different parts of the world. Our results are comparable to Joshi et al.[62]. who reported diagnostic accuracy of 95 %, sensitivity of 96 %, specificity 93 % , positive predictive value of 93 % and negative predictive value of 88 %. This study results are also similar to study done by Tauro LF et al[51] who showed sensitivity of 91.37 %, specificity of 88.09 %, positive predictive value of 91.37%, negative predictive value of 88.09 % and diagnostic accuracy of 90 %. **Factors Influencing False Negative Diagnosis of Acute Appendicitis:-** It is reported by Yacoe and Jeffrey[67] that one of the factors responsible for false negative diagnosis in acute appendicitis is retrocaecal position of the appendix and when caecum is filled with gas and feces where adequate compression is not possible. In our study out of 3 false-negative patients, 1 was retrocecal in position and proper evaluation by adequate compression was not possible due to gas distended cecum. In 2 patients appendicitis was missed, as the patients were obese. We missed it to obesity

## CONCLUSION □□

USG is very effective diagnostic tool for acute appendicitis in children .Ultrasound have high specificity (100%) ,high sensitivity (95%) and high accuracy (97.27%) rate in diagnosis of acute appendicitis in children. Informative USG have a major diagnostic rule in decreasing the rate of normal appendectomy in children. High suspicious of A.A. should be considered when it associated with secondary signs by USG examination. Obesity and retrocecal appendicitis should be put in mind whenUSG show no findings of A.A..

## RECOMMENDATION □□

Availability of *ultrasound* examination with radiologist at afternoon and evening time Any child with clinical features of acute abdominal pain associated with two USG signs, that the diameter of appendix=5-6mm or more with loss of its compressibility is diagnosed as acute appendicitis and need appendectomy as soon as possible. Ultrasound is simple and very effective method in diagnosis acute appendicitis and exclude other abdominal pathology ,especially when done by pediatric radiologist . Abdominal and pelvic USG is an excellent screening tool for acute appendicitis. This examination is quick , painless ,does not involve the use of ionizing radiation.

## REFERENCES

- 1 Garcia Pena BM, Mandl KD, Kraus S, Ultrasonography and limited computed tomography in the diagnosis and management of appendicitis in children. *JAMA* 1999; 282:1041–1046.
- 2 Narsule CK, Kahle EJ, Kim DS, Anderson AC, Luks FI. Effect of delay in presentation on rate of perforation in children with appendicitis. *Am J Emerg Med.* 2011 Oct. 29(8):890-3.
- 3 Sivit CJ, Siegel MJ, Applegate KE, Newman KD. Special focus session: when appendicitis is suspected in children. *Radio- Graphics* 2001; 21:247–262.
- 4 Scholer SJ, Pituch K, Orr DP, Clinical outcomes in children with acute abdominal pain. *Pediatrics* 1996; 98:680–685.
- 5 Rao PM, Rhea JT, Rattner DW, Venus LG, Novelline RA. Introduction of appendiceal CT: impact on negative appendectomy and appendiceal perforation rates. *Ann Surg* 1999; 229:344–349.

- 6 Karakas SP, Guelfguat M, Leonidas JC, Springer S, Singh SP. Acute appendicitis in children: comparison of clinical diagnosis with ultrasound and CT imaging. *Pediatr Radiol* 2000; 30:94–98.)
- 7 Rothrock SG, Skeoch G, Rush JJ, Clinical features of misdiagnosed appendicitis in children. *Ann Emerg Med.* 1991;20:45-50.
- 8 Curran TJ, Muenchow SK. The treatment of complicated appendicitis in children using peritoneal drainage: results from a public hospital. *J Pediatr Surg.* 1993;28:204-208
- 9 Rothrock SG, Skeoch G, Rush JJ, Clinical features of misdiagnosed appendicitis in children. *Ann Emerg Med.* 1991;20:45-50.),
- 10 Trautlein JJ, Lambert R, Miller J. Malpractice in the emergency room: a critical review of undiagnosed appendicitis cases and legal actions. *Qual Assur Util Rev.* 1987;2:54-56.).
- 11 Anderson R. Appendicitis, epidemiology and diagnosis. In: Thesis, Linköping University, J Pediatr Surg. 1998)
- 12 Williams R. Development J, structure and function of the appendix and its surgical treatment. London: Chapman & Hall Medical, J Pediatr Surg. 1994:9-30. 35
- 13 Wakeley C. The position of vermiform appendix as ascertained by an analysis of 10,000 cases. *J Anat* 1933;198)
- 14 Abramson D. Vermiform appendix located within the caecal wall. Abnormalities and bizarre locations. *Dis Colon Rectum* 1983;1983-386-389
- 15 Anderen –sandberg A. Appendicitis. Diagnosis, treatment and result in the 2000s. A literature study aiming at evidence based surgery., 2002
- 16 Graffeo CS, Counselman FL. Appendicitis. *J Emerg Med Clin N Am* 1996; 14: 653-671.
- 17 Prystowsky JB, Pugh CM, Nagle AP. Acute appendicitis. *Curr Probl Surg* 2005; 42: 688- 692.
- 18 Birnbaum BA, Wilson SR. Appendicitis at the millennium. *Radiology* 2000; 215: 349-352.
- 19 Rybkin AV, Thoeni RF. Current concepts in imaging of appendicitis. *Radiol Clin N Am* 2007; 45: 411-422
- 20 Kwan KY, Nager AL. Diagnosing pediatric appendicitis: Usefulness of laboratory markers. *Am J Emerg Med* 2010;28: 1009–15
- 21 Alvarado A. A practical score for the early diagnosis of acute appendicitis. *Ann Emerg Med* 1986;15:557–64.
- 22 Samuel M. Pediatric appendicitis score. *J Pediatr Surg* 2002;37:877–81
- 23 Aloo J, Gerstle T, Sgmund II JS. Appendicitis in children less than 3 years of age: a 28- year review. *Pediatr Surg Int* 2004; 19: 777-9.
- 24 Rothrock SG, Pagane J. Acute appendicitis in children: emergency department diagnosis and management. *Ann Emerg Med.* July 2000;36:39-51.
- 25 Smink DS, Finkelstein JA, Kleinman K, The effect of hospital volume of pediatric appendectomies on the misdiagnosis of appendicitis in children. *Pediatrics* 2004;113:18–23.
- 26 Flum DR, Koepsell T. The clinical and economic correlates of misdiagnosed appendicitis: Nationwide analysis. *Arch Surg* 2002;137:799–804.
- 27 Roosevelt GE, Reynolds SL. Does the use of ultrasonography improve the outcome of children with appendicitis? *Acad Emerg Med.* 1998;5:1071-1075.
- 28 Sarfati MR, Hunter GC, Witzke DB, Impact of adjunctive testing on the diagnosis and clinical course of patients with acute appendicitis. *Am J Surg.* 1993;166:660-665.
- 29 Malik AA, Wani NA. Continuing diagnostic challenge of acute appendicitis. *Aust New Zeal J Surg* 1998; 68: 504-505.
- 30 Rothrock SG, Pagane J. Acute appendicitis in children: emergency department diagnosis and management. *Ann Emerg Med.* 2000 Jul.36(1):39-51
- 31 Wiersma F, Toorenvliet BR, Bloem JL, Allema JH, Holscher HC. US examination of the appendix in children with suspected appendicitis: the additional value of secondary signs. *Eur Radiol.* 2009 Feb. 19(2):455-61.
- 32 Sulowski C, Doria AS, Langer JC, Man C, Stephens D, Schuh S. clinical outcomes in obese and normal-weight children undergoing ultrasound for suspected appendicitis. *Acad Emerg Med.* 2011 Feb. 18(2):167-73.
- 33 Lowe LH, Penney MW, Stein SM, et al. Unenhanced limited CT of the abdomen in the diagnosis of appendicitis in children: comparison with sonography. *AJR Am J Roentgenol.* 2001 Jan. 176(1):31-5.
- 34 Pastore V, Cocomazzi R, Basile A, Pastore M, Bartoli F. Limits and advantages of abdominal ultrasonography in children with acute appendicitis syndrome. *Afr J Paediatr Surg.* 2014 Oct-Dec. 11(4):293-6.
- 35 Gracey D, McClure MJ. The impact of ultrasound in suspected acute appendicitis. *Clin Radiol.* 2007 Jun. 62(6):573
- 36 Hernandez JA, Swischuk LE, ngel CA, Chandler R, Lee S. Imaging of acute appendicitis: US as the primary imaging modality. *Pediatr Radiol.* 2005;35:392-5.
- 37 Rybkin AV, Thoeni RF. Current concepts in imaging of appendicitis. *Radiol Clin North Am.* 2007;45:411-22.
- 38 L. Raposo Rodriguez, G. Anes Gonzeza, J.B. Garcia Hernandez, S. Torga Sanchez Radiologa. Usefulness of ultrasonography in children with right iliac fossa pain. 2012;54(2):137-148
- 39 Puylaert J. Ultrasonography of the acute abdomen: gastrointestinal conditions. *Radiol Clin North Am.* 2003;41: 1227-42.



- 40 Gaensler,R, Erik H.L. Brooke Jeffrey, Jr. Faye C Laing, Ronald R Townsend; Sonography In Patients With Suspected Acute Appendicitis: value in establishing alternative diagnoses; AJR 1989; 152:49-51.
- 41 Ooms HWA, Koumans RKJ, Ho Kang Yu PJ, Puylaert JBCM, Ultrasound in the diagnosis of acute appendicitis. Br J Surg 1991; 78:315-18.
- 42 Abu-Yousef MM. Ultrasonography Of Right Lower Quadrant. Ultrasound Quarterly 2001;17(4):221-5.
- 43 George MJ, Siba PP, Charan PK, Rao RRM. Evaluation of Ultrasonography as a useful Diagnostic Aid in Appendicitis. Indian J Surg. 2002; 64: 436-9.
- 44 Peletti A, Baldisserotto M. Optimizing US examination to detect the normal and abnormal appendix in children. Pediatr Radiol. 2006;36:1171--6.
- 45 Birnbaum BA, Wilson SR. Appendicitis at the millennium. Radiology 2000; 215: 349-352.
- 46 Doria AS. Optimizing the role of imaging in appendicitis. Pediatr Radiol 2009; 39 (Suppl 2):S144-S148.
- 47 Poortman P, Oostvogel HJ, Bosma E et al. Improving diagnosis of acute appendicitis. J Am Coll Surg 2009; 208: 434-41.
- 48 Parks NA, Schroepel TJ. Update on imaging for acute appendicitis. Surg Clin North Am 2011; 91: 141-54.
- 49 Lewis FB, Holcroft JW, Boey J, Dumphy E A Critical Review Of Diagnosis and Treatment In 1000 Cases, Arch Of Sur, 1975; 110:677-84.
- 50 Addiss DG, Shaffer N, Fowler BS, Tauxe RV. The epidemiology of ppendicitis and appendectomy in the United States. Am J Epidemiology 1990;132:910-25.
- 51 Tauro Lf, Premanand T S, Aithala P S, George C, Suresh H B, Acharya D, John P. Ultrasonography Is Still A Useful Diagnostic Tool In Acute Appendicitis, Journal of Clinical and Diagnostic Research 2009 Oct; 3:1731-36.
- 52 Sohail et al. Doptaus – a simple criterion for improving sonographic diagnosis of acute appendicitis J Pak Med Assoc 2009; 59: 79-82.
- 53 Thomas Rettenbacher, AloisHollerweger, Peter Macheiner, Lukas Rettenbacher, Robert Frass, Barbara Schneider, et al presence or absence of gas in the appendix: additional criteria to rule out or confirm acute appendicitis-evaluationwithultrasound, Radiology 2000; 214:183-7.
- 54 Puylaert J. Acute appendicitis: US evaluation using graded compression. Radiology 1986; 158:355-60..
- 55 Jeffery RB Jr, Laing FC, Townsend RR. Acute appendicitis: sonographic criteria based on 250 patients. Radiology 1988;167:327-9.
- 56 Michel RiouxSonographic Detection Of The Normal And Abnormal Appendix, AJR 1992; 158: 773-8
- 57 Lee JH, Jeong YK, Park KB, Park JK, Jeong AK, Hwang JC. Operator dependent techniques for graded compression son ography to detect the appendix and diagnose acute appendicitis, AJR. 2005 Jan; 184(1): 91-7
- 58 Grebeldinger S. Ultrasonographic diagnosis of acute appendicitis. Med. Pregl. 1996; 49:487-91.
- 59 Skanne P, Amland P.F., Nordshus T. et al. Ultrasonography in patients 38 ith suspected acute appendicitis. A prospective study. Br. Jr. Radiol, 1990; 63:787-93.
- 60 Hahn HB, Hoepner FU., Kalle T et al. Sonography of acute appendicitis in children: 7 years experience. Paediatr. Radiol 1998; 28:147-51.
- 61 Tarjan Z., Mako E., Winternitz T., et al. The value of ultrasonic diagnosis in acute appendicitis. Orv. Hetil. 1995; 136:713-7.
- 62 Puylaert JB. A prospective study of Ultrasonography in diagnosis of acute appendicitis. NEJM, 1987; 317:666-9.
- 63 Joshi HM, Patel VB, Dave AN, Ultrasonographic Evaluation Of AcuteAppendicitis, Ind J RadiolImag, 1996; 2:75-8.
- 64 Nicolas Kessler, MD Catherine Cyteval, MD, PhD Benoi'tGallix, MD, PhD AlvianLesnik, MD Paul-Marie Blayac, MD Joseph Pujol, MD Jean-Michel Bruel, MD Patrice Taourel, MD, PhD Appendicitis: evaluation of sensitivity, specificity, and predictive values of US, Doppler US and laboratory findings Radiology 2004; 230:472-8.
- 65 Matteo Baldisserotto, Edson Marclniosi, accuracy of noncompressive Sonography of children according to the potential positions of the appendix, AJR 2000;175:1387-92.
- 66 Ida Chan, Simon G. Bicknell, Mary Graham, Utility and Diagnostic Accuracy of Sonography in Detecting Appendicitis in a Community HospitalAJR 2005;184:1809-12
- 67 Wolf B. Schwerk, Britta Wichtrup, Matthias Rothmund, Joseph Ruschoff, Ultrasonograpy In The Diagnosis Of Acute Appendicitis: A Prospective Study, Gastroenterology Sept 1989: 630-9.
- 68 Yacoe ME, Jeffrey B Jr Sonography of appendicitis and Diverticulitis RadiolClin N Am 1994; 32:899-912