

Excess Consumption Effects of Aqueous Extract of Piper Guineense Fruits on the Lungs of Adult Female Wistar Rats

Akudike Chijioko Jesse^{1*} Ezejindu Damian Nnabuihe¹ Eze Uche Jones¹ Ndukwe GU²
Ezejindu Cosmas Nnadozie³

1. Department of Anatomy, Faculty of Basic Medical Sciences, College of Health Science, Nnamdi Azikiwe University, Nnewi Campus, Nigeria

2. Department of Anatomy, Faculty of Basic Medical Sciences, Abia State University Uturu, Abia State, Nigeria

³Department of Microbiology, Abia State University Uturu, Abia State, Nigeria

Abstract

The present study was undertaken to investigate the excess consumption effect of aqueous extract of *Piper guineense* fruits on the lungs of adult female wistar rats. *Piper guineense* popularly known as West African black pepper, in ancient times has been known to possess a whole lot of medicinal values and also a good contractile effect on the uterus of post-natal mothers. In this experiment, twenty virgin adult female wistar rats were grouped into four of five animals each. Group 1 was the control group, group 2 were treated with 1000mg/kg of *Piper guineense* extract, group 3 were treated with 1500mg/kg of the extract and the group 5 were treated with 2000mg/kg of the extract all for a period of twenty-eight days. After the last administration, the animals were sacrificed and the lungs harvested for histological processing and analysis. The results from the histological analysis of this experiment exhibited extensive oedema with coalition of some of the alveolar spaces which were increasing as the experimental doses were increased. It can be concluded from this study that excessive consumption of *Piper guineense* fruits could cause serious damages to the lungs. Therefore this study suggests that although *Piper guineense* is truly medicinal, the consumption should be moderate and well regulated so as to prevent some damages to the lungs.

Keywords: Consumption, Lungs, *Piper guineense*, Wistar rats.

1. Introduction.

In ancient times and till date, many traditional agricultural societies rely on edible plants to provide important energy and micronutrients (Grivetti and Ogle, 2000). A type of such edible plant is the spice called *Piper guineense*.

Piper guineense is a plant that has edible leaves and seeds, it is traditionally known as “uziza”, “iyere” and “masoro” in Igbo, Yoruba and Hausa languages in Nigeria and West African black pepper. It belongs to the family *Piperaceae* with over 700 species around the world mainly in tropical and sub-tropical regions of the world (Olonisakin *et al.*, 2006) and climbs up to 12m high by its adventitious rootlets (Busia, 2007). The fresh fruits of this plant are drupe mesocarp with an oval shape and the mature ones appear black in colour. The plant has been found to have a range of effects ranging from antioxidant effects (Adegoke *et al.*, 1999), antimicrobial (Davidson, 1997; Ahn *et al.*, 2007), antibacterial (Nwinyi *et al.*, 2009), tocolytic (Williams *et al.*, 2013), hepatoprotective effects (Nwozo *et al.*, 2012) and increasing uterine muscle contractions (Udoh, 1999) and therefore could also be included in our daily diets (Echo *et al.*, 2012). Studies on the dose related effect of aqueous extract of the seeds of *Piper guineense* on the livers and kidneys of wistar rats revealed that there were some pathological differences in the tissues of the organs causing increasing hepatic and renal toxicities with increasing doses in the animals (Ebeye *et al.*, 2007). Other studies on the short and long term oral administration of the aqueous extract of *Piper guineense* showed a significant increase in body weights, values of red and white blood cells, packed cell volumes and mean corpuscular haemoglobin concentrations which are dependent on the duration of the treatments (Hassan *et al.*, 2010).

The lungs begin to develop as a respiratory diverticulum (lung bud) at approximately 4 weeks and can produce adequate gas exchange at the end of the 7th month intrauterine (Sadler, 2012). The lungs lie within the thoracic cavity surrounded by visceral layer of the pleura with the right lung having three lobes and the left lung has two lobes (Sinnatamby, 2011).

This study therefore was taken to determine the excess consumption effect of aqueous extract of *Piper guineense* fruits on the lungs of adult female wistar rats.

2. Materials and Method

2.1. Plant Collection and Identification

The plant specimens were purchased at a local market called Nkwo-Nnewi, Nnewi in the month of July, 2015. They were properly identified by a botanist at the Department of Botany, Faculty of Biosciences, Nnamdi Azikiwe University, Awka.

2.2. Preparation of Extracts

The fruits were first dried by sun-drying method for a period of fourteen days¹⁶, weighing about 310grams. The dried specimens were then ground to fine powder with the aid of a milling machine; the fine powder was then sieved through a no. 20 mesh-sized sieve and put in distilled water for a period of 72 hours. The solution was then filtered through with a parceling cloth and the filtrate put in a water bath at 50°C to concentrate.

2.3. Animals and Experimental Protocol

20 adult female wistar rats weighing between 139-147 grams were used for the experiment. They were housed in 4 big meshed cages under standard environmental conditions. Animals were given top feeds grower mash super-deluxe animal feed produced by Eastern Premier Feed Mills Ltd, a subsidiary of Premier Feeds Mills Co. Ltd, Plateau state and water freely. All procedures and protocols were approved by the Ethical committee of the Faculty of Basic Medical Sciences, College of Health Sciences, Nnamdi Azikiwe University, Nnewi campus and were strictly adhered to.

The animals before commencement of extract administration were properly weighed using an Electronic kitchen scale (SF-400) which has a capacity of 7,000grams and then the extract administration commenced.

The animals were then given the extract through the following protocols for 28 days respectively:

Group 1 served as the control group and fed with water and feed only.

Group 2 received 1000mg/kg body weight of the extract daily.

Group 3 received 1500mg/kg body weight of the extract daily.

Group 4 received 2000mg/kg body weight of the extract daily.

These extracts were always administered every evening and the animals were observed every three hours except at nights.

2.4. Tissue Processing

The tissues were processed according to standard procedures for easy study and understanding under the compound light microscope, the liver fixation was done in 10% formal saline for 2 hours to preserve its tissue and cellular components, they were then dehydrated in ascending grades of alcohol of 50%, 70%, 90% and 100% (absolute alcohol) for 2 hours each before then being cleared in three changes of xylene for a period of 1 hour 30 minutes to remove the alcohol from the tissue being processed. The xylene was then removed and substituted by the molten paraffin maintained at a temperature of 3-5°C above the melting point of the paraffin wax used, afterwards the infiltrated tissues were placed into embedding moulds containing molten paraffin wax and during this procedure, tissues were oriented into proper position after which were allowed to cool and solidify before being transferred into a bath of ice block for easy detachment of the mould made from the embedded cassette. The mould containing the liver was then mounted and trimmed to remove excess wax, before then sectioned first to 15 microns and later 4 microns with the aid of a rotatory microtome. The tissue sections were deparaffinised in 20% alcohol and hydrated in a water bath preheated to about 45°C before being allowed to dry on clean slides, the slides were dried on a hot plate at 5°C for adherence of the tissue. The sectioned tissue slide was stained using haematoxylin and eosin staining techniques for general tissue structure to give its characteristic colour before being mounted using the Dibutylphthalate Polystyrene Xylene mountant and finally covered with cover slip before viewing under the compound light microscope.

2.5. Statistical Analysis

This was carried out using the one way ANOVA test by the statistical package for social sciences (SPSS) 16.0 software package with the level of significance at 0.05 ($p < 0.05$).

3. Results and Discussion

The results obtained from this experiment are as follows:

3.1. Physical and Behavioural Observations

By the 2nd week, there was sneezing within the experimental groups.

By the 3rd week, there were clear coloured and slimy liquids coming out of the animals' noses as well as sluggish and staggering movements among animals of the experimental groups.

By the 4th week, the slimy liquids were coming out more.

3.2. Body Weights Analysis

Table 1: Shows the summary of the mean body weights of the different groups

	GROUP 1 (Control)	GROUP 2 (1000mg/kg)	GROUP 3 (1500mg/kg)	GROUP 4 (2000mg/kg)
INITIAL WEIGHT	139.33±2.08	143.33±0.58	145.67±3.05	148.33±0.58
P-VALUE		0.019	0.001	0.000
2 WEEKS WEIGHT	150.33±1.53	147.67±0.58	149.67±2.08	151.00±0.00
P-VALUE		0.022	0.515	0.515
FINAL WEIGHT	153.67±1.53	145.33±1.16	145.67±1.16	143.67±0.58
P-VALUE		0.000	0.000	0.000

The mean weights of the animals were analysed and showed that there was an insignificant increase in the body weights of animals of experimental groups after 2 weeks of administration and a significant decrease in body weights of the animals of the experimental groups at the end of the 4th week of the experiment when comparing their initial and final weights to those of the control group.

3.3. Histological Analysis

The following pictorial results were obtained after histological processing of the tissues respectively

Group 1 (control):

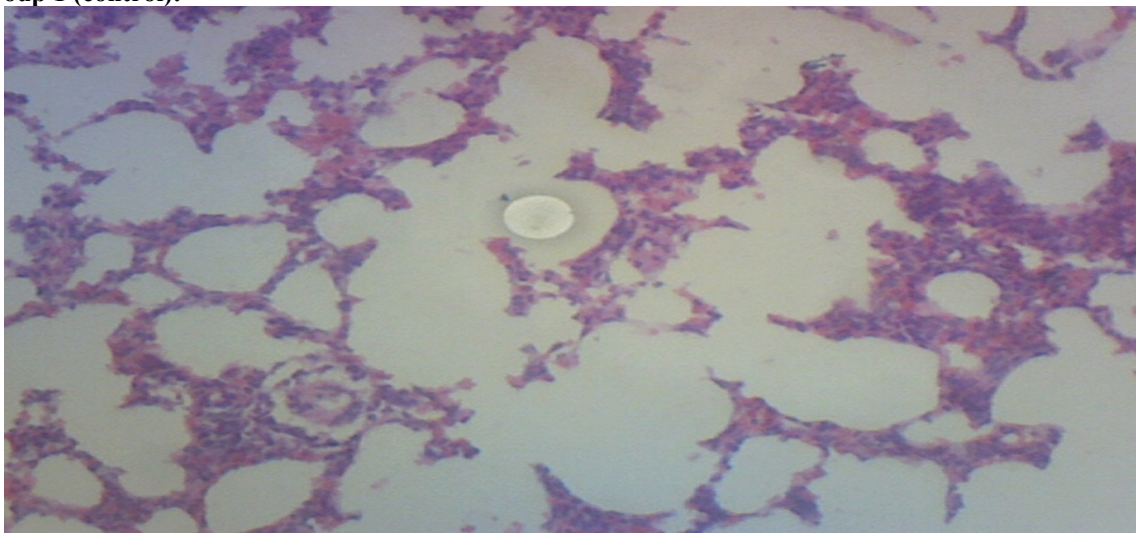


Fig. 1: Shows normal lung tissue and normal alveolar wall (H & E) × 60.

Group 2 (1000mg/kg):

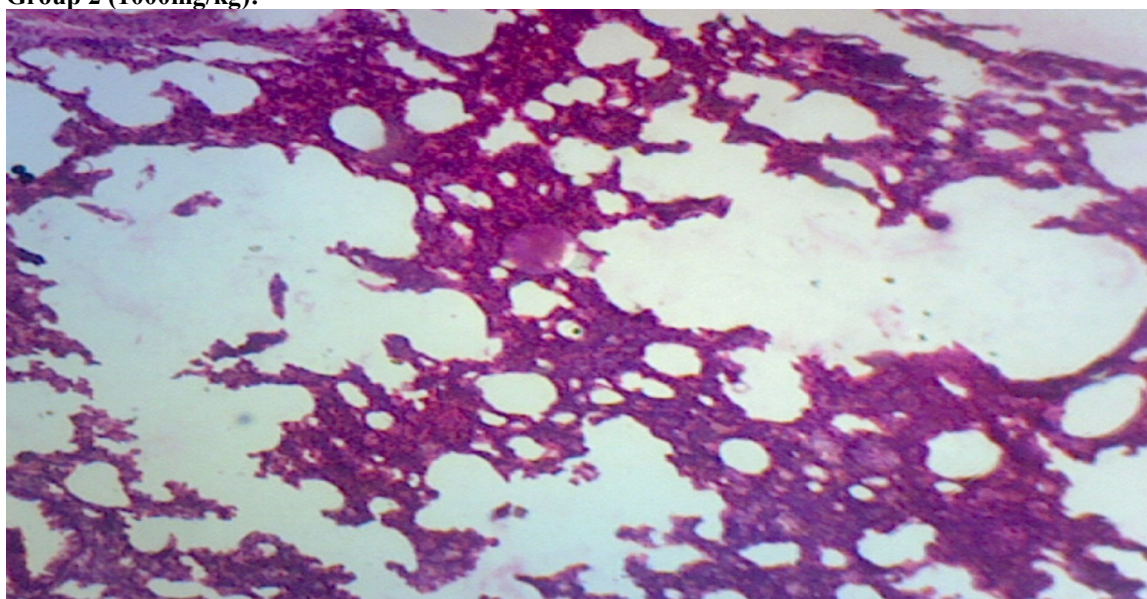


Fig. 2: Shows mild to moderate oedema with mild destruction of alveolar wall (H & E) × 60.

Group 3 (1500mg/kg):

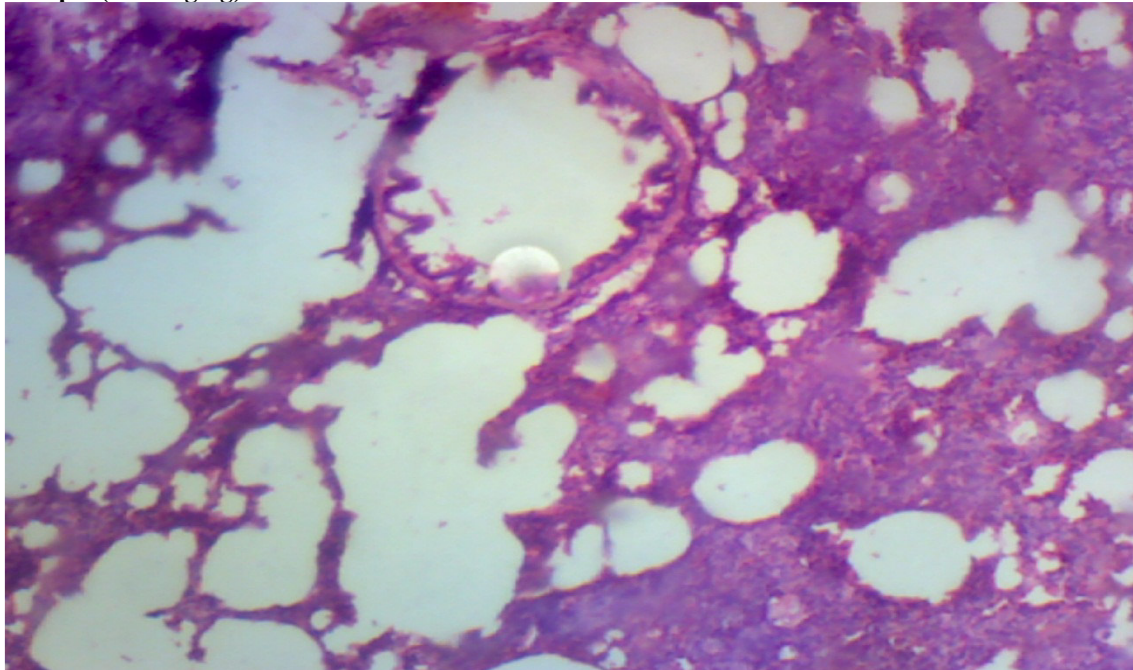


Fig. 3: Shows moderate oedema as well as moderate destruction of alveolar wall (H & E) \times 60.

Group 4 (2000mg/kg):

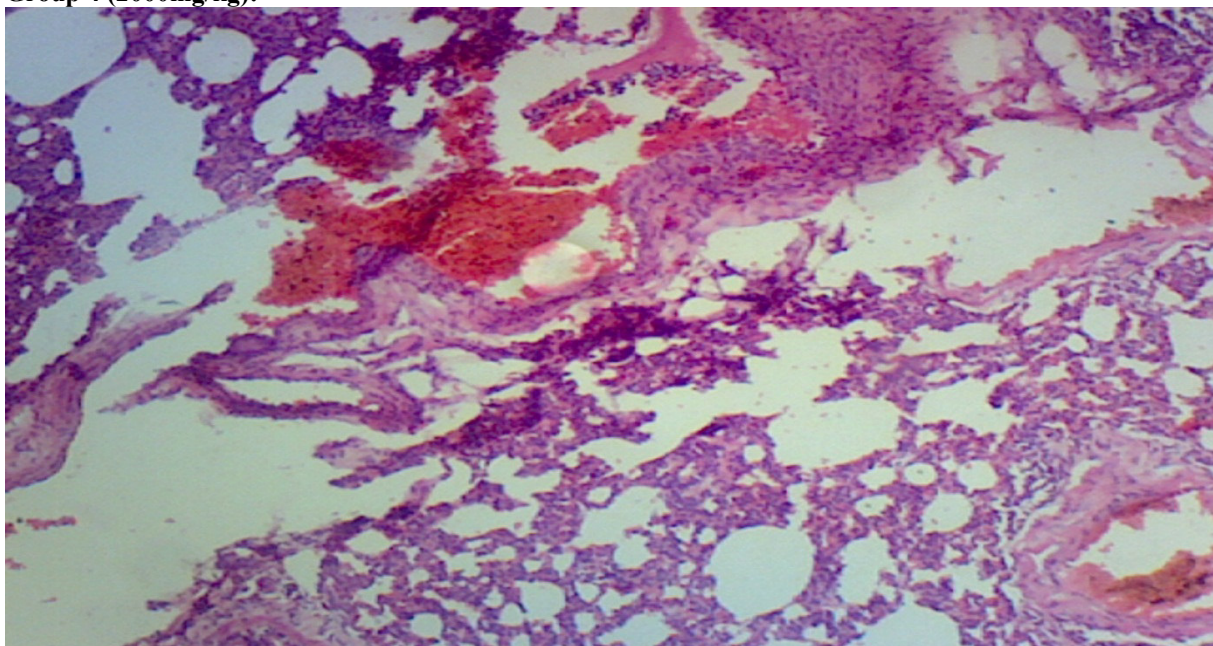


Fig. 4: Shows moderate oedema, moderate destruction of alveolar walls and intrapulmonary haemorrhages (H & E) \times 60.

The lungs are the centre for gaseous exchange that must be protected from any form of harm. A lot of materials could pose risks to the lungs some of which could affect the alveolar walls and spaces.

In this study, the results show that excess consumption of *Piper guineense* continuously produced slimy liquids from the nose. Also, *Piper guineense* at high doses caused a decrease in the body weights of the animals. It also caused formation of edema which could be mild to moderate. It also caused mild to moderate destruction of the alveolar walls septa leading to destruction and coalition of alveolar spaces. The results also showed that there were congestions of the pulmonary vessels causing intrapulmonary haemorrhages.

4. Conclusion

It can be concluded from this study that the excess consumption of *Piper guineense* fruits at high doses could really affect the entire histological structure of the lungs, thus reducing rate of gaseous exchange and the lungs

functionality. As such, agencies should advise against the excess consumption of the plant as it could affect not only the lungs but also other organs of the body but advocate that its use be regulated properly over a period of time of use.

References

1. Grivetti L.E and Ogle B.M. (2000). Value of Traditional Foods in Meeting Macro and Micronutrients Needs: the Wild Plant Connection. *Nutrition Research Reviews*. 13 (1): 31-46.
2. Olonisakin A, Oladimeji M.O and Lajide L. (2006). Chemical Composition and Antibacterial Activity of Steam Distilled Oil of Ashanti Pepper (*Piper guineense*) Fruits (Berries). *Electron J. Environ. Agric Food Chem*. 5 (5): 1531-1535.
3. Busia K (2007). In: Adosraku R.K, Kyekyeku J.O and Attah I.Y. Characterization and HPLC Quantification of Piperine Isolated from *Piper guineense* (Fam. *Piperaceae*). *International Journal of Pharmacy and Pharmaceutical Sciences*. 5 (1): 252-256.
4. Adegoke G.O, Skura B.J and Mustapha A. (1999). Effect of Concentration of Extract, Heat, Temperature of Incubation and pH on the Inhibition of *Staphylococcus aureus* by the spice *Aframomum danielli* K. Schum. *Nig. J. Sci*. 33: 61-66.
5. Davidson P.M (1997). In: Doyle M.P, Beuchat L.R, Montville T.J. In: Dada A.A, Ifesan B.O.T and Fashakin J.F. Antimicrobial and Antioxidant Properties of Selected Local Spices used in “Kunun” Beverage in Nigeria. *Acta Sci. Pol, Technol. Aliment*. 2013; 12 (4): 373-378.
6. Ahn J, Grun I.U and Mustapha A. (2007). Effects of Plant Extracts on Microbial Growth, Colour Change and Lipid Oxidation in Cooked Beef. *Food Micro*. 24: 7-14.
7. Nwinyi O.C, Chinedu N.S, Ajani O.O, Ikpo C.O and Ogunniran K.O. (2009). Antibacterial Effects of Extracts of *Ocimum gratissimum* and *Piper guineense* on *Escherichia coli* and *Staphylococcus aureus*. *African Journal of Food Science*. 3 (1): 22-25.
8. Williams F.E, Obianwu H, Adedeji O.S and Oyewepo A.O. (2013). In Vitro Tocolytic Effects of the Glycosidic Constituents of the Fruits of *Piper guineense*. *Biokemistri*. 25 (2): 92-95.
9. Nwozo S.O, Ajagbe A.A and Oyinloye B.E. (2012). Hepatoprotective Effect of *Piper guineense* Aqueous Extract Against Ethanol-Induced Toxicity in Male Rats. *Journal of Experimental and Integrative Medicine*. 2 (1): 71-76.
10. Udoh F.V (1999). In: Udoh F.V, Ekanem A.P and Eyo V.O. Pharmacodynamic Effect of Methanolic Extract of *Piper guineense* Leaf on Uterine Physiology. *Pharmacologia*. 3 (7): 200-203.
11. Echo I.A, Osuagwu A.N, Agbor R.B, Okpako E.C and Ekanem B.E. (2012). Phytochemical Composition of *Aframomum melegueta* and *Piper guineense* Seeds. *World Journal of Applied Environmental Chemistry*. 2 (1): 17-21.
12. Ebeye O.A, Emore E, Enaibe B.U and Igbigbi P.S. (2007). Hispathological Effect of *Piper guineense* Extract on Wistar Rats. *Journal of Biological Sciences*. 7: 1484-1487.
13. Hassan D.I, Ogah D.M, Yusuf N.D, Musa M.M and Saidu G.M. (2010). The Effect of Acute and Chronic (short and long term) Oral Administrations of Black Pepper (*Piper guineense*) Aqueous extract on the Body Weight and Haematological Values of Albino-Wistar Rat. *Journal of Medicinal Plants Research*. 4 (12): 1122-1125.
14. Sadler T.W. (2012). *Langman’s Medical Embryology*. 12th Edition. Wolters Kluwer|Lippincott Williams & Wilkins, China. Pp: 201 & 205.
15. Sinnatamby C.S. (2011). *Last’s Anatomy: Regional and Applied*. 12th Edition. Elsevier Ltd, China. Pp: 213.
16. Omafuvbe B.O and Kolawole D.O. (2004). Quality Assurance of Stored Pepper (*Piper guineense*) Using Controlled Processing Methods. *Pakistan Journal of Nutrition*. 3 (4): 244-249.