

# Does Sweet Pausinystalia Yohimbe Affect Reproductive Hormones, Accessory Glands and Sperm in Rats?

Louis Chukwuemeka Ajonuma<sup>1\*</sup> Eniola Carew<sup>1</sup> Misturah Salami<sup>1</sup> Adebisi Saka Bamiro<sup>1</sup>  
Grace Adeyemi Umoren<sup>1</sup> Innocent Ikechukwu Okoye<sup>1</sup> Basil Chinedu Bonaventure<sup>1</sup>  
Samira Lobo Makonjuola<sup>2</sup>

1.Department of Physiology, Lagos State University College of Medicine, Ikeja, Lagos, Nigeria

2.Department of Pharmacology, Lagos State University College of Medicine, Ikeja, Lagos, Nigeria

## Abstract

Sweet Pausinystalia yohimbe (Sweet *P. yohimbe*) is popularly known for its aphrodisiac actions and widely used for the treatment of erectile dysfunctions in the sub-Saharan region of Africa. However, little is known of its effects on reproductive hormones and sperm production. Therefore, this study investigated the effects of Sweet *P. yohimbe* on reproductive steroid hormones, male accessory glands and sperm in the rat. Seventeen adult male Sprague-Dawley (SD) rats were divided into three groups. Group A (control group) had 5 rats and received 0.5ml of normal saline, while groups B and C (test groups) had 6 rats each and received 150mg/kg and 300mg/kg body weights of aqueous extract of Sweet *P. yohimbe* respectively via oral gavages daily for 4 weeks. The rats were weighed prior to Sweet *P. yohimbe* treatment and just before sacrifice. Tissues obtained (testes, prostate and seminal vesicles) were used for histological studies and sera for hormonal measurements. Sperm concentration, motility and vitality were also determined using sperm from the caudal epididymis and vas deference. There was a statistical significant reduction in bodyweights in test groups but none in the organ body weight ratio. There were significantly decreased sperm concentrations and motility in tests groups while vitality was normal amongst all groups. Head to head sperm agglutination was also seen in the tests groups. A dose dependent decrease in the testosterone/estradiol ratio was observed. Cell destruction, epithelial thinning and pseudostratification were also seen in the testes, prostate and seminal vesicles. Sweet *P. yohimbe* has a dose dependent effect on reproductive steroid hormones, sperm concentration and motility as well as male accessory glands in rats as seen in this study. This may impair reproductive functions and fertility.

**Keywords:** Accessory glands, Rats, Sweet *Pausinystalia yohimbe*, Reproductive hormones, Sperm motility, Sperm concentration

## 1.0 Introduction

The use of herbal preparations has been in existence for decades and has been proven to be beneficial long before the use of orthodox therapies. Sweet Pausinystalia yohimbe (Sweet *P. yohimbe*) is popularly known for its effective aphrodisiac actions and widely used for the treatment of erectile dysfunctions in the sub-Saharan region of Africa including Saudi Arabia and Middle East region where it grows in the wild (Sunderland *et al.*, 1997, Eweka *et al.*, 2010, Etiani, 2012).

The extracts of Pausinystalia yohimbe contain the alkaloid yohimbine an alpha-<sub>2</sub> antagonist that has been widely used with variable success in treating erectile dysfunction (Ajayi *et al.*, 2003). It has a more recent history of use as aphrodisiac and as a hallucinogen, and helps to heighten the sense of touch and send tickling sensation up and down the spine (Sahelian, 2010; Etiani, 2012).

The amount of alkaloid activity in *P. yohimbe* bark is highly variable (Adeniyi *et al.*, 2007). The exact concentration of Yohimbine in Sweet *P. yohimbe* is not known. Yohimbine is sympatolytic and has a local anesthetic action similar to that of cocaine (Anderson, 2001). The vasodilating action of Yohimbine is particularly strong on the sex organ hence, its aphrodisiac action (Adeniyi *et al.*, 2007).

Herbal preparation with respect to reproductive activity is however important due to its relation to fertility. Various nations, tribes and people use different herbal preparations as aphrodisiacs in order to enhance their sexual performances. Although Sweet *P. yohimbe* has been used for the treatment of erectile dysfunctions, its effect on male reproduction is not well defined and has not been properly studied to any reasonable extent. Therefore, the objectives of this study are to investigate the effects of Sweet *P. yohimbe* on reproductive steroid hormones, male accessory glands and sperm in the rat.

## 2.0 Materials and Methods

### 2.1 Animals

Seventeen healthy, adult Sprague-Dawley (SD) male rats, weighing 165-300g, were obtained from the animal house unit of the Babcock University, Ilishan, Ogun State, and housed in the Animal House Unit of the Lagos State University College of Medicine Ikeja, Lagos, Nigeria for two weeks to acclimatize prior to the study. The rats were fed with standard rat chow purchased from Agege Livestock Feed Mills, Agege, Lagos, Nigeria and water was provided *ad libitum*. The rats were strictly exposed to 12 hours of dark/light cycle. This study was

done according to the regulations of the use of animals in experiments of Animal House Unit, Lagos State University College of Medicine, Ikeja, Lagos, Nigeria.

## 2.2 Sweet *P. yohimbe* and Preparation of extract

Dried stems of Sweet *P. yohimbe* used in this study were purchased from a known local herbal merchant from Ikeja, Lagos, Nigeria. The stems were taken to two other herbal merchants one at Mosalasi Alhaja in Agege, Lagos, and the other located at Alabarago along Badagry express road Ojo, Lagos, and the merchants identified the stems as Sweet *P. yohimbe* "Dan Medina" from Saudi Arabia.

The stems of the Sweet *P. yohimbe* were chopped into small pieces, pounded in a wooden mortar with pistil and then blended with Electric Blender (Panasonic, MX-AC300) into a fine smooth Sweet *P. yohimbe* powder (SPP). Crude extraction has been previously described (Bordbar *et al.*, 2013; Etiani, 2012). In brief, 50g of SPP was boiled in 1litre of distilled water in a beaker on a hot plate with a magnetic stirrer (JOANLAB, Model: SH-4) for 90mins at a temperature of 120 °C, after which the boiled extract was allowed to cool, and then it was sieved and then placed in the oven at about 100 °C to dry. The oven dried extract was named Sweet *P. yohimbe* extract (SPE). SPE was weighed indicating that 50g of SPP yielded 16g of SPE.

## 2.3 Experimental Design

The experimental animals were randomly divided into 3 groups. Group A (control group) had 5 rats and received 0.5mls. of normal saline, while groups B and C (test groups) had 6 rats each and received 150mg/kg and 300mg/kg body weights of aqueous extract of SPE respectively via oral gavages daily for 4weeks. The concentration of SPE to be given was determined by dissolving 16g of SPE into 320mls of distilled water, and allowed to dissolve (Bordbar *et al.*, 2013; Etiani, 2012). The concentration was determined as 50mg/ml. SPE was then administered to each of the animals according to their weight using this formula

$$\frac{\text{weight} \times \text{dose}}{\text{concentration}} = \text{dose for each animal}$$

The diluted SPE was then termed Sweet *P. yohimbe* aqueous extract (SPAЕ).The rats were administered SPAЕ daily through oral gavages for a period of 4weeks.

After 4 weeks of administration, the rats were anaesthetized using Ketamine HCL, and were dissected open; blood samples were collected via cardiac puncture and the blood samples were stored in plain sample bottles. The following reproductive organs were obtained, the testes, seminal vesicles, prostate, and were weighed and fixed in 10% formalin for histology and epididymis for sperm analysis.

## 2.4 Serum Preparation

The collected blood samples were allowed to clot. The samples were then placed in a table top centrifuge (Surgifield, SM80-2, England) and were spurned for 20mins at 3000 rpm. The separated serum samples were collected into clean sterile sample bottles and stored at -20°C until analyzed.

## 2.5 Measurement of sperm motility

### 2.5.1 Sperm collection and motility analysis

The epididymides of the anaesthetized rats were also obtained and fatty tissues removed. Caudal epididymis and vas deferens were minced into a sample bottle and mixed with 50µl of sperm washing medium supplemented with HEPES (Ajonuma *et al.*, 2003) to enable the sperm cells swim out and the temperature was maintained at 37 °C. For motility assessment, 10µl of sperm washing medium was obtained using sterilized pipettes and then placed on glass microscopic slides and then observed under the microscope (Olympus, XSZ-107BN, Japan) at × 400 magnifications, and at least 100 spermatozoa in a total of 5 fields were evaluated.

A simple system for grading motility by WHO (2010) was used to distinguish spermatozoa with progressive or non-progressive motility from those that are immotile. Progressive motility (PR): spermatozoa moving actively, either linearly or in a large circle, regardless of speed. Non-progressive motility (NP): all other patterns of motility with an absence of progression, e.g. swimming in small circles, the flagella force hardly displacing the head, or when only the flagella beat can be observed. Immotility (IM): no movement. Assessment of only progressive motility (PR) was regarded to be motile and was scored as the percentage motile sperms (WHO, 2010).

### 2.5.2 Sperm Concentration

This parameter was checked using the improved Neubauer haemocytometer; this has two separate counting chambers, each with a microscopic pattern of gridlines etched on the glass surface. It was used with its special thick cover-slip which was used to cover the grids. The dilution of spermatozoa and sperm diluents was 1+9 (1:20), this ratio requires counting of only the middle grid (grid number 5), and rows from grid number 5 were assessed. 50µl of sperms from the sperms mixed with sperm washing medium was obtained using a pipette into a sample bottle and 950µl of sperm diluents was obtained using pipette into the sample bottle of the obtained 50µl

of sperms cells using 1:20, and then 10 $\mu$ l was obtained using pipettes into both the upper and lower chambers of the haemocytometer, and covered with cover-slips to avoid drying up of the sample being checked under the microscope, assessment is done through counting of calibrated boxes seen under the microscope, 5 boxes were counted both in the upper and lower chambers of the Neubauer counter for accuracy as instructed by WHO, (2010).

### 2.5.3 Sperm Vitality

Sperm vitality was assessed as previously described WHO, (2010). Vitality test using eosin alone was done. The spermatozoa mixed with the sperm washing medium were kept at a temperature of 37 °C. 5 $\mu$ l of sperm in sperm washing medium was obtained using sterilized pipettes and mixed thoroughly with equal amount of eosin dye on a microscopic slide, and covered with a 22mm  $\times$  22mm cover-slip then left for 30seconds. The slide was observed under a simple light microscope at  $\times$ 400 magnification. (Olympus, XSZ-107BN, Japan) Live spermatozoa having white heads were scored and considered to be live and those that stain dark pink to red on the head are considered dead (WHO 2010).

### 2.6 Hormones Measurement

Hormones measurement was done using enzyme linked immunosorbent assay (ELISA) using Accu-bind Micro wells Estradiol (E2) Test System, Monobind Inc. Lake Forest, CA, USA) according to manufacturers protocol for E2. In brief, reagents and the serum were brought to room temperature (25 °C). 25 $\mu$ l of serum sample was placed into micro plates wells using a pipette. 50 $\mu$ l of E2 enzyme reagent was added to the wells. Then the micro plates were swirled gently for 30 seconds to enable mixing and covered to incubate for 90 minutes at room temperature. The contents of the micro wells were discarded by decanting with absorbent paper. 350 $\mu$ l of wash buffer was added and washing was repeated for three times. 100 $\mu$ l of substrate solution was added to the wells and incubated at room temperature for 20 minutes. 50 $\mu$ l of stop solution was added to each well and was gently mixed for 20 seconds. The solution was read within 30 minutes, and each well was read at 450nm using a reference wavelength of 630nm optical density on a STAT Fax 4700 ELISA microplate reader.

For Follicular Stimulating Hormone (FSH), Luteinizing Hormone (LH) and Testosterone, ELISA was done using substrates and kits from JD Biotech, Taipei, Taiwan according to manufacturers' protocol.

### 2.7 Light microscopy

This was carried out as previously described (Ajonuma et al., 2005). In brief, all collected organs (testis, seminal vesicle and prostate) were cut into small pieces after removal of fatty tissues and fixed in 10% formalin overnight. Tissue samples were dehydrated in graded ethanol and embedded in paraffin wax and processed with KD-TS6A tissue processor. Sections 5 mm thick were cut using a Shandon Finesse Manual Rotary Microtome, model 325, ThermoScientific, and dried onto Superfrost microscope slides (Fisher Scientific, Pittsburgh, PA, USA). For hematoxylin and eosin (H&E) staining, slides were dewaxed in xylene and dehydrated in graded alcohol and stained for light microscopy. Observation was performed under a Novel Optic Binocular microscope, model NLCD-307.

### 2.8 Statistical Analysis

Data are presented as mean and standard error of mean (SEM). Statistical analyses were carried out by Analysis of variance (ANOVA). Multiple comparisons and differences between groups were analyzed using Tukey comparison test.  $P \leq 0.05$  (two-tailed) was considered statistically significant. Analyses were carried out on Graph Pad Prisms (Graph Pad, Inc., San Diego, CA, USA).

## 3. Results

### 3.1 Effects of Sweet *P. yohimbe* on body weights

As shown in Figure 1, there were significant changes in the body weights of rats in the test groups. After four weeks of treatment with Sweet *P. yohimbe*, the control group A was observed to have gained weight (263 $\pm$ 14 from initial body weights of 221 $\pm$ 12) compared to test group B (150mg/kg body weight), 218 $\pm$ 9.5 from initial body weight of 210 $\pm$ 12,  $p=0.0422$ ). Interestingly, group C those that received 300mg/kg body weight of Sweet *P. yohimbe* had weight loss instead of gaining weight after 4 weeks of treatment. They weighed 244 $\pm$ 12 as against initial body weight of 249 $\pm$ 13 grams ( $p=0.0001$ ) compared to the control.

### 3.2 Effects of Sweet *P. yohimbe* on Relative organ weights

After 4 weeks of treatment, the effect of *P. yohimbe* on relative testicular weight was not significant across the test groups compared to the control. Group A (control) (0.01089 $\pm$ 0.0005347), B (150mg/kg) (0.001136 $\pm$ 0.0003947) and C (300mg/kg) (0.01072 $\pm$ 0.0007516).

Similarly, there was no significant increase in the relative prostatic weights. However a dose dependent increase was observed in the test groups compared to the control. Group A (control) (0.001139 $\pm$ 0.00000367),

group B (150mg/kg) (0.0012364±0.0001305), group C (300mg/kg) (0.001423±0.0001831).

No statistical significant difference across the test groups compared to the control in the relative organ/body weights of the seminal vesicles. However, there was a visible increase in group C. Group A (0.002839±0.00005294), B (150mg/mg) (0.002254±0.0003463), C (300mg/kg) (0.00341±0.0005693).

### 3.3 Effects of Sweet *P. yohimbe* on Sperm

#### Sperm Concentration

Figure 2, show that there was a significant decrease in sperm concentration of both test groups compared to the control. Group A (control) (118±16), B (150mg/kg) (38±6.5) (P<0.0001) and C (300mg/kg) (30±4.0) (P<0.0001).

#### Sperm Motility

As shown in Figure 3, there was a significant reduction in the sperm motility of the test groups compared to the control. Group A (control) (99±1.6), B (150mg/kg) (9.3±2.3) (P<0.0001) and C (300mg/kg) (7.7±2.8) (P<0.0001) but the difference between groups B and C was not significant.

#### Sperm Vitality

As shown in Figure 4, there was a small decrease in the sperm vitality of the group C (300mg/kg) that was significant compared to the control. Group A (control) (100±0.0), B (150mg/kg) (99±0.49), C (300mg/kg) (97±0.98) (P=0.0288).

Sever sperm head to head agglutination was also observed in the test groups.

### 3.4 Effects of Sweet *P. yohimbe* on Reproductive Hormones

#### Serum FSH

As shown in Table 2, serum FSH level had no statistical significance and it was seen that FSH level showed the highest rise in the figure among group B (150mg/kg) (9.0±6.9) compared to the control A (3.1±0.97) and C (300mg.kg) (2.7±0.37).

#### Serum LH

The level of serum LH was not statistically significant compared to the control. There was decrease in serum LH level according to the rise in dose of *P. yohimbe* compared to the control A (control) (10±7.4), B (150mg/kg) (3.9±2.8), C (300mg/kg) (1.5±0.62) as shown in Table 2.

#### Serum Testosterone

As shown in Table 2, there was no statistical significance across test group compared to the control, however there was an increase in the testosterone level of B (150mg/kg) (90±49) compared to the control A (75±28) and a decrease in the testosterone level in the (300mg/kg) (46±28) compared to the control.

#### Serum Estradiol

As shown in Table 2, there was no statistical significance across test group compared to the control. However there was an increase in the estradiol levels of group B (150mg/kg) (35±6.5) and a decrease in the levels in the group C (300mg/kg) (24±2.3) compared to the controls group A (18±3.6).

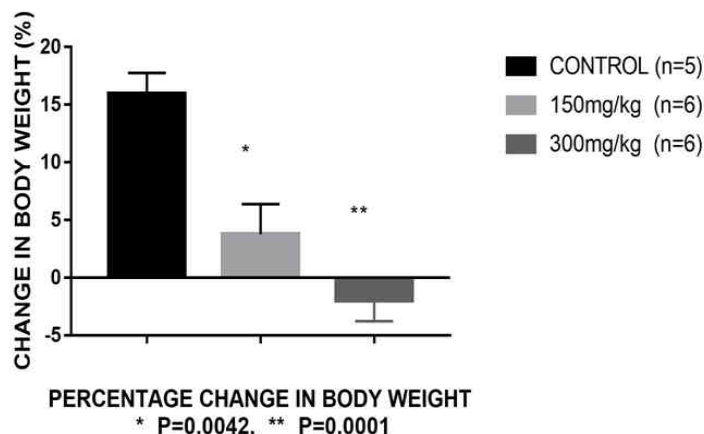
#### Testosterone - Estradiol Ratio

As shown in Figure 5, there was no statistical significance on testosterone estradiol ratio. However, there was a gradual decrease in the testosterone estradiol ratio as *P. yohimbe* dose increased among the groups compared to the control, (control) A (5.2±2.3), B (150mg/kg) (3.0±1.7), C (300mg/kg) (2.0±1.2).

### 3.5 Light microscopy

The effects of Sweet *P. yohimbe* on testes and male accessory glands (prostate, seminal vesicles). In the testes, group A (control) showed normal testicular architecture. Test groups B and C showed the testes undergoing degenerative changes, loss of cellular architecture and decreased spermatozoa in the lumen of the seminiferous tubules (Fig 6). In the prostate, group A (control) showed normal architecture of the prostate, while B and C shows thinning and degeneration of the glandular epithelium, pseudostratification and increased interstitial spaces in the glands (Fig 7). The seminal vesicles control showed normal architecture while test groups B and C shows loss of glandular layers, increased interstitial spaces and thinning of the epithelial layers (Fig 8).

**Figure 1. Effects of Sweet *P. yohimbe* on Rat Body Weights**



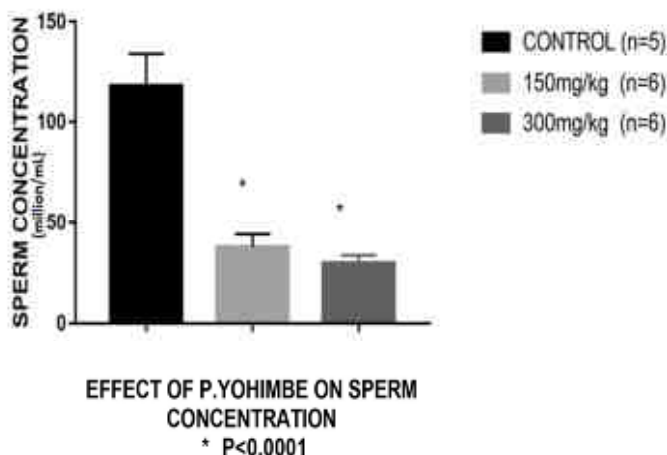
The percentage change in the body weights of rats treated with Sweet *P. yohimbe* for 4 weeks was quite significant across the test groups when compared to the control, A (16±1.8). Group B; (150mg/kg) had a significant decrease in percentage body weight (3.8±2.6) (p=0.0042) and C (300mg/kg) (-2.0±1.8) (p=0.0001) (turkey test) compared to the control. Group A n=5, B n=6, C n=6 respectively.

**Table 1. The Effects of Sweet *P. yohimbe* on Relative Organ Weights**

GROUPS	RELATIVE ORGAN WEIGHTS
	<b>RELATIVE TESTICULAR WEIGHT (x 10<sup>-3</sup>)</b>
A (CONTROL) (n=5)	10.89 ± 0.5347
B (150mg/kg) (n=6)	11.36 ± 0.3947
C (300mg/kg) (n=6)	10.72 ± 0.7516
	<b>RELATIVE PROSTATE WEIGHT (x 10<sup>-3</sup>)</b>
A (CONTROL) (n=5)	11.39 ± 0.00367
B (150mg/kg) (n=6)	12.64 ± 0.1305
C (300mg/kg) (n=6)	14.23 ± 0.1831
	<b>RELATIVE SEMINAL VESICULAR WEIGHT (x 10<sup>-3</sup>)</b>
A (CONTROL) (n=5)	2.839 ± 0.05294
B (150mg/kg) (n=6)	2.254 ± 0.3464
C (300mg/kg) (n=6)	3.41 ± 0.5693

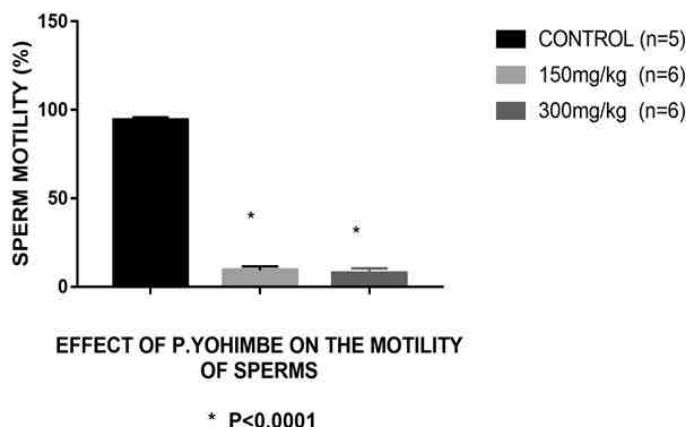
Effects of Sweet *P. yohimbe* on Relative Organ Weights for testes, prostate and seminal vesicles after 4 weeks of treatment. Values are in grams. Group A n=5, B n=6 and C n=6 respectively.

**Figure 2. Effects of Sweet *P. yohimbe* on Sperm Concentration**



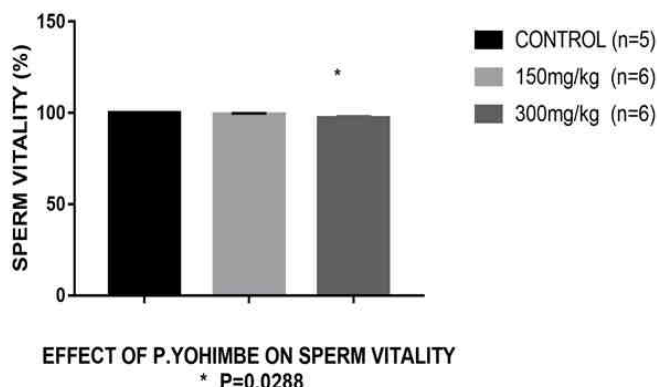
Effects of Sweet *P. yohimbe* on Sperm Concentration after 4 weeks of treatment. There was a significant decrease in sperm concentration for both test groups compared to the control. Group A (control) (118±16), B (150mg/kg) (38±6.5) (\*P<0.0001) and C (300mg/kg) (30±4.0) (\*P<0.0001) (turkey test). Values are in million / ml. Group A n=5, B n=6 and C n=6 respectively.

**Figure 3. Effects of Sweet *P. yohimbe* on Sperm Motility**



Effects of Sweet *P. yohimbe* on Sperm Motility after 4 weeks of treatment. There was a significant reduction in the sperm motility of the test groups when compared to the control. Group A (control) (99±1.6), B (150mg/kg) (9.3±2.3) (\*P<0.0001) and C (300mg/kg) (7.7±2.8) (\*P<0.0001) but no significant difference among test groups (turkey test). Values are in percentage (%). Group A n=5, B n=6 and C n=6 respectively.

**Figure 4. Effects of Sweet *P. yohimbe* on Sperm Vitality**



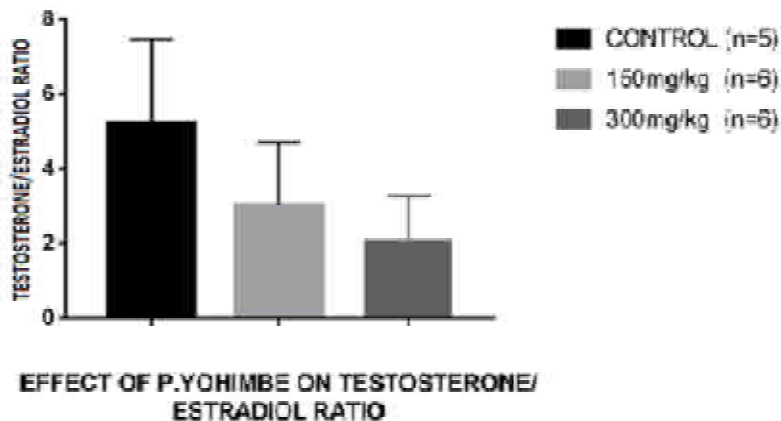
Effects of Sweet *P. yohimbe* on Sperm Vitality after 4 weeks of treatment. There was a significant decrease in the sperm vitality of the group C (300mg/kg) compared to the control, the B (150mg/kg) had to significance compared to the control. A (control) (100±0.0), B (150mg/kg) (99±0.49), C (300mg/kg) (97±0.98) (\*P=0.0288) (turkey test). Values are in percentage (%). Group A n=5, B n=6 and C n=6 respectively.

**Table 2. Effects of Sweet *P. yohimbe* on Serum Hormones**

GROUPS	Serum Hormones
	<b>FSH</b>
A (CONTROL) (n=5)	3.1± 7.4
B (150mg/kg) (n=6)	9.0±6.9
C (300mg/kg) (n=6)	2.7±0.37
	<b>LH</b>
A (CONTROL) (n=5)	10.0±7.4
B (150mg/kg) (n=6)	3.9±2.8
C (300mg/kg) (n=6)	1.5±0.62
	<b>Testosterone</b>
A (CONTROL) (n=5)	75±28
B (150mg/kg) (n=6)	90±49
C (300mg/kg) (n=6)	46±28
	<b>Estrogen</b>
A (CONTROL) (n=5)	18±3.6
B (150mg/kg) (n=6)	35±6.5
C (300mg/kg) (n=6)	24±2.3

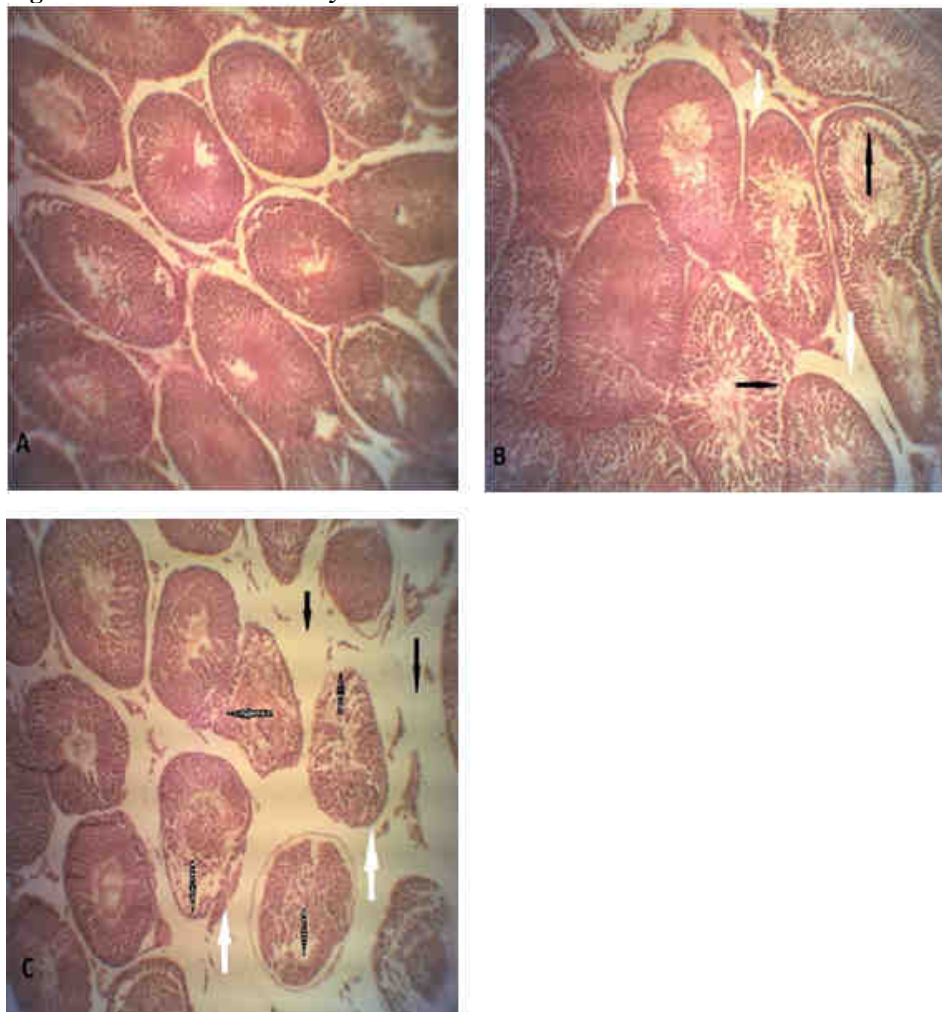
Effects of Sweet *P. yohimbe* on Serum Hormones after 4 weeks of treatment. Serum FSH, LH, Testosterone and Estradiol, were not statistically significant different when compared to the control. Values are

in mIU/L for FSH and LH; nmol./L for Testosterone and Estradiol. Group A n=5, B n=6 and C n=6 respectively.  
**Figure 5. Effects of Sweet *P. yohimbe* on Testosterone / Estradiol Ratio**



Effects of Sweet *P. yohimbe* on Serum Testosterone / Estradiol Ratio after 4 weeks of treatment. There was no statistical significance on testosterone / estradiol ratio. However, there was a gradual dose dependent decrease in the testosterone estradiol ratio among the groups. Group (control) A ( $5.2 \pm 2.3$ ), B (150mg/kg) ( $3.0 \pm 1.7$ ), C (300mg/kg) ( $2.0 \pm 1.2$ ). Values are in nmol./L. Group A n=5, B n=6 and C n=6 respectively. Group A n=5, B n=6 and C n=6 respectively.

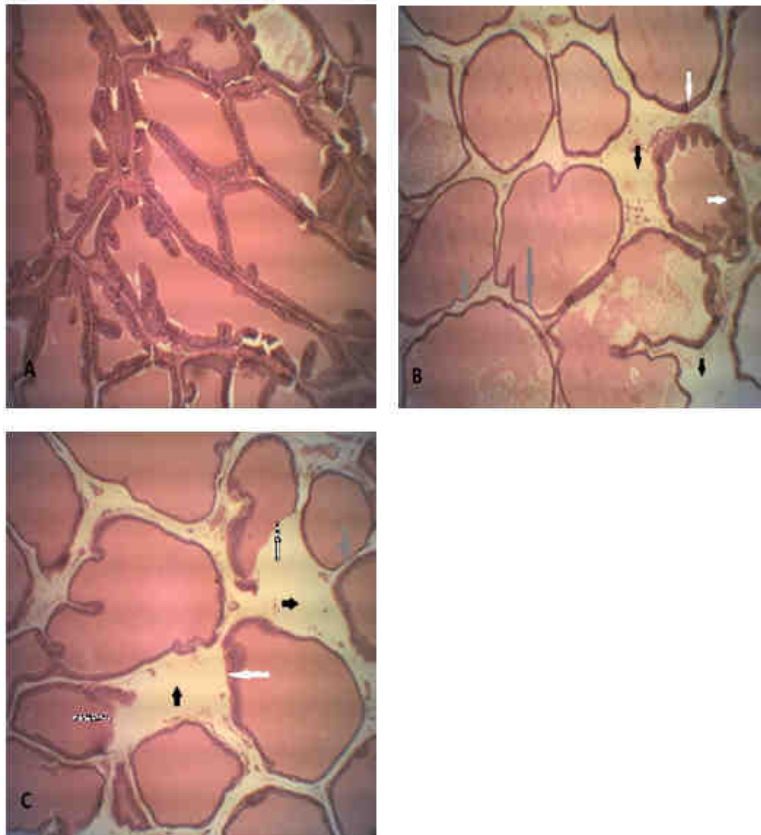
**Figure 6. Effects of Sweet *P. yohimbe* on Testes**



Haematoxylin and eosin (H&E) staining photomicrograph of Sweet *P. yohimbe* treatment after 4 weeks on testes. Group A (control) shows the normal architecture of the testes while B and C (150mg/kg bodyweight and 300mg/kg bodyweight *P. yohimbe* shows the testes are undergoing degenerative changes. White arrows

(detachment of basement membrane), white pigmented arrows (loss of cellular architecture and decreased spermatozoa in the lumen of the somniferous tubules) (Black Arrows in B=loss of cellular architecture, Black Arrows in C= increased interstitial space). Magnification x10. Group A n=5, B n=6 and C n=6 respectively.

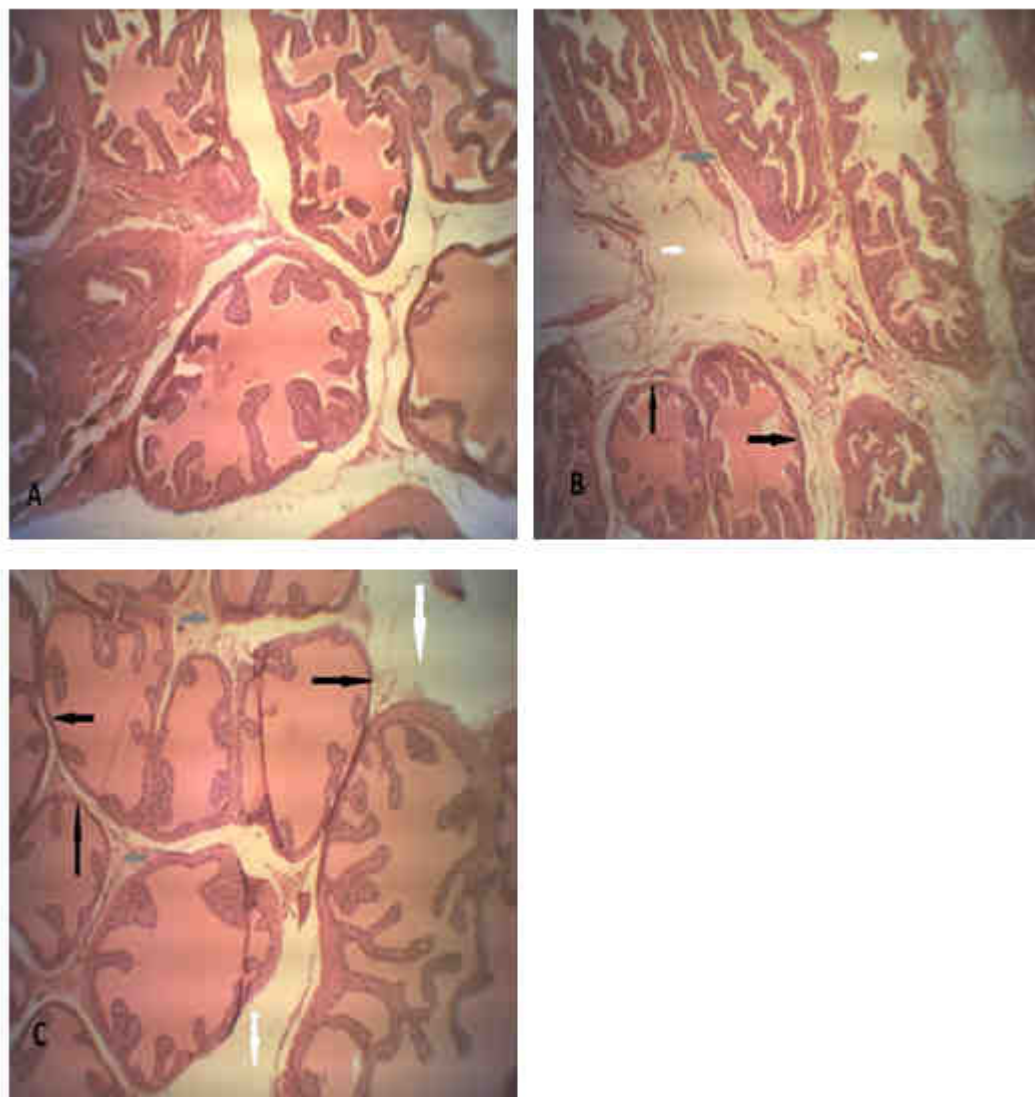**Figure 7. Effects of Sweet *P. yohimbe* on Prostrate**



Haematoxylin and eosin (H&E) staining photomicrograph of Sweet *P. yohimbe* treatment after 4 weeks on prostate. Group A (control) shows the normal architecture of the prostate, while B and C (150mg/kg bodyweight and 300mg/kg bodyweight *P. yohimbe* treatment groups) shows the prostate the thinning of the glandular epithelium (Grey Arrows), the degeneration of the glandular epithelium (white Pigmented Arrows), pseudostratification (White Arrows) and increased interstitial space in between the glands (Black Arrows). Magnification x10. Group A n=5, B n=6 and C n=6 respectively.



**Figure 8. Effects of Sweet *P. yohimbe* on Seminal Vesicle**



Haematoxylin and eosin (H&E) staining photomicrograph of Sweet *P. yohimbe* treatment after 4 weeks on Seminal Vesicles. Group A (control) shows the normal architecture of the seminal vesicle while B and C (150mg/kg bodyweight and 300mg/kg bodyweight of *P. yohimbe* treated groups) shows loss of glandular layers (Grey Arrows) increased interstitial space (White Arrows) and thinning of the epithelial layer (Black Arrows). Magnification x10. Group A n=5, B n=6 and C n=6 respectively.

#### 4. DISCUSSION

Sweet *P. yohimbe* is now commonly used in increasing proportion for the treatment of erectile dysfunction and as aphrodisiacs to increase libido like *P. yohimbe* (Jacks *et al.*, 2007). To the best of our knowledge, this is the first report of Sweet *P. yohimbe*. The main objective of this study was to evaluate the effects of sweet *P. yohimbe* on reproductive steroid hormones, male accessory glands and sperm in the rat.

Administration of Sweet *P. yohimbe* showed a dose dependent significant weight loss compared to the controls. It was observed however, that the overall percentage change in body weights was significant when compared to the control group. The significant weight loss observed in this study corresponds to previous studies on *P. yohimbe* that has lipolytic effect (Sax, 1991), but contrary to Galitzky *et al.*, 1990, which explains that *P. yohimbe* had no effect on body weight, body fat and cholesterol at low levels. However, the weight profile of the 300mg/kg test group supports the observation that *P. yohimbe* aids lipolysis and fat depletion by (Galitzky *et al.*, 1998; Galitzky *et al.*, 1990, Berlan *et al.*, 1991). These results contradict the findings of Ogwo *et al.*, (2016) that reported significant weight gain across test groups. The method of Sweet *P. yohimbe* administration in this study was different. Ogwo *et al.*, (2016) mixed *P. yohimbe* extract powder with the feed of the rats. In this study we administered Sweet *P. yohimbe* extract daily doses through oral gavages and this may be the reason for the

discrepancy. We did not observe significant changes in the relative organ / body weight ratios as reported by Ogwo *et al.*, (2015) that observed increase in the relative testicular weights following *P. yohimbe* administration.

Sperm analysis in this study showed large head to head agglutinations. The presence of increased head to head agglutination can affect sperm motility as well as concentration (WHO, 2010). However, the presence of severe agglutination may not directly mean there is an immunological cause but may be suggestive of the presence of anti-sperm antibodies. (WHO, 2010). Interestingly therefore, Sweet *P. yohimbe* may contain some anti-sperm antibody properties that are yet to be characterized. This may also explain the decrease in sperm motility and sperm concentration observed in this study. These observations also are not in agreement with those of Oyeyemi *et al.*, 1998 and Ogwu *et al.*, 2016 that reported increase in sperm concentration and motility following *P. yohimbe* administration. In sperm vitality assessment, only the 300mg/kg b.w test group had a significant decrease when compared to the control. However, it is still within the acceptable difference of 95% as stipulated by WHO (WHO, 2010) and may not have any effect in relation to infertility.

Sweet *P. yohimbe* 150mg/kg dose increased FSH, testosterone and estradiol levels compared to the control group which may indicate increased stimulation for spermatogenesis. Although LH level was decreased which may mean that Sweet *P. yohimbe* may be suppressing LH levels but increasing FSH, testosterone and estradiol levels. If low dose of Sweet *P. yohimbe* may still maintain spermatogenesis with indirect secretion of testosterone but not directly from LH stimulation of Leydig cells while 300mg/kg b.w test group increased the level of estradiol only is not clear. This phenomenon needs further investigation. However, other studies showed that *Pausinystalia macroceras* extract would support spermatogenesis at low dose while at higher doses decrease spermatogenic activity (Balch, 1997, Jacks *et al.*, 2007). Studies evaluating the effects of *P. yohimbe* on sex hormones and pituitary hormones have not been clearly interpreted. The effect of Sweet *P. yohimbe* on estrogenic activity in the testes has not been reviewed in the past. However, the reduction in testosterone level in the 300mg/kg b.w may be due to the non significant increase in estradiol level in the testes secreted by the sertoli cells, which may result in negative feedback inhibition by the secretion of inhibin which may explain the reduction in the level of LH in the serum. The estradiol level in the 300mg/kg b.w leads to a non significant decrease in the FSH level. Non significant increase in testosterone level in 150mg/kg b.w can be the reason for the decrease in LH level may be due to negative feedback inhibition of LH by testosterone. FSH promotes spermatogenesis by promoting adhesion of round spermatids to sertoli cells (O'Donnell *et al.*, 2006; Sluka *et al.*, 2006). In low dose, both FSH and LH are increased compared to the control. However in this study, Sweet *P. yohimbe* have no effect on spermatogenesis despite increased FSH, testosterone and estradiol levels at low dose. Increase in testosterone/estradiol ratio may mean that the testosterone level is high. However, the decrease of testosterone/estradiol ratio as seen in this study may indicate a rise in serum estradiol level and this can serve as a marker for infertility (Jonathan *et al.*, 1993).

The effect of Sweet *P. yohimbe* on the male accessory organs has not been previously studied. The present study showed widening of the interstitial spaces and thinning of glandular layers of the seminiferous tubules, and detaching of the basement membrane in 150mg/kg b.w test group, while the 300mg/kg b.w dose group showed severe edema and total loss of cellular architecture, decrease in spermatozoa in the lumen of the seminiferous tubules, the presence of detached membranes were as seen, complete disorganization and cellular destruction in the testes. The prostate as well as seminal vesicle had showed degeneration and pseudostratification with thinning of glandular layers and increased interstitial space due to edema.

In summary, Sweet *P. yohimbe* widely used for the treatment of erectile dysfunctions and for its aphrodisiac actions in the sub-Saharan region of Africa is seen to have a dose dependent negative effect on reproductive hormones, sperm motility and concentration, testes as well as male accessory glands in rats. These findings may lead to male infertility and further studies are needed to determine if it has similar effects in humans.

## References

- Adeniyi AA., Brindley GS, Pryor JP, and Ralph d. JI (2007). "Yohimbe in the Treatment of Orgasmic Dysfunction". London CSC Group Publishers Pp 603-607
- Ajayi AA, Newaz M, Hercule H, Saleh M, Bode CO, Oyekan AO, 2003. "Endothelin-like action of *Pausinystalia yohimbe* aqueous extract on vascular and renal regional hemodynamics in Sprague Dawley rats". *Exp. Clin. Pharmacol.* 25(10): 817
- Anderson KE, (2001). "Pharmacology of Penile Erection". 2nd Edition. Thomas Y, Crowell New York Pp 501
- Andersson KE, Holmquist F, and Wagner G, (1991) "Pharmacology of drugs used for treatment of erectile dysfunction and priapism". *Int. J. Impot. Res.* 3:155-172.
- Balch PA, (1997) "Prescription for nutritional healing-A practical A-Z reference for drug free remedies using vitamins, minerals, herbs and food stimulant". AVERY Publishers.Pp. 68-70.
- Berlan M, Galitzky J, Riviere D, Foureau M, Tran MA, Flores R, Louvet JP, Houin G, Lafontan M, (1991). "Plasma catecholamine levels and lipid mobilization induced by yohimbine in obese and non-obese

- women". *Int. J. Obesity*, 5: 305-15.
- Brugh V.M, lipshultz LI (2004); "Male factor infertility:evaluation and management", *MedClin North Am*, Mar; 88(2): 367-85.
- Cold C & Taylor J. (1999) .The Prepuce. *BJU Int*, 83 Suppl.(1), 34-44. <http://www.cirp.org/library/anatomy/cold-taylor/>.
- Cold C.J, Taylor J.R (1999); The prepuce. *British Journal urology*, V83, Suppl.1: Pages 34-44.
- Eberhard Nieschlag; Hermann M. Behre; Susan Nieschlag (2012). *Testosterone: Action, Deficiency, Substitution*. Cambridge University Press.pp. 130.
- Edmund S. Sabanegh, Jr. (2010). *Male Infertility: Problems and Solutions*. Springer Science & Business Media.pp. 83.
- Ellington, Joanna. (2014) "Slippery When Wet: One Woman's Journey through the Mystery of Sex". Dr. E Publishing, LLC.
- Emerald M. (2016) "Pituitary Gland: Pituitary Hormones". In: Caballero, B., Finglas, P., and Toldrá, F. (eds.) *The Encyclopedia of Food and Health* vol. 4, pp. 392-400. Oxford: Academic Press. Switzerland:
- Essig, Maria G. (2007) Edited by Susan Van Houten and Tracy Landauer, Reviewed by Martin Gabica and Avery L. Seifert. "Semen Analysis". *Healthwise.WebMD*.
- Etiani JC, (2012), "Preliminary investigation on effects of burantashi extract on lipoproteins of albino male and female wistar rats" (Theses). Caritas University, Enugu.
- Eweka AO, O'niabohs FA, Momodu O, (2010) "The Histological Effects of Mixed Diet Containing P.Yohimbe Ground Stem Bark On The Kidney Of Adult Male Wistar Rats (*Rattus Norvegicus*)" *Biology*, 2(1):30-36
- Galitzky J, Riviere D, Tran MA, Montastruc JL, Berlan M, (1990). "Pharmacodynamic effects of chronic yohimbine treatment in healthy volunteers". *European J. Clin. Pharmacol.* 39 (5): 447-51
- Glitzky, J., Taouis, M., Berlan, M., rivierre, D., Garrigues, M. and Lafontan, M. (1988). "Alpha 2-Antagonist compounds and Lipids Mobilization.Evidence for a Lipid mobilizing Effect of Oral Yohimbine in Health Male Volunteers". *J. Med. Biochem.* 5(10): 69-80.
- Guay AT, Spark RF, Jacobson J, Murray FT, Geisser ME, (2002). "Yohimbine treatment of organic erectile dysfunction in a dose-escalation trial". *Intern. J. Impotence Res.* 14(1): 25-31.
- Ivell R, (2007); Lifestyle impact and the biology of the human scrotum, *Reprod. Biol Endocrinol*, 5:15,
- Jacks TW, Asala AS, Priasad J, (2007). "Testicular enhancement activity of aqueous extract of *Pausinystalia macroceras* stem-bark in Wistar rats". *J. Anat.Sciences*, 1: 3-6.
- Jonathan PJ, John K, Donald RK, William TC, (1993). "Effect of obesity and fertility status on sex steroid levels in men" *J. Urol.* 42 (2) 171-174
- Kershaw-Young CM And Maxwell WM (2011). "The Effect of Seminal Plasma on Alpacai Sperm Function". *Theriogenology*.15:76(7):1107-206
- Kucio C, Jonderko K, Piskorska D, (1991) "does yohimbe act as a slimming drug?", *Isr. J. Med. Sci.* 27(10):550-6
- Lewis, SE; Aitken, RJ (2005). "DNA damage to spermatozoa has impacts on fertilization and pregnancy". *Cell Tissue Res.* 322 (1): 33-41.
- Lozano GM., Bejarano I, Espino J, González D, Ortiz A., García JF, Rodríguez AB, Pariente JA. (2009). "Density gradient capacitation is the most suitable method to improve fertilization and to reduce DNA fragmentation positive spermatozoa of infertile men". *Anatolian J. Obstet. Gynecol.* 3 (1): 1-7.
- Mehrpour O, Karrari P (2014). "Occupational exposure to pesticides and consequences on male semen and fertility: A review." *Toxicol. Lett.* 230: 146-156.
- Multigner L, Olivia A. (2002) "Secular variations in sperm quality: fact or science fiction?" *Cad Saude Publica.* 18, 403-412.
- O'Donnell L, Robertson KM, Jones ME, Simpson ER (2001). "Estrogen and spermatogenesis". *Endocrin. Rev.* 22 (3): 289-318.
- Ogwo EU, Osim EE, Nwankwo AA, Ijioma SN, (2015). "Semen Quality In Male Albino Rats Fed With Various Concentrations Of Pausinystalia Yohimbe Bark Powder (Burantashi)". *J. Med. Dent. Sc. Res.*3.1. 16-24
- Okonkwo IL, (2012). "Preliminary investigation on effects of burantashi extract on liver enzymes of albino male and female wistar rats" (Theses) Caritas University, Enugu.
- Oliveira JB, Massaro FC, Mauri AL, Petersen CG, Nicoletti AP, Baruffi RL, Franco JG (2009). "Motile sperm organelle morphology examination is stricter than Tygerberg criteria". *Reproductive Biomedicine Online* 18 (3): 320-326.
- Oliver-Beyer, B. (1986). "Medicinal Plants in Tropical West Africa", 4th Edition Morocco. Macin Group Publishers Pp 83-90.
- Oyeyemi MO, Ubiogoro O, (2015). "Spermiogram and morphological characteristics in testicular and epididymal spermatozoa of large white boar in Nigeria". *Int. J. Morphol.*, 23(3):235-239,

- Pang MG, You YA, Park YJ, Oh SA, Kim DS, Kim YJ (2009). "Numerical chromosome abnormalities are associated with sperm tail swelling patterns". *Fertil.Steril.* 94 (3): 1012–1020.
- Pareek, Tej K.; Joshi, Ayesha R.; Sanyal, Amartya; Dighe, Rajan R. (2007). "Insights into male germ cell apoptosis due to depletion of gonadotropins caused by GnRH antagonists". *Apoptosis* 12 (6): 1085-100.
- Pasqualotto EB, Daitch JA, Hendin BN, Falcone T, Thomas AJ, Nelson DR, Agarwal A (1999). "Relationship of total motile sperm count and percentage motile sperm to successful pregnancy rates following intrauterine insemination" (PD. *J. Assist. Reprod. Genet.* 16 (9): 476–82.
- Pasqualotto FF, Locambo CV, Athayde KS, Arap S. (2003) "Measuring male infertility: epidemiological aspects". *Rev Hosp Clin Fac Med Univ Sao Paulo.* 58, 173-178.
- Petrelli G, Musti M, Figa-Talamanca I. (2000) "Exposure to pesticides in greenhouses and male fertility". *G Ital Med Lav Ergon*, 22, 291-295.
- Quill, A. T., Garbers, L. D. (2002). "Sperm Motility Activation and Chemoattraction". In Daniel M. Hardy. *Fertilization.* Carlifornia: Academic press. p. 29.
- Rajmil O, Fernández M, Rojas-Cruz C, Sevilla C, Musquera M, Ruiz-Castañe E (2007). "Azoospermia should not be given as the result of vasectomy". *Arch. Esp. Urol.* (in Spanish) 60 (1): 55–8.
- Ramandeep Singh, Sarabjeet Singh, G. Jeyabalan, Ashraf Ali, Alok Semwal (2013) *Int J Recent Adv Pharm Res.*;3(1):29-35: 2230-9306.
- Sadler, T. (2010). "Langman's medical embryology". (11th ed.). Philadelphia: Lippincott William & Wilkins. p. 30.
- Sahelian R, (2010), "History of Yohimbe" *Natural Sex Boosters* <http://www.raysahelian.com/yohimbe.html>
- Sax L, 1991. "Yohimbine does not affect fat distribution in men". *International J. Obesity*, 15(9): 561-5.
- Shalet SM, (2009), "Normal testicular function and spermatogenesis", *Pediat Blood Cancer*, Aug;53(2): 285-288.
- Sluka, O'donnell, Bartles JR, Staton PG, (2006). "FSH Regulates The Formation Of Adherens Junctions And Ectoplasmic Specializations Between Rat Sertoli Cells Invitro And Invivo". *J.Endocrinol* 189(2):381-95.
- Smith, Eric P.; Boyd, Jeff; Frank, Graeme R.; Takahashi, Hiroyuki; Cohen, Robert M.; Specker, Bonny; Williams, Timothy C.; lubahn, Dennis B.; Korach, Kenneth S. (1994). "Estrogen Resistance Caused by a Mutation in the Estrogen-Receptor Gene in a Man". *New England Journal of Medicine* 331 (16): 1056-1061.
- Sredhar R.P, Jhansi R.P, (2012) "Metals: Male Reproductive Function", *Int.J. Pharm.Sci.Rev.Res*,16(2) 13, 56 – 60.
- Suckow, M., Weisbroth, S., & Franklin, C. (2005). "The Laboratory Rat", Second Edition (American College of Laboratory Animal Medicine). Toronto: Academic Press.
- Sunderland, T.C. et al (1997) *The Ethnobotany, Ecology and Natural Distribution of Yohimbe (Pausinystalia johimbe (K.Schum.)), an Evaluation of the Sustainability of Current Bark Harvesting Practices, and Recommendations for Domestication and Management. A Report Prepared for ICRAF.*
- Weschler, Toni (2002). "Taking Charge of Your Fertility" (Revised ed.). New York: HarperCollins. p. 189.
- William J. Kraemer; AD. Rogol (2008). "The Encyclopedia of Sports Medicine". An IOC Medical Commission Publication, the Endocrine System in Sports and Exercise. John Wiley & sons.pp. 286.
- Wolf-Bernhard Schill; Frank H. Comhaire; Timothy B. Hargreave (2006). "Andrology for the clinician". Springer Science & Business Media.pp. 76.
- World Health Organization. "WHO laboratory manual for the examination and processing of human semen". 5th ed., Geneva,
- Yakubu MT, Lawal SB, Mansur L, Akanji MA, (2003). "Evaluation of Selected Parameters Of Rat Liver And Kidney Function Following repeated Administration Of Yohimbine" *Biokemistri* 15(2) 50-60.