

BIFOCAL BONE LENGTHENING FOR SEVERE POST-TRAUMATIC SHORTENING OF THE FEMUR USING ILIZAROV SYSTEM IN A HYBRID FASHION: A Case Report and Literature Review

IBEANUSI S.E.B.¹, Dr. Chioma J C²

¹Dr. IBEANUSI S.E.B. FRCS Ed, FWACS, FMCS, MSc. (Trauma Surg.)

Department of Surgery, University of Port Harcourt, Nigeria.

²Dr. Chioma J.C. MBBS, FWACS

Department of Surgery, Federal Medical Centre, Umuahia.

E mail: chiomaac.j269@gmail.com

Abstract

Limb length discrepancy portends major challenge to a person's function and the treating surgeon.. A 44 year old male patient presented with 15.5cm shortening of the femur from, infected non-union of the femur following injury sustained from road traffic collision 10 years earlier. He had multiple failed operative fracture fixation complicated by post operative infection causing significant morbidity and loss of job from prolonged immobilisation. The infected non-union and the limb length discrepancy were successfully treated by infection control and limb lengthening by bifocal callotaxis using the Ilizarov method in a hybrid fashion over a period of 105 days. The patient regained weight bearing on the affected limb after 7 months.

Key Words: Severe Limb Length Discrepancy, Infected Non-Union, Bifocal Callotaxis, Hybrid Fixation, Shortened Lengthening Time

BACKGROUND

Limb length discrepancy (LLD) is when there is a difference between the lengths of any particular limb on the different sides of the body in the same individual (1). Severe limb length discrepancy portends significant challenge to both the patient and the managing orthopaedic and trauma reconstruction surgeon (2).

The causes of LLD could generally be classified as congenital or acquired. The acquired cause includes recent or previous trauma,, bone infections and dysplasia (3,4). The effects of LLD in each particular patient vary depending on the extent of the discrepancy. These effects may include limping, more energy and exertion on walking, pain on walking, the need for use walking aids for ambulation and psycho-social challenges (5, 6). Depending on the severity of the morbidity from the LLD, there may be the need for change in jobs, habits, accommodation, social recreation and activities of daily living for the affected persons.

Morbidity from LLD is worsened if the deformity resulted from infected non union (7 8). The issue of infection in the presence of non-union is like that of the "chicken and egg situation" as one often leads to the other and there is the need to treat one to be able to control the other (8). Infected non union has been classified by various authors based on the extent of the infection, the deformity and associated morbidity (9, 10

Surgical treatment is not usually recommended especially when the difference is less than 4 cm (4, 11). Shoe lifts or orthoses are usually recommended in cases where LLD is less than 4 cm, Orthoses have been shown to improve limb function on walking and running (4, 11). In addition, shoe lifts are cheap and are easily replaced when they become defective. Surgery is the recommended for correcting significant LLD above 4cm (8).The surgical options of treatment especially when the LLD is extensive may include, use of vascularized free bone transfer, lengthening and or shortening of the limb to achieve equalization of length of both sides and amputation (4, 11,12).When LLD resulted from infected non-union, the goals of treatment include the eradication of infection, achievement of bony union and correction of soft tissue, bony and joint deformities (12,13).

The process of limb lengthening using callotaxis method as proposed by Ilizarov requires that the distraction and transport be done at a very slow rate usually 1mm per day to the desired length followed by a period of time

required for the maturation and consolidation of the regenerate (13). In cases when the LLD is extensive, the duration required to lengthen the bone to achieve equilibration using Ilizarov approach can be quite prolonged. This prolonged treatment time often results in patients' dissatisfaction, loss of compliance, and other bony and soft tissue complications such as recurrent infections of the pin tracts used in the lengthening process (13). Lengthening at 2 distinct levels after corticotomy (bifocal lengthening) has been tried by surgeons in an attempt to reduce the duration for lengthening in cases of extensive LLD (14). Bifocal lengthening, although not commonly done provides shortened lengthening time, immobilization and hospitalization during the correction of extensive LLD (14, 15).

Amputation has been recommended especially when the LLD is very extensive such as 25cm and above and the resources for complex limb reconstruction not available (15). In Nigeria, amputation is often not readily accepted as option of treatment (16) and the surgery for limb equalization is often not very available due to limited resources and expertise often required for such complex procedures (16). This report describes a case of significant LLD of 15 cm resulting from multiple failed treatment of fracture of the femur which was successfully treated by bi-focal distraction osteogenesis with the Ilizarov system used in a hybrid fashion.

CASE REPORT

This is a case of a 44 year old male patient who presented with 15.5cm shortening of the femur resulting from, infected non-united fracture of the right femur from a road traffic collision 10 years earlier. Following the initial injury the patient had two unsuccessful open reduction and internal fixations (ORIF). The second ORIF was complicated by persistent post-operative infection, hardware failure and segmental loss of the femur culminating to severe LLD. The resultant deformity significantly limited the patient's function including the activities of daily function leading to loss of job as a trained nurse. He had recurrent discharging sinuses from the affected bone with recurrent flares of osteomyelitis. He was markedly distressed both physically, psychologically, socially and financially as he was the bread winner of an extended family responsible for more than 12 dependants.

The significant findings on clinical examination was in the musculo-skeletal system which revealed a LLD of about 15.5cm shorter than the left side and right foot was floating about 17cm above the ground. There were multiple actively discharging sinuses on lateral aspect of the right thigh through an old incision scar with an abnormal movement at the mid thigh. The right hip and the part of the limb below the right knees were essentially normal. His other systems were essentially normal.

X ray radiography of the right femur showed old fracture of the mid shaft of the femur with failed plate and screws in place. The fracture showed non-union with features of chronic osteomyelitis. The Full blood count revealed haemoglobin of 90g/L, white blood cell count of $11 \times 10^9/L$ with Neutrophils of 72% and Lymphocytes of 21%. The Erythrocyte Sedimentation Rate (ESR) was 66mm per hour. His blood electrolytes, random blood sugar and chest X-ray radiography were essentially all within normal limits.

With the extent of the deformity and associated prolonged morbidity, various options of treatment including amputation were discussed with the patients. He bluntly declined amputation but opted for limb salvage. Following an informed consent, the patient had the infected and failed implants removed, combined with sequestrectomy, excision of infected non-union, acute docking and compression of the bone ends at the fracture site. The shortened limb was lengthened by callotaxis using the Ilizarov method following corticotomy at two levels (i.e. distal right femur and proximal right tibia). The fixation was achieved with Ilizarov's ring -wire fixators for subsequent distraction osteogenesis at both metaphyses around the right knee joint, whereas compression at the fracture site in the mid shaft of right femur and stabilization of the right tibia distally was done using threaded bar and pins external fixator in a hybrid fashion.

Distraction was commenced at the rate of 1mm per day at the distal femur and 0.75mm per day at the proximal tibia after 10 days following the corticotomy. The LLD was corrected over a period of 105 days and patient allowed proportionate weight bearing 7 months after bifocal corticotomies. He had up to 4 episodes of pin sites infection which was treated successfully with wound dressing and occasional antibiotics. The infected fracture non union was healed, infection successfully eradicated and the LLD corrected.

DISCUSSION

The management of long bone fractures with significant bone gap and limb length discrepancy could be daunting in trauma reconstruction surgery (1, 9). Earlier methods of limb lengthening such as that described by Wagner were associated with high incidence of complications such as infection, non-union, and failure of fixation (1-3). Soft tissue resistance was a major limiting factor for bone distraction and lengthening (17). Resistive tension during distraction osteogenesis (termed distraction-resisting forces) is generated by the differences created during adaptation of the newly formed bone and the already established soft tissues (5). Soft tissue resistance is currently blamed as the cause of complications such as joint stiffness, axial deviations of the lengthened limb etc. (6, 13).

Ilizarov later introduced slow distraction osteogenesis following a gentle corticotomy to achieve bone lengthening and overcome soft tissue resistance with special basic equipment (6, 13). The circular fixator invented by Ilizarov for the treatment of limb deformities and shortening, revolutionized the limb lengthening treatment (18). Preservation of the periosteum, careful corticotomy to preserve the endosteal and marrow circulation, a stable fixation using tensioned wires, and the period of rest observed before distraction allows for formation of fracture callus; (2,6,13,17). The complex and slow method of bone lengthening can be a salvage option in situations of significant LLD from non-union complicated by infection.

In this particular patient been reported, all hope was lost following ten years of immobilisation and two failed surgical interventions, prolonged wound care and multiple antibiotic usage. His LLD greater than 15cm complicated by intractable infection seemingly appeared amenable to only amputation in the face of limited resources. However, the option limb salvage with the Ilizarov principles at bi-focal levels gave the patient hope and ultimately restored his physical, mental, social and psychological well being over a shorter period. The patient became better positioned financially to fend for self and his extended family.

The management of post traumatic shortening and infected non-union of long bones often present a major challenge (19). Unfortunately, complications of non-union include persistent infection, stiffness of the joint, deformity and disability are rife in most developing countries, Conventionally treatment of non-union include debridement and covering of tissue defects with grafts or flaps (8), packing of defects with antibiotic beads till biologic membrane forms and beads replaced with bone graft (20), Papineau's open cancellous grafting (21), bone transplantation, and transposition of adjacent bones such as tibialisation of fibular in the cases involving the tibia (22). The Ilizarov method however simultaneously addresses most of the aforementioned problems and offers a better solution for complications of non-union (23).

The use of this method of treatment eliminated the infection and achieved union of the fracture over a period of 3 and half months giving a distraction rate of about 1.4mm per day. The achievement of 15cm bone length using this method was very gratifying for the patient who had lost all hopes of functional recovery of the limb as it would have taken a minimum of 170 days to achieve the same result using the conventional method originally described by Ilizarov (13). In a similar study in India to evaluate outcomes of Ilizarov ring fixation in recalcitrant infected tibial non-unions, the average bone gap was 4cm in 59% of the patients who underwent external bone transport with 9 month fixation period and about 8.5 month average fixation period for patients that had internal bone transport (23).

Adegbehingbe and colleagues used monotube fixator to achieve limb lengthening by distraction, resulting in a 10.1 ± 4.0 cm mean bone length lengthening, with an average mean bone transport time of 105.6 ± 38.2 days, consequently leading to a 0.99 ± 0.14 mm/day(6).

Bell used the conventional all wire transosseous technique of the Ilizarov method, which included fixation of the whole tibia and foot for bifocal lengthening. Although the outcome was excellent, the fixation was bulky and complex, making it uncomfortable for the patients (20 Noonan). The use of bifocal distraction had been mainly described for treatment of mandibular defects (24) but literature is scarce its use in long bone defects.

Deformity correction and lengthening has been enabled by the Ilizarov approach and the utilization of hybrid configuration which combined the ring and wire systems and the bar and pins fixators improved rigidity and comfort. The combination of the ring –wire fixators at the metaphysis near and across the knee joint and the bar-pin fixators at the shaft of both femur proximally and tibia distally in a hybrid fashion provided a less cumbersome and more comfortable construct for the patient without compromising stability of the fixation. The

conventional Ilizarov system has been considered bulky and uncomfortable for most patients (25). Its use in this case would have very uncomfortable for both the surgeon and the patient. The single bar and two parallel pins per segment fixation advocated by Wagner (1) and now popularised by the linear rail technique (26) has limited ability to control angular deformities especially valgus and varus during lengthening especially around the joints as in this case. Attempt to obviate these complications led to the revision to a two-crossed pin per segment fixation (27).

Good outcomes in lengthening has been reported in the use of the currently modified system compared to results from the conventional Ilizarov method (28). Multiple wire and pin tract infections and scars are still complications of the method. However, gains of the treatment for the patient superseded this cosmetic effect.

An observed drawback with this described method of care was the immobilization of the right knee joints over the period of bone lengthening and consolidation of the regenerate. This however, did not pose significant problems as the knee range of motion recovered some few months later after the treatment. More so, the knee is usually immobilized in cast for about the same length of time when fractures of the tibia are treated by cast immobilization. Another anticipated challenge was the issue of rapid stretching of the soft tissues during the period of lengthening using this method. This issue was also not a major problem in this case since the patient was already a fully grown adult. His soft tissues and supporting tissues around the shortened bone had been present in their full lengths prior to the index injury but only contracted over the years as result in the loss in the length of the femur. The gradual distraction of the bones only assisted in re-establishing lengths of the contracted surrounding soft tissues and the supporting neuro-vascular structures. Whether this will be the same in cases of congenital shortening of the long bones may need to be ascertained using better designed clinical studies.

CONCLUSION

Bifocal limb lengthening is a viable option in the treatment of severe LLD in patients who would not accept amputation and when other options of treatment are not possible. It shortens the length of hospitalisation and reduces complications associated with prolonged external fixation thus reduces the comparative cost of treatment for the patients. The adoption combined Ilizarov ring fixation especially around the joints and the conventional bar and pin fixation at the shaft of the long bones is effective, makes the construct less cumbersome and less bulky for both the patient and the treating surgeon without compromising stability of the fixation. This helped in making the procedure more acceptable to the patient. However, for optimal results the treatment needs to be individualized for each particular patient with consideration of other biological and socio-economic factors around the individual patients.

DECLARATIONS:

The authors categorically state that this manuscript, including related information and figures has not been previously published and the manuscript is not under consideration elsewhere.

All the information contained in this manuscript are original except otherwise clearly stated and duly acknowledged.

Consent for Publication: Available

Funding: None

Conflicting interests: None

Authors' contributions: All the authors made substantial contributions in the study design, implementation and write up.

REFERENCES

1. Aaron AD, Eilert RE. Results of the Wagner and Ilizarov methods of limb-lengthening. *J Bone and Joint Surg.* 1996; 78: 20–29.

2. De Bastiani G, Aldegheri R, Renzi-Brivio L, Trivella G. Limb lengthening by callus distraction callotaxis. *J Pediat Orthop*. 1987; 7:129–134
3. Mosca VS, Moseley CF. Complications of Wagner leg lengthening and their avoidance. *Orthop Trans*. 1986; 10: 462.
4. Malot R, Park K-W, Song S-H, Kwon H-N, Song H-R. Role of hybrid monolateral fixators in managing humeral length and deformity correction: 23 patients (40 humeri) followed for 1–7 years. *Acta Orthopaedica*. 2013; 84(3):280-285
5. Cai G, Saleh M, Coulton L, Yang L. Distraction-resisting force during tibia diaphyseal lengthening and consolidation-a study on a rabbit model. *Clin Biomech* 2004; 19: 733–737.
6. Adegbehingbe OO, Ojo OD, Abiola PO, Ariyibi AL, Oginni LM, Obateru JA. Distraction by a monotube fixator to achieve limb lengthening: predictive factors for tibia trauma. *Journal of Trauma Management & Outcomes*. 2013; 7:3. doi:10.1186/1752-2897-7-3.
7. A.E. Beris, Z. Dailiana, E.O. Johnson and P.N. Soucacos, Vascularized bone grafts for the management of nonunion, *Injury Int J Care Injured* 2006; 37(5): S41–S50.
8. Gustilo RB Orthopaedic infection. Diagnosis and treatment. Philadelphia: Saunders, 1989
9. D. Paley, M. A. Catagni, F. Argnani, A. Villa, G. B. Benedetti and R. Cattaneo, “Ilizarov Treatment of Tibial Nonunions with Bone Loss,” *Clinical Orthopaedics and Related Research*, 1989; 241:, 146-165.
10. Kulkarny: Kulkarni G S. Principles and practice of deformity correction. *Indian J Orthop* 2004;38:191-8
11. Hasler CC, Krieg AH. Current concepts of leg lengthening. *Journal of Children’s Orthopaedics*. 2012; 6(2):89-104
12. Umizarov GA Classification of nonunions of the long bones complicated by infection and principles of treatment. *Sborn Trud CITO*, 1986; 30:5–9.
13. Ilizarov GA, Green SA Transosseous osteosynthesis., Berlin Heidelberg New York. Springer, 1992.
14. Leif Pål Kristiansen & Harald Steen Reduced lengthening index by use of bifocal osteotomy in the tibia: Comparison of monofocal and bifocal procedures with the Ilizarov external fixator, *Acta Orthopaedica Scandinavica*, 2002; 73:1, 93-97, DOI: 10.1080/000164702317281486
15. Choi I H, Sohn C S, Chung C Y, Cho T J, Lee J W, Lee D Y. Optimum ratio of distraction in double level tibial lengthening. *Clin Orthop* 1999; 368: 240-6.
16. Ibeanusi SE. Salvage of severely injured limbs in a developing country. *Port Harcourt Medical Journal* 2012; 12(1): 7 – 9.
17. Codivilla A. On the means of lengthening, in the lower limbs, the muscles and tissues which are shortened through deformity. *Clin Orthop Relat Res* 1994; 301:4–9..
18. Hamdy RC. Evolution in long bone deformity correction in the post-Ilizarov era: External to internal devices. *J Limb Lengthen Reconstr* 2016;2:61-7
19. Noonan KJ, Leyes M, Forriol F, Canadell J: Distraction osteogenesis of the lower extremity with use of monolateral external fixation. *J Bone and Joint Surg* 1998, 80-A (6):793–806.
20. Masquelet A.C., Begue T. The concept of induced membrane for reconstruction of long bone defects. *Orthop Clin North Am*. 2010; 41:27–37.
21. Papineau LJ L’excision-greffe avec fermeture retardée délibérée dans l’ostéomyélite chronique. *Nouv Presse Med*, 1973; 2:2753–2755.
22. Huntington TW. VI. Case of bone transference: Use of a segment of fibula to supply a defect in the tibia. *Ann Surg*. 1905;41:249–51
23. Madhusudhan TR, Ramesh B, Manjunath KS, Shah HM, Sundaresh DC Krishnappa N. Outcomes of Ilizarov ring fixation in recalcitrant infected tibial non-unions – a prospective study. *Journal of Trauma Management & Outcomes*. 2008; 2:6 doi:10.1186/1752-2897-2-6.
24. Natu SS, Ali I, Alam S, Giri KY, Agarwal A, Kulkarni VA. The biology of distraction osteogenesis for correction of mandibular and craniomaxillofacial defects: A review. *Dental Research Journal*. 2014; 11(1):16-26.
25. Paley D. Problems, Obstacles and complications of limb lengthening by the Ilizarov technique. *Clin orthop Relat Res*. 1990;250: 81–104.

26. Watson TJ. Principles of External Fixation. Chapter 8, Rockwood and Green's fracture in adults. 7th ed. Vol. 1. Philadelphia USA: Lippincott Williams and Wilkins Publisher; 2010. pp. 191–243.
27. Fincham BM, Jaeblo T. The effect of drill bit, pin, and wire tip design on drilling. *J Am Acad Orthop Surg.* 2011; 19(9):574-9.
28. Anglen J O. Early Outcome of Hybrid External Fixation for Fracture of the Distal Tibia *Journal of Orthopaedic Trauma* 1999;13(2):92-97.
29. Littenberg B, Weinstein LP, McCarren M, et al. Closed fractures of the tibial shaft. A meta-analysis of three methods of treatment. *J Bone Joint Surg Am.* 1998 Feb. 80(2):174-83. [Medline].

Figure1. Pre operative radiograph

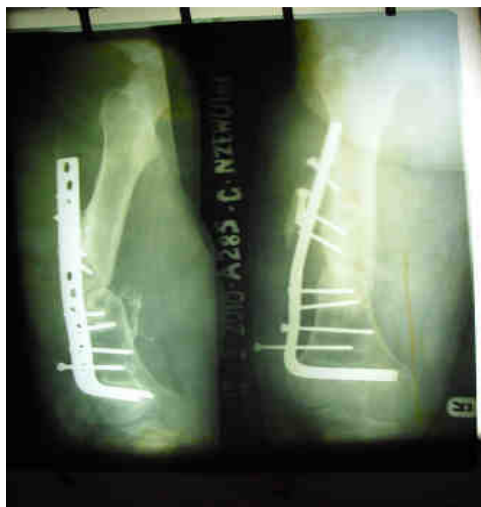

Figure 2. 14 Day Post distraction



Figure 3. Hybrid fixation photograph (Lat. View).

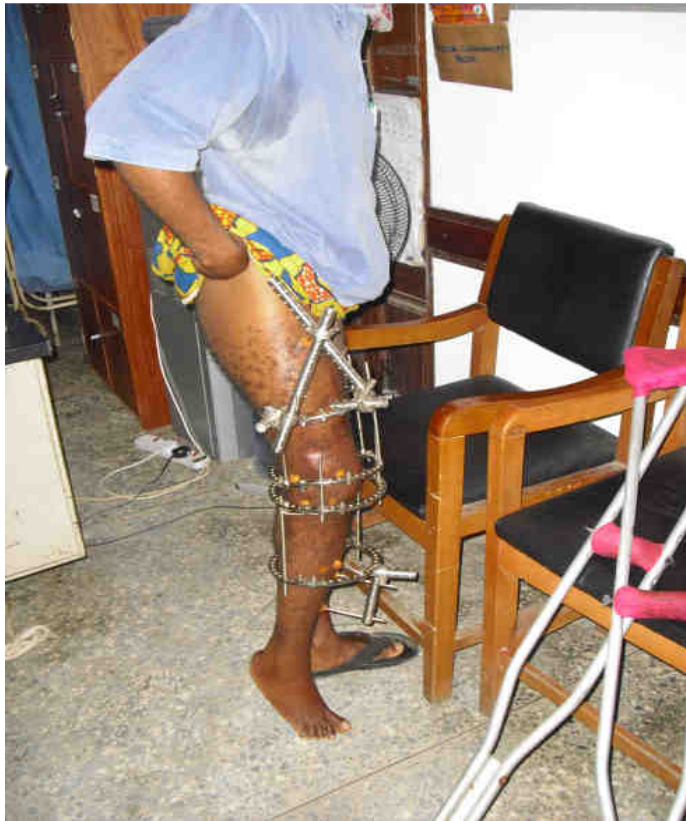

Figure 4. Radiograph at completion of Distraction

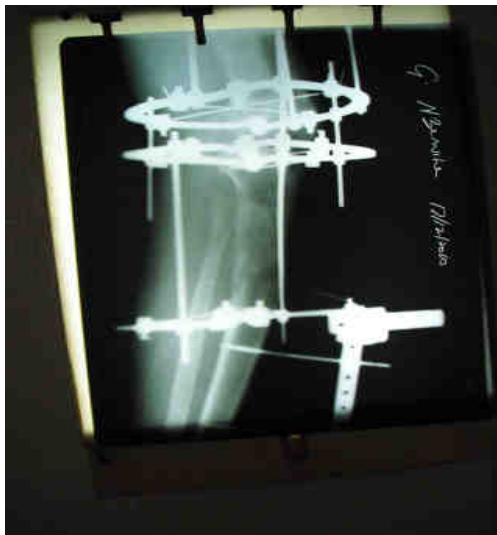

Figure 5. Post treatment radiographs showing Tibia and femur

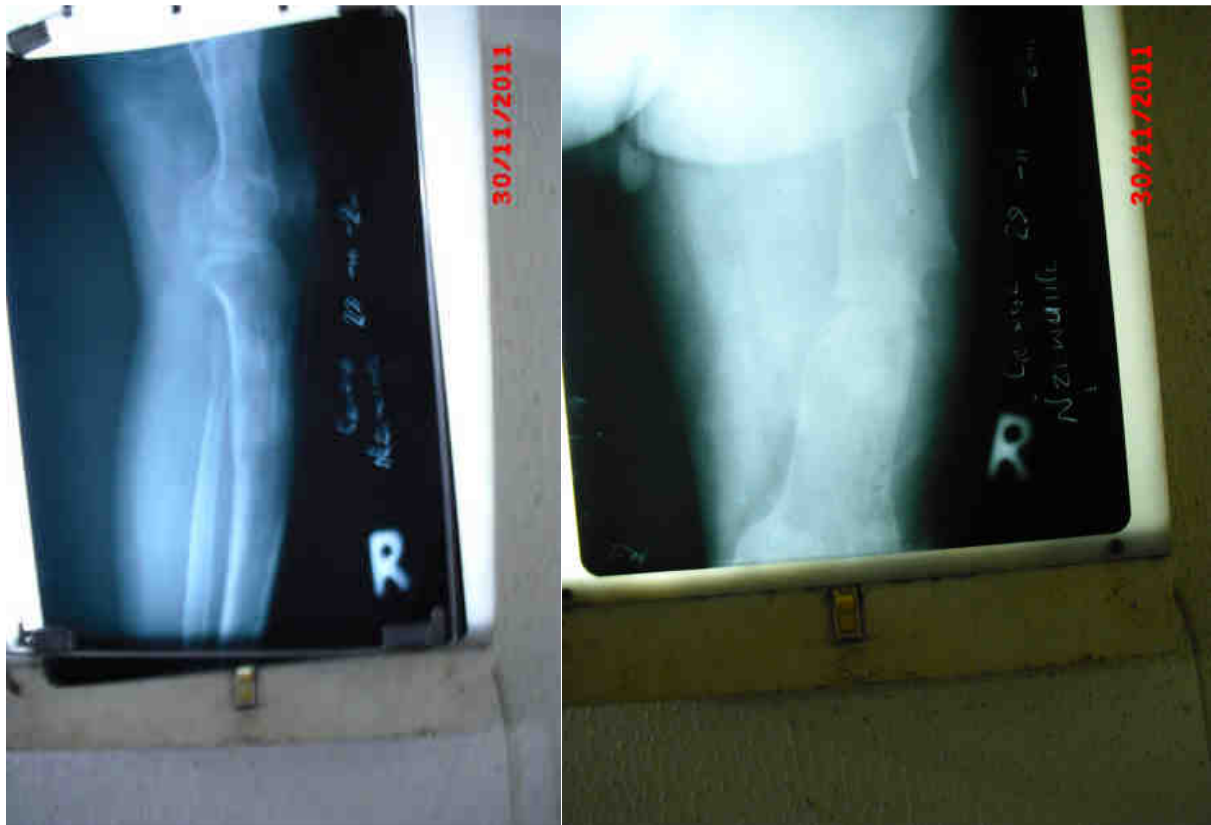


Figure 6. Post treatment photograph (Lat. and AP Views).

