

## Anti-Necrobiosis Effect of Maggot Infestation in Experimental Pig Skin: A Tool in Forensic Medicine

SABO, A.M.<sup>1\*</sup> MANDONG, B.M.<sup>2</sup> ADELAIYE, A.B.<sup>3</sup> HASSAN, W.B.<sup>3</sup> LONGWAP, A.S.<sup>4</sup>

1.Department of Human Physiology, Faculty of Medical Sciences, University Of Jos

2.Department of Pathology, Faculty of Medical Sciences University of Jos

3.Department of Human Physiology Faculty of Medicine Abu Zaria

4.Department of Chemical Pathology, Faculty of Medical Sciences, University of Jos

### Abstract

Forensic examination in crime scene investigation (CSI) may involve examination of corpses from outside and exposed environment or even exhumed bodies. Analysis of necrotic tissue is often a challenging work. Though forensic entomology is helpful in determining time of death by linear regression method, this work seek to employ and advance the use of knowledge of the effect of insect larvae in comparing the pattern and nature of necrobiosis in maggot infested tissue and non-infested tissue during forensic analysis and interpretation. Twenty samples of pig skin were obtained, a good choice as a model similar to human skin, ten of which were deliberately infested with cultured larvae of *Lucilia sericata* as test and the other ten allowed to undergo natural Necrobiosis without the larvae as control group, all in moist environment. The weight of each sample pig skin is taken every other day (48 hourly). The result showed a significant loss of consistency by autolysis and sloughing in non-infested pig skin more than in the infested pig skin sample and a significant of loss of weight in the two groups of sample ( $P < 0.05$ ). Marked acantholysis was more prominent in the non-infested pig skin than infested Pig skin on qualitative histological comparison. The study suggests that Necrobiosis in Maggot infested Tissue is much less than in Non-infested Tissue.

### INTRODUCTION

Necrobiosis is a distinct degenerative cell process at death with the help of released autolytic enzymes. This is clearly distinguishable from apoptosis (programmed cell death) a process of cell death within a living tissue in which the cell actively take part in its own demise. Necrobiosis is a process accelerated by higher environmental temperatures and the presence of invading bacteria. The larvae (maggots) of some species of fly are long known to exert beneficial effect on necrotic wound and have been exploited therapeutically in biosurgery, specifically Maggot Debridement Therapy according to Pechter and Sherman (1993). Forensic entomology helps in determining the time of death by linear regression method, a process that involves freezing one group of sample of the larvae for reference and then growing to maturity another set of the larvae from the same decomposing corpse. The sizes of the second generation of the larvae are compared with the frozen reference group obtained directly from the corpse to estimate the time of death. Pathologists are also interested in consistency of tissue during analysis. The consistency may vary according to whether the dead body undergoing investigation has been exposed to insect in the open and has grown some maggots or not. The analysis may prove crucial in presenting evidence before the law.

AIM: This work seek to study the pattern and nature of necrobiosis in maggot infested and non-infested model pigskin.

### MATERIAL AND METHOD

Twenty units of pig skin sample cut to average size of 35 kg.

Four plastic buckets two of which with tightly covered outlet with clothing

Twenty rubber bands

Twenty five Litre of distilled water.

Metlar Balance

Formal-saline

Ten Tissue specimen bottles

Dissecting kit

Pairs of surgical gloves and disposable gloves

Ten of the twenty pig Skin samples were deliberately infested with laboratory grown larvae of *Lucilia sericata*. The other Ten are control samples and the all of them were allowed to decompose naturally under the same room temperature in moist environment within the two plastic Jars. The other Ten are control samples and the all of them were allowed to decompose naturally under the same room temperature in moist environment within the two plastic Jars. Each sample is weight serially on alternate days with Metlar balance for two weeks (384 hours) Replicates of the experiment of a sample each of the two groups were conducted with specimen for histology taken from both the maggot infested and the non-infested Pigskin samples for histology.

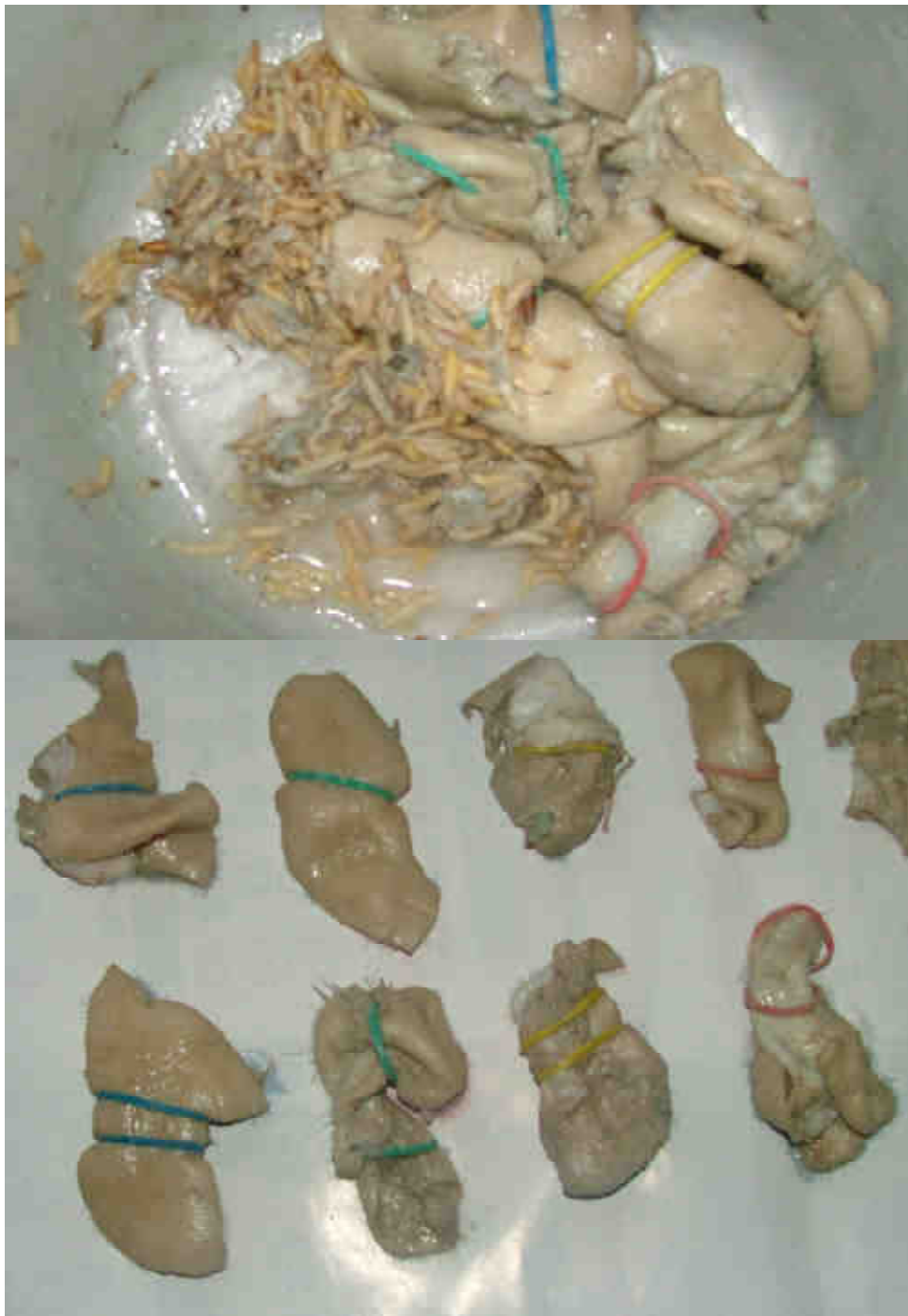

Plate 1. Picture maggot infested Pig skin samples and coloured rubber band labeled samples.

## RESULT

**TABLE 1 SHOWING CHANGES IN WEIGHT IN GRAM OF NON INFESTED PIG SKIN SAMPLES WITH TIME IN HOURS**

Time	Specimen 1	Specimen 2	Specimen 3	Specimen 4	Specimen 5	Specimen 6	Specimen 7	Specimen 8	Specimen 9	Specimen 10
0	28.8	28.6	38.11	39.01	32.12	36.7	42.64	39.53	38.04	28.31
48	29.6	28.8	37	36.8	30.55	36.15	41.28	38.1	37.9	27.4
96	28.35	27.1	35.69	37.05	30.06	35.29	41.15	37.92	37.93	26.13
144	30.01	27.71	37.09	37.27	31.7	35.92	41.99	38.68	37.7	26.72
192	33.5	29.59	42.18	38.1	35.82	36.22	43.54	40.01	38.47	28.49
240	30.01	27.09	37.27	34.52	32.48	34.27	41.61	36.81	33.98	28.69
288	36.92	25.09	37.37	31.97	31.02	31.11	40.01	32.42	30.82	26.09
336	23.82	22.19	34.74	28.84	27.69	31.5	35.19	29.51	26.29	22.45
384	21.49	20.92	31.93	27.51	25.5	30.91	35.2	28.23	25.63	20.58

**TABLE 2 SHOWING CHANGES IN WEIGHT IN GRAM OF INFESTED PIG SKIN SAMPLES WITH TIME IN HOUR**

Time	Specimen 1	Specimen 2	Specimen 3	Specimen 4	Specimen 5	Specimen 6	Specimen 7	Specimen 8	Specimen 9	Specimen 10
0	39.4	33.9	32.2	30.4	23.4	34.7	27.7	39.6	34.1	22.5
48	39.6	35	34	32.48	26.3	36.3	29.45	38.44	38.1	25.45
96	36.5	31.65	31.61	29.59	23.64	32.68	25.7	35	35.66	22.6
144	37.59	32	32.39	30.03	25.25	33.32	27.19	35.78	36.03	23.86
192	35.78	32	32.22	30.05	24.88	33.08	27.17	34.87	36.28	23.71
240	33.82	31.31	29.81	28.11	24.29	32.08	26.53	32.22	34.44	23.05
288	32.71	30.06	29.23	24.99	23.39	31.93	27.18	31.8	35.3	23.12
336	30.04	29.29	24.72	20.11	21.79	31	24.62	29.6	29.09	21.12
384	29.19	27.32	22.63	19.18	20.91	29.89	22.47	28.23	24.08	18.67

The results were analyzed using SPSS and MS Excel software

Table 3. SHOWING ANALYSIS OF VARIANCE (ANOVA)

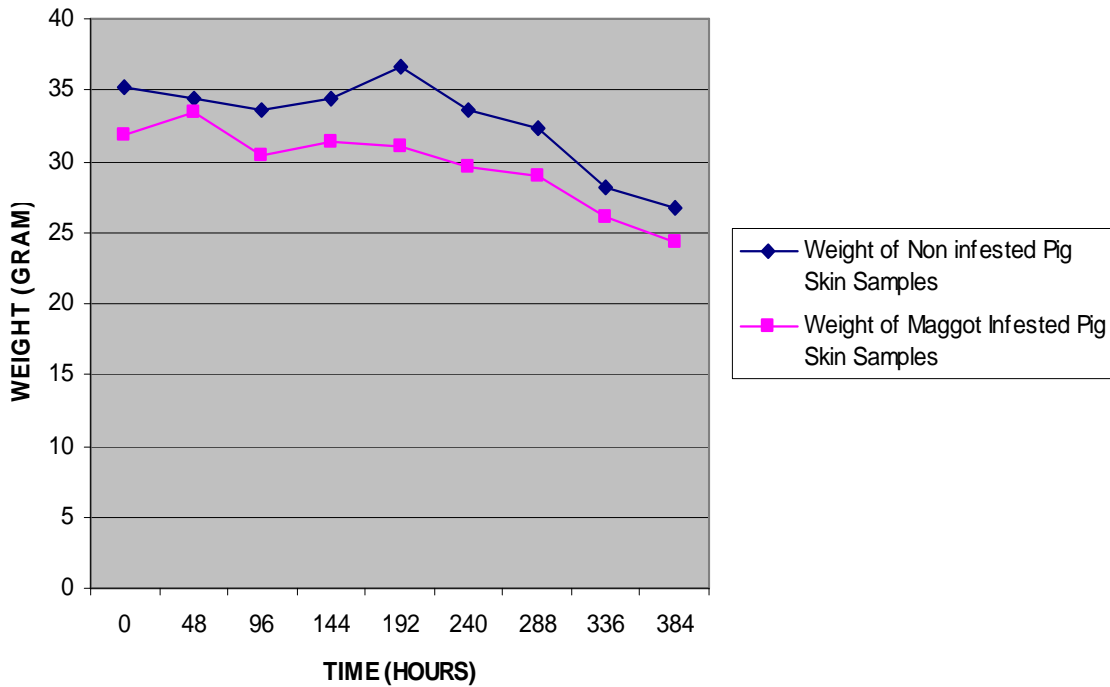
ANOVA					
	Sum of Squares	df	Mean Square	F	Sig.
Weight of Non-infested samples of Pig skin (Gram)	Between Groups	8	105.223	4.361	.000
	Within Groups	81	24.129		
	Total	89			
Weight of Maggot infested Pig Skin (Gram)	Between Groups	8	83.426	3.870	.001
	Within Groups	81	21.559		
	Total	89			

TABLE 4. SHOWING CORRELATION TEST RESULTS

Correlations			
		Weight of Non-infested sample Pig skin (Gram)	Weight of Maggot infested Pig Skin (Gram)
Weight of Non-infested sample Pig skin (Gram)	Pearson Correlation	1.000	.359**
	Sig. (2-tailed)	.	.001
	N	90	90
Weight of Maggot infested Pig Skin (Gram)	Pearson Correlation	.359**	1.000
	Sig. (2-tailed)	.001	.
	N	90	90

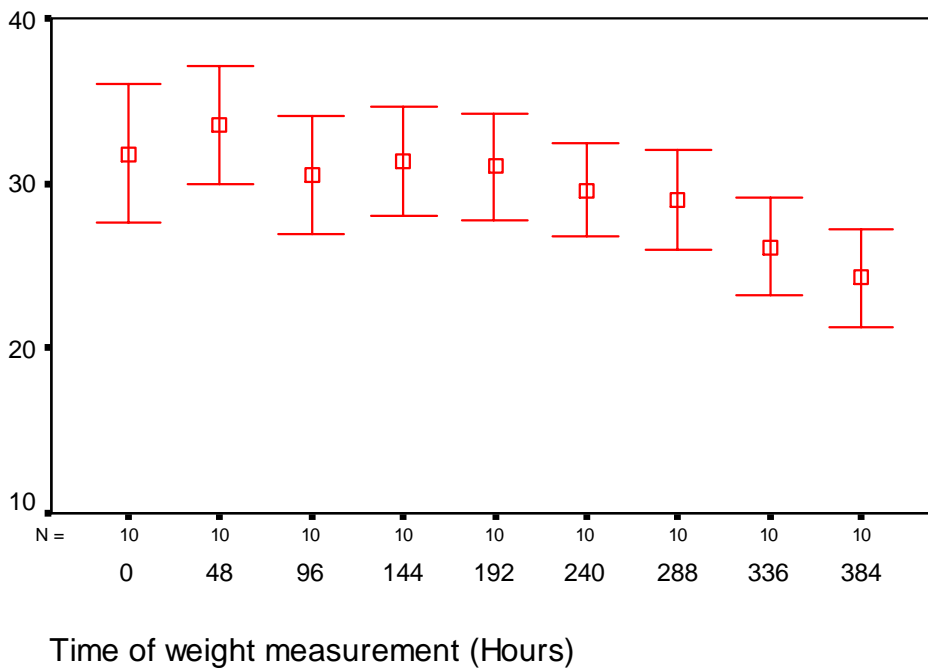
\*\* . Correlation is significant at the 0.01 level (2-tailed).

**LINE GRAPH SHOWING COMPARATIVE CHANGES IN MEAN WEIGHTS OF NON-INFESTED AND MAGGOT INFESTED PIG SKIN SAMPLES WITH TIME**



**95% CI Weight of Maggot infested sample Pig Sk**

**ERROR BAR SHOWING CHANGES IN WEIGHT OF MAGGOT INFESTED PIG SKIN WITH TIME**



SLIDE SHOWING TISSUE B96 HOUR OF INCUBATION.

SLIDE SHOWING TISSUE BREAKDOWN IN NON- INFESTED PIG SKIN AT 96 HOUR OF INCUBATION

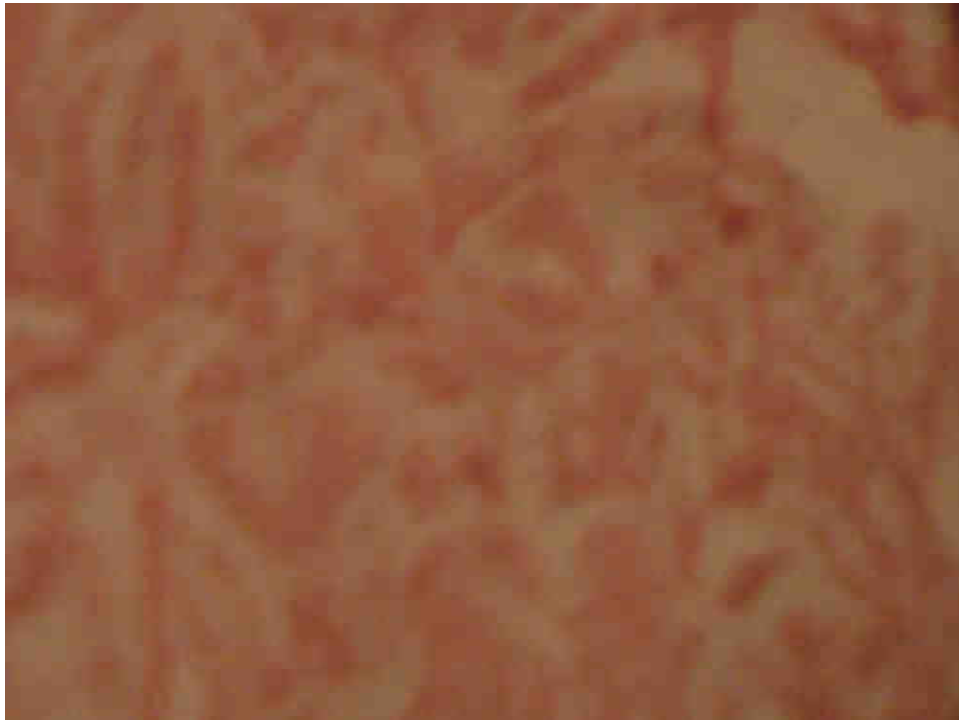

PLATE I. There is massive break down of the tissues of skin with blebs and fat necrosis prominent acantholysis

SLIDE SHOWING TISSUE BREAKDOWN IN MAGGOT INFESTED PIG SKIN AT 96 HOUR OF INCUBATION

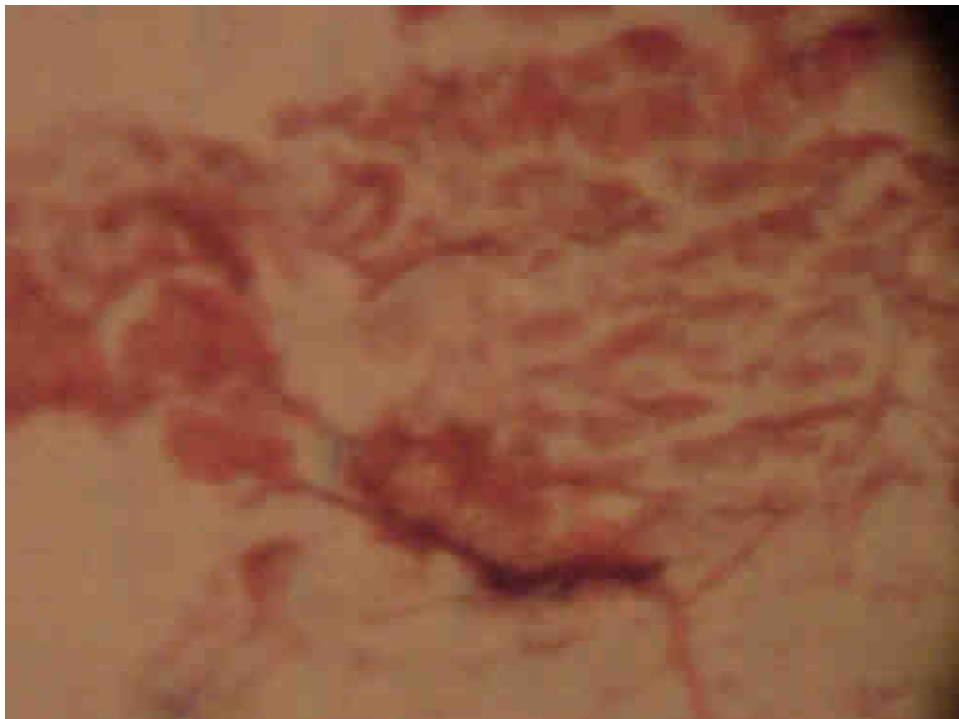


PLATE II. There is comparatively less break down of the tissue of the skin and lesser feature of acantholysis

#### **DISCUSSION**

Marked acantholysis is shown more in control (Non-infested) tissue samples. Proteolytic enzymes released on food substrate (necrotic tissue) by maggots may ordinarily be thought to cause enhance breakdown of tissue

evident as loss of consistency and comparatively lowered weight. The results in this work suggests otherwise. Maggot infested tissue samples have better consistency and weight reduction is significantly less than those of non infested Pig skin sample  $P < 0.01$ .

The reduction may likely be in part due to antimicrobial effect of ammonia rich secretion produce by the maggots. The inhibition of bacteria means massive necrosis due to bacteria is reduced. This work may help explain the beneficial effect of maggot during the debridement therapy. Maggots produce slower and organized breakdown of tissue presumably during MDT by probably preventing voracious bacterial induced necrosis. Despite the comparatively higher bacterial induced necrosis, maggot still possess powerful enough proteolytic cocktail released unto tissue to cause break down of even tough tissue like the sequestrum formed in chronic osteomyelitis (Mumcuoglu, 1998).

## CONCLUSION

Maggot infestation prevents massive necrosis in the tissue. Secretion from the larvae in saprophagous feeding may account for this finding. The antimicrobial ammonium rich secretion which may result in less bacterial colonization of the pig skin and less of the voracious bacterial induced necrosis has been reported (Robinson and Baker, 1959). This finding is a point worthy of note in forensic evaluation of necrotic tissues, considering whether they were infested by maggots of *Lucilia sericata* used in this study.

## REFERENCES

1. Baer W.S. (1993). The treatment of chronic osteomyelitis with the maggot (larvae of the blowfly). *Journal of Bone and Joint Surgery*. 13: 438.
2. Hewitt, F. (1932). Osteomyelitis: Development of the use of maggots in treatment. *Am J Nursing*. 32: 31-38
3. Mumcuoglu, K.Y., Ingber, A., Gilead, L., Stessman, J., Friedmann, R., Schulman, H., Bichucher, H., Ioffe-Uspensky I, Miller J, Galun R, Raz I (1998). Maggot therapy for the treatment of diabetic foot ulcers. *Diabetes Care*. 21(11): 2030-31.
4. Mumcuoglu, K.Y., Lipo, M., Ioffe-Uspensky I, Miller, J., Galun, R. (1997) [Maggot therapy for gangrene and osteomyelitis] (in Hebrew). *Harefuah*. 132:323-5,382.
5. Namias, N., Varela, E., Varas, R.P., Quintana, O., Ward, C.G. (2000). Biodebridement: a case report of maggot therapy for limb salvage after fourth-degree burns. *J Burn Care Rehabil*. 21 (3):254-257.
6. Pechter, E.A. and Sherman, R.A. (1993). Maggot therapy: The Medical Metamorphosis. *Plastic and Reconstructive Surgery*. 72 (4): 567-570.
7. Robinson, W. and Baker F.C (1939). The Enzyme Urease and the Occurrence of Ammonia in Maggot-Infected Wounds.
8. Sherman, R.A, Wyle, F.A., & Thrupp, L. (1995). Effect of antimicrobial agents on the growth, feeding and development of *Lucilia sericata* (Calliphoridae, DIPTERA).