

## Expression of Alkaline Phosphatase by periodontial tissue treated with topical application of VEGF and TGF-β1

Athraa Yahya Al-Hijazi<sup>1</sup> Abdul Karim Abed Ali Al-Mahammadawy<sup>2</sup>

1. Professor Oral histology and biology, College of Dentistry, University of Baghdad
2. Lecturer Department periodontic, College of Dentistry, University of Baghdad  
E-Mail: athraayms@yahoo.com

### Abstract

Growth factors are able to regulate significant cellular events in tissue regeneration and repair in periodontium injury. VEGF is a key regulator of physiological and pathological angiogenesis, because it induces endothelial cell proliferation, stimulates angiogenesis and TGF-β1 effects on cell growth, biological interactions and receptor binding abilities. Both factors maintain periodontal health and affected on the expression of ALP by periodontal tissue.

The aim of the present study To identify the biological events for expression of ALP by application of VEG and TGF-β1, in periodontial healing.

Eighteen male Albino rats were subjected for non surgical operation of distal sides of both lower anterior teeth, right side was considered as experimental site treated with 1µm of a combination of VEGF and TGF, while left be the control and treated with 1µm of normal saline.

All the samples were studied immunohistochemistry for identification alkaline phosphatase at three periods 3,7,14 day postoperatively.

The results demonstrated a higher records of positive gingival epithelial cell, stromal cell, PDL cell and bone cell that expressed strong immune-reaction of ALP in combined (VEGF & TGF-β1) group in comparison to control.

**Conclusion.** The present study suggested that using of a combination of VEGF and TGF in injured periodontium is a powerful tool in regenerative of periodontium tissue, by strong expression of ALK by epithelial and connective cells.

**Keywords:** vascular endothelial growth factor; periodontium healing, alkaline phosphatase, transforming growth factor.

**Abbreviations :** vascular endothelial growth factor (VEGF), periodontal ligament (PDL), alkaline phosphatase (ALP), transforming growth factor (TGF).

### 1. Introduction

After periodontium injury occurs, healing proceeds in a succession of cell-cell and cell-extracellular matrix interactions. In the process of normal wound healing, the growth factors act in conjunction to form a complex arrangement of molecules that regulate cellular activity and bordering the wound (Polimeni, et al 2006).

The aim of periodontal therapy is to regenerate and restore the various periodontal components affected by disease to their original form, function, and consistency (Yun, et al 2010). Regeneration requires restoration of alveolar bone height to the cemento-enamel junction, regeneration of gingival connective tissue destroyed by inflammation, formation of new cementum on previously exposed root surfaces, synthesis of Sharpey's fibers and their insertion into root surfaces, and re-establishing epithelial seal at the coronal portion. The activity of alkaline phosphatase (ALP) is considered to indicate the presence of osteoblast cells, osteoprogenitor and the formation of new bone. In many study this enzyme was investigated in cells of regenerated periodontal tissue underlying treated by guided tissue regeneration (GTR), Kuru, et al 1999; Stucki, et al 2001.

The new therapeutic approaches available to achieve these objectives include use of barrier membranes for guided tissue regeneration, and applying growth factors (Pisoschi et al., 2010 Buduneli & Kinane, 2011).

Vascular endothelial growth factor (VEGF) represents a specific mitogen of endothelial cells in vitro and an inducer of angiogenesis in vivo (Ferrara, 2000). While TGF-1 exhibits both pro-inflammatory and anti-inflammatory properties besides its ability to stimulate synthesis of ECM molecules and to inhibit the breakdown of ECM, it has been intensively evaluated in relation to periodontal healing (Banita, et al 2011).

The present study was designed to examine the biological effect of the topical application of growth factors VEGF and TGF-β1 in periodontal wound that prepared by deprived of periodontal ligament, bone and cementum layers in non surgical curette technique, and to study the expression of ALP by periodontium.

### 2. Materials and Methods

#### 2.1 Materials

\*VEGF165A protein (Rat)(ab51967), lyophilised form From abcam company

\*TGF beta 1 protein (Active) (ab50036), lyophilised form From abcam company.

\* Anti-Alkaline phosphatase, Tissue Non-specific antibody from Abcam company UK(ab65834).

\*Detection Kits System ,Abcam company England(ab64259)

## 2.2 Experimental animal

Eighteen male Albino rats, weighting (300-400)gram, aged(6-8)months were used and maintained under control conditions of temperature, drinking and food consumption and according to the National Research Council's guide for the care and use of laboratory animals. The animals were subjected for non surgical operation of distal sides of both lower anterior teeth( right side was considered as experimental site ,while left be the control one).

## 2.3 Methods

### 2.3.1.Assessment for the subgingival depth to create a periodontium defect

Before starting the experiment ,histologic and radiographic examinations were done to ten samples of lower jaw carrying the central teeth of normal intact rats( excluded from the designed number) to get a data base on the estimation of a proper sub gingival depth related to rats that allowed and supported the study to create a periodontium defect includes alveolar bone, cementum and periodontal ligament.

### 2.3.2. Non Surgical Technique

The non surgery was performed under a well sterilized condition and gentle technique. Every animal was weighted to calculate the dose of general anesthesia that was given to it. The general anesthesia was induced by Intra muscular injection of xylazine 2% (0.4 mg/kg B.W.), plus keta mine HCL 50mg (40 mg/kg- B.W.). Then the animal was placed on the surgical table and the surgical towel was placed under the site of the operation .Using Cavitron Ultrasonic Scaler with a stopper to 0.2 mm( depth assess from our present data) and with focused spray design that inserts direct water down into the pocket in which it helps to flush away debris., periodotium defect was made. Removing thin cementum layer, alveolar bone layer and tearing in periodontal ligament for both distal sides of lower anterior teeth, experimental and control sites.After operation a radiographic films were taken to confirm our work .

Drying the area by air, then applied a combination of both VEGF and TGF- $\beta$ 1 1 $\mu$ m,while normal saline 1  $\mu$ m was used for control. The animals were scarified at intervals 3,7,14 day ,using over dose anesthesia . Six animals for each period. the lower jaw was dissected and fixed in10% buffered formalin.

### 2.3.3 Assessment of Immunohistochemistry results

Positive reading was indicated when the cells display a brown cytoplasmic stain, while negative reading was indicated for absence of immune-reactions depends on positive and negative control.

#### 2.3.3.1 Immunohistochemical scoring for positive cells expressed ALP.

Quantification method. Of Immunoreactivity was semiquantitatively estimated the immune-staining score that was calculated as the sum of a proportion score and an intensity score. The proportion score reflects the estimated fraction of positively stained infiltrating cells (score 0, none; score 1, <10%; score 2, 10-50%;score 3, 51-80%; score 4, >80%). The intensity score represents the estimated staining intensity (score 0, no staining; score 1, weak; score 2,moderate; score 3, strong) ,Hillmann, et al 1999.

## 3.Results and Discussion

Periodontial tissue have heterogeneous cellular constituents ,the cell with indicative of a highly undifferentiated state, express high alkaline phosphatase activity (Luan,etal 2006)

The results for control group illustrate a positive expression for ALK marker by prickle cell of gingival epithelia at 3 day period. At 7 and 14 days osteoblast of woven bone,fibroblast expressed faint ALK immune-reaction,while sulcular epithelia shows a negative DAB stain,figures(1.2.3.4,5). Groeneveld ,etal 1995 established the spatial distribution of ALP activity and assessed the activity of the enzyme quantitatively in the periodontium of the rat maxillary molars, a highest activity was found in areas related to mineralization, adjacent to the alveolar bone and cementum and inner part, adjacent to the tooth, while a negative results was found in outer part .

The experimental combination group illustrates strong positive localization of ALp by all epithelial layers of gingival at 3 day,and strong positive by osteoblast and sulcular epithelia,figures(6,7,8).Fibroblast ,endothelial cells of repaired periodontal ligament shows a positive immune-reaction for ALp,figure(9).These results may attributed that VEGF could have a direct effect on osteoprogenitor cells, mainly by promoting the differentiation of osteoblasts and by increasing the mineralisation of the regenerated bone that expressed strong ALK ( Keramaris,etal 2002) .In addition to the ability of exogenous transforming growth factor-beta (TGF - $\beta$ 1) to induce osteogenesis critical events in both bone formation and fracture healing (Olivos-Meza,etal 2010 and Kasagi and Chen,2013)

Sulcular epithelium resembles a non-keratinized extension of the oral epithelium, and is continuous with the junctional epithelia .In present study sub-sulcular connective tissue shows numerous active formation of new blood vessels, enhance proliferation of sulcular epithelia that shows strong ALK expression.

Statistic analysis revealed a higher records in the mean value of cells that expressed positivity for ALP of experimental combined group in comparisum to control,with a highly significant value,and the stromal cell showed to be more affected ,tables(1&2),figure(10).

The present study highlighted on the ability to deliver a combination of growth factors in a manner to form biocompatible scaffolds to sites of tissue regeneration that promote angiogenesis and osteogenesis and it offers significant therapeutic opportunities for a variety of tissue engineered scaffold.

#### 4.Conclusion

Topical application of a combination of VEGF and TGF enhanced periodontium cells for expression of ALK that include epithelial and connective tissue .

#### References

- Banita, M., Pisoschi, C., Stanciulescu, C., Mercut, V., Scricieiu, M., Hancu, M. & Craitoiu, M. Phenytoin-induced gingival overgrowth – an immunohistochemical study of TGF-B1 mediated pathogenic pathways, *Farmacia*; 2011. 59(1): 24-33.
- Buduneli, N. & Kinane, D.F. Host-derived diagnostic markers related to soft tissue destruction and bone degradation in periodontitis. *Journal of Clinical Periodontology*.2011,Vol.38, Suppl.11,pp. 85-105
- Ferrara N. Vascular endothelial growth factor and the regulation of angiogenesis. *Recent Prog Horm Res*. 2000;55:15–35.
- Groeneveld MC, Everts V, Beertsen W Alkaline phosphatase activity in the periodontal ligament and gingiva of the rat molar: its relation to cementum formation. *J Dent Res*. 1995 Jul;74(7):1374-81.
- Hillmann,G;Gebert,A;Geurtsen,W. Matrix expression and proliferation of primary gingival fibroblasts in a three dimensional cell culture mode. *Journal of Cell Science* .1999.112: 2823-2832.
- Kasagi,Sh and Chen W .TGF-beta1 on osteoimmunology and the bone component cells. *Cell Biosci*. 2013; 3: 4.
- Keramaris ,N; Calori ,G; Nikolaou,V; Schemitsch,E. Fracture vascularity and bone healing: A systematic review of the role of VEGF *Injury*.2002, 39, Issue null: S45-S57.
- Kuru L, Griffiths GS, Petrie A, Olsen I. Alkaline phosphatase activity is upregulated in regenerating human periodontal cells. *J Periodontal Res*. 1999 Feb;34(2):123-7.
- Luan,X;Ito,Y;Dangaria,S;Diekwisch,Th.*Dental Follicle Progenitor Cell Heterogeneity in the Developing Mouse Periodontium Stem Cells and Development*. 2006, 15(4): 595-608.
- Olivos-Meza ,A; Fitzsimmons ,J; Casper ,M; Chen,Q. Pretreatment of periosteum with TGF-β1 *in situ* enhances the quality of osteochondral tissue regenerated from transplanted periosteal grafts in adult rabbits Osteoarthritis Cartilage. 2010 September; 18(9): 1183–1191.
- Pisoschi, C., Banita, M., Gheorghita, L., Stanciulescu, C., Craitoiu, M. & Fusaru, A.M. Salivary Transforming Growth Factor 1 – a possible risk factor for gingival overgrowth. *Archives of the Balkan Medical Union*.2010. 45(1):18-22.
- Polimeni, G;Xiropaidis,A;Wikesjo,U. *Biology and principles of periodontal wound healing/regeneration Periodontology 2000*.2006 Volume 41, Issue 1, pages 30–47.
- Stucki U, Schmid J, Hämmerle CF, Lang NP.Temporal and local appearance of alkaline phosphatase activity in early stages of guided bone regeneration. A descriptive histochemical study in humans. *Clin Oral Implants Res*. 2001 Apr;12(2):121-7.
- Yun, Y.R., Won, J.E., Jeon, E., Lee, S., Kang, W., Jo, W., Jang, J.H., Shin, U.E. & Kim, H.W. Fibroblast Growth Factors: Biology, Function, and Application for Tissue Regeneration *Journal of Tissue Engineering*, 2010, Article ID 218142, page,18.

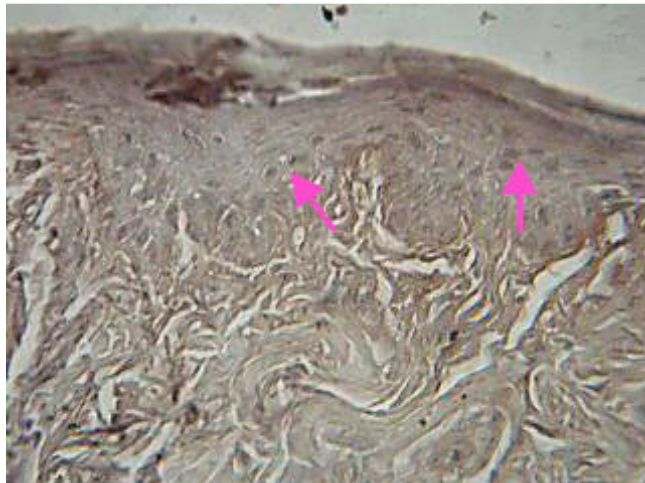


Figure (1) Faint stain for (ALP) in control group expressed by prickle cell (arrow) of epithelial of gingiva . DAB stain x40

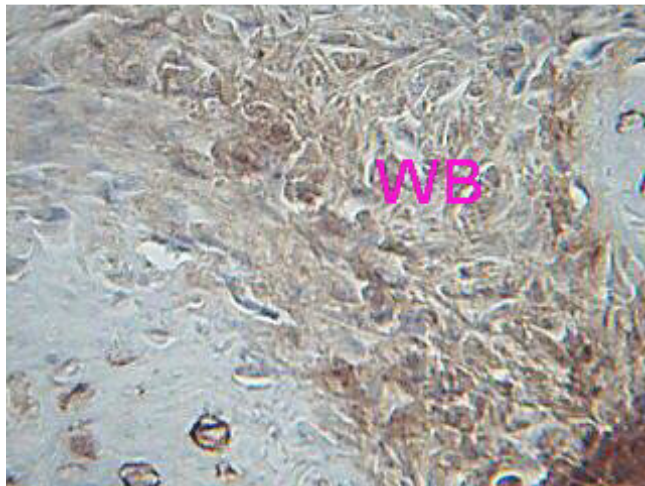
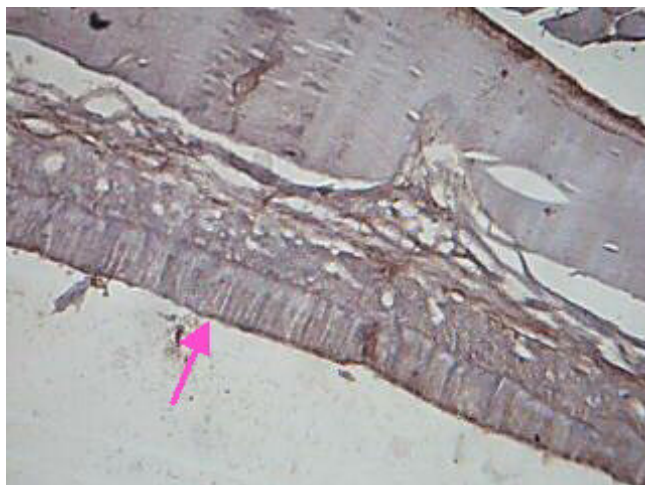
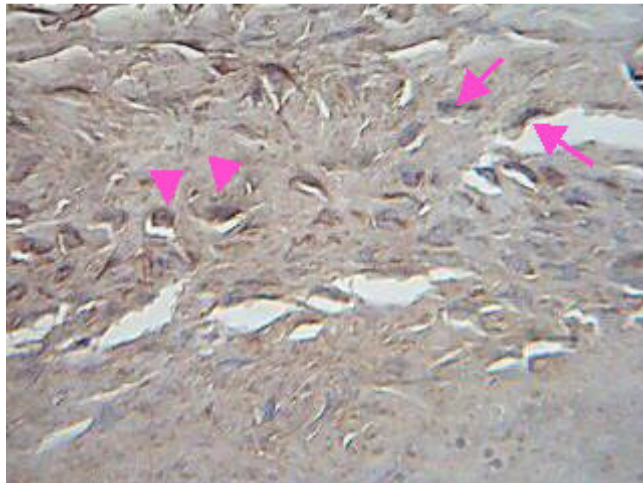


Figure (2) woven bone (WB) expressed faint immuno- reaction for (ALP). DAB stain x40



Figure(3) Negative expression for ALP by sulcular epithelia in control x40



Figure(4) Osteoblast (arrows) osteocyte (arrow heads) in newly formed bone expressed positive (ALP) immunoreactions. DAB stain x40

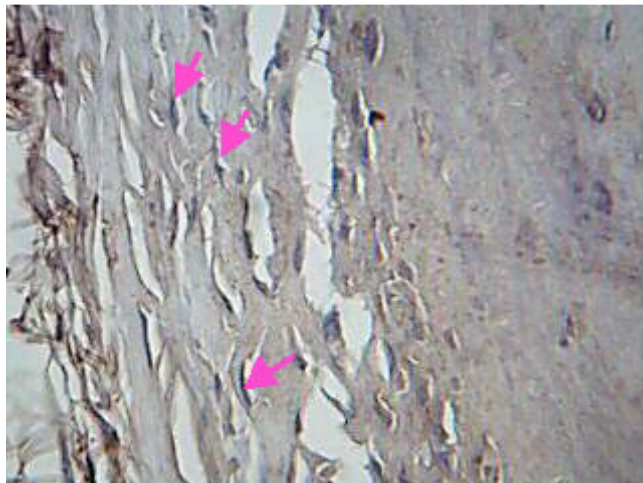


Figure (5) Fibroblast (arrows) show positive expression of (ALP). DAB stain x40

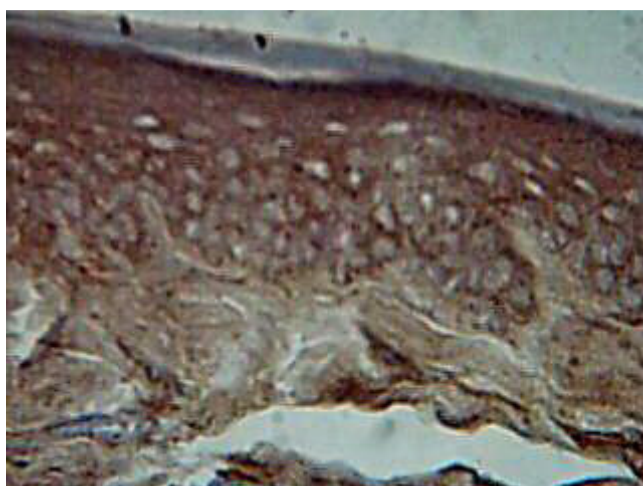


Figure (6) Epithelia cell of gingival tissue of experimental group expressed strong positive (ALP) immunoreactions. DAB stain x40

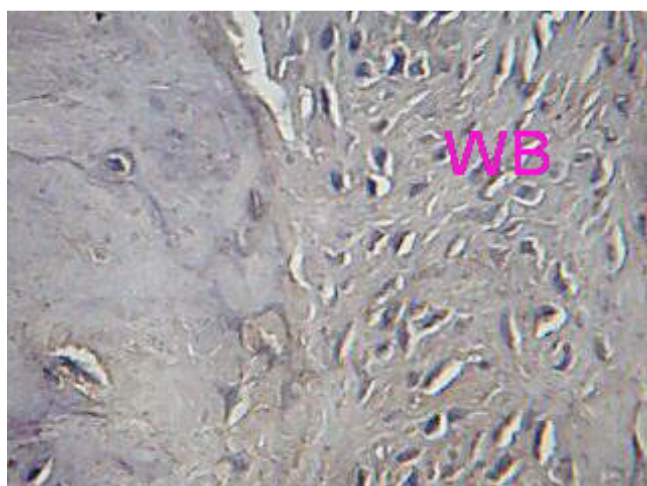


Figure (7) Cells within woven bone (WB) express (ALP) and show positive DAB stain. DAB stain x40



Figure (8) Sulcular epithelia (arrow ) strongly stained for expression of (ALP) DAB stain x40

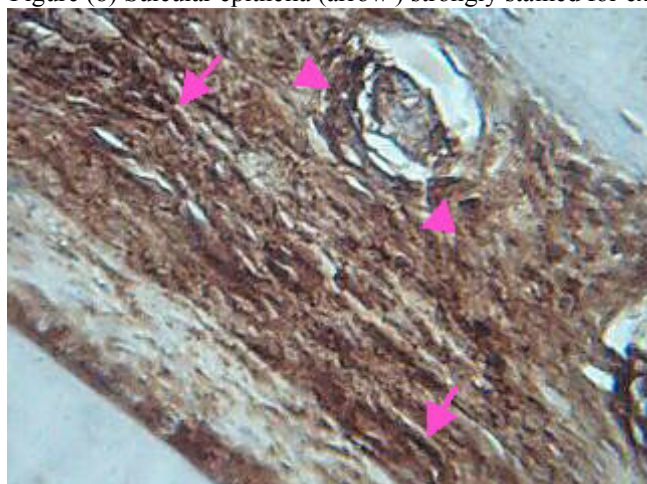
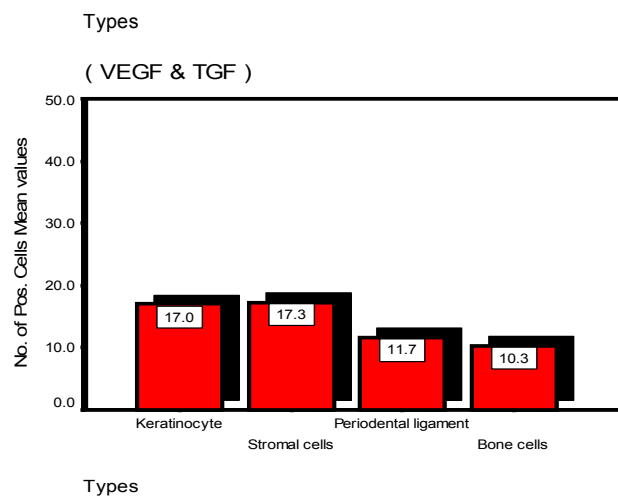
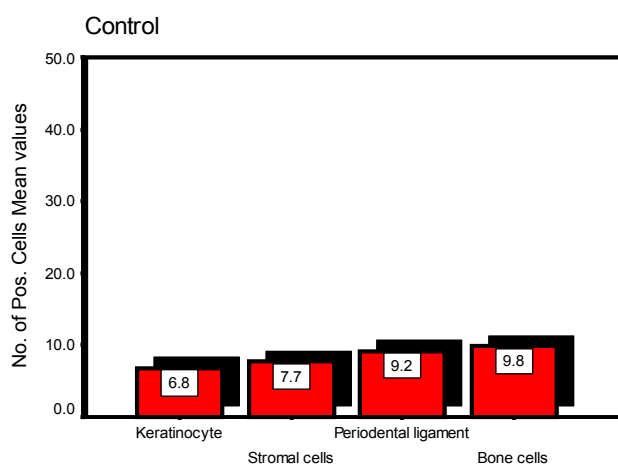


Figure (9) Fibroblast (arrows), endothelial cell (arrow heads), positively stained for (ALP). DAB stain x40

**Table (1): Summary Statistics of the Studied No. of Positive Cells for ALK Marker in the Studied Groups**

Marker	Groups	No. of Positive :	No.	Mean	Std. Dev .	Std. E.	95% C. I. for Mean		Min.	Max.
							L.B	U.B.		
Alkaline Phosphates	Control	Keratinocyte(Ging.)	6	6.8	1.0	0.4	5.8	7.9	6	8
		Stromal cells(Ging.)	6	7.7	0.5	0.2	7.1	8.2	7	8
		Periodontal ligament	6	9.2	1.3	0.5	7.8	10.6	8	11
		Bone cells	6	9.8	1.0	0.4	8.8	10.9	8	11
	( VEGF & TGF )	Keratinocyte(Ging.)	6	17.0	2.1	0.9	14.8	19.2	14	20
		Stromal cells(Ging.)	6	17.3	3.0	1.2	14.2	20.5	14	20
		Periodontal ligament	6	11.7	1.5	0.6	10.1	13.3	10	14
		Bone cells	6	10.3	1.5	0.6	8.8	11.9	8	12



**Figure (10): Bar charts for the estimated overall means values for the Studied No. of Positive Cells for ALK in the Studied Groups**

Table (2): Multiple Comparisons by (LSD Method) among all pairs of different (S.O.V.) effect's on Positive Cells in compact form

<b>LSD test</b>				
<b>Factor</b>	<b>(I) group</b>	<b>(J) group</b>	<b>Sig.<sup>(*)</sup></b>	<b>C.S.</b>
<b>Groups</b>	<b>control</b>	<b>( VEGF &amp; TGF )</b>	<b>0.000</b>	<b>HS</b>
<b>Types of cells</b>	<b>Keratinocyte</b>	<b>Stromal cells</b>	<b>0.000</b>	<b>HS</b>
		<b>Periodontal ligament</b>	<b>0.000</b>	<b>HS</b>
		<b>Bone cells</b>	<b>0.634</b>	<b>NS</b>
	<b>Stromal cells</b>	<b>Periodontal ligament</b>	<b>0.000</b>	<b>HS</b>
		<b>Bone cells</b>	<b>0.000</b>	<b>HS</b>
		<b>Periodontal ligament</b>	<b>Bone cells</b>	<b>0.000</b>