

# Anatomical and Histological Study of Glands in Uterine cervix of Black Goat (*Capra hircus*)

Kamal Ali Salih<sup>1\*</sup> and Kasim Sakran Abass<sup>2</sup>

<sup>1</sup>Department of Anatomy and Histology, College of Veterinary Medicine, University of Kirkuk, Kirkuk, Iraq

<sup>2</sup>Department of Basic Nursing Sciences, College of Nursing, University of Kirkuk, Kirkuk, Iraq

\*All corresponding to Dr. Kamal Ali Salih

Email: [kamalalbiaty@yahoo.de](mailto:kamalalbiaty@yahoo.de)

Tel: +9647702363861

## Abstract

The purpose of this study was to look for morphological and histological effects of the glands in the uterine cervix uteri of indigenous goat as well as study the evidenced by light microscopy. Simple tubular, branched glands were observed in the cervix uteri of the indigenous goats. It was concluded that the cervical mucus in the goat was produced by the cervical glands in addition to the surface epithelium of cervical mucosal lining. Finally, results obtained from these studies may suggest the suitability of uterine cervix glands for produced the cervical mucus in black goat tissues.

**Key words:** Black goat, glands, anatomical, histological

## 1. Introduction

A cervix uterus is the lower, narrow portion of the uterus where it joins with the top end of the vagina. It is cylindrical or conical in shape and protrudes through the upper anterior vaginal wall (Klaes et al., 2001; Miessen et al., 2012; Sarmadi et al., 2012). Its play an important roles as a sphincter of the uterus. During menstruation the cervix stretches open slightly to allow the endometrium to be shed (Harris et al., 1980; Ravarino et al., 2012).

The uterine cervical epithelium protects the upper reproductive tract from insults providing a physical barrier, secretions containing bactericidal and virucidal agents and a pathogen-dependent direct immunomodulation (Quayle, 2002). During estrous, it takes part in direct sperm-epithelium interaction (Song *et al.*, 2010), as well as in the signal reception from seminal fluid (Robertson, 2007). Cervical cell cultures of a variety of species are already applied in various fields of science. They serve as in vitro systems for basic research (Sharkey *et al.*, 2007), in oncological and microbiological studies (Guseva *et al.*, 2003), as well as for assessment of product-and pharmaco-toxicity (Krebs *et al.*, 2002). At the end the objective of the paper was to study the morphology of the glands in cervix uteri of indigenous goat as well as investigate the evidenced by light microscopy.

## 2. Materials and Methods

### 2.1 Chemicals

Absolute alcohol,  $\geq 99.8\%$  purity, [chemical name: ethyl alcohol, molecular structure:  $\text{CH}_3\text{CH}_2\text{OH}$ , molecular mass:  $46.6 \text{ g mol}^{-1}$ ] was purchased from Fluka, Germany. While eosin, 98% purity, [chemical name: 2',4',5',7'-Tetrabromofluorescein, molecular structure:  $\text{C}_{20}\text{H}_3\text{Br}_4\text{O}_5$ , molecular mass:  $647.89 \text{ g mol}^{-1}$ ] obtained from BDH, UK. All other reagents and solvents used in this paper were of analytical grade.

### 2.2 Animals

Experiments were conducted on twelve black goats (*Capra hircus*). The goats were purchased from Kirkuk inhabiting the northern part of Iraq. All goats were adult non-lactating females and were kept under continuous veterinary supervision. The body weight of the black goats used in this study ranged from 15 to 20 kg and kept in room with dimensions of 5 x 5 x 5 m with constant lighting at a temperature of 25-35 °C and relative humidity was between (40-45%), which was controlled by electric heaters. The floor litter consisted of wood shavings; water and feed were available ad libitum. This supplementation was made in order to enable the goats to maintain their body weight at its initial value, following their failure to do so when fed wheat straw only. The age of the goat used in the experiments ranged between 6 months to 3.5 years. The present study has been approved by the Scientific Committee of the College of Veterinary Medicine at the University of Kirkuk (Iraq). All the experiments observed with institutional regulations addressing animal use, and good attention and care were given to the goats used in this work.

### 2.3 Experiment procedure

Shortly after evisceration the whole genital tract was removed from the carcass, the cervix excised and opened and slices from representing middle part of the cervix fixed in 10% neutral formalin and processed for dehydration and subsequent infiltration and were embedded in paraffin wax. The sections of 6  $\mu$ m thickness are stained by mayer's haematoxylin and eosin, were examined by light microscope to study the presence of glands in these tissues.

### 3. Results

The cervical glands were appeared as invaginations at the surface epithelium into the lamina propria layer. These invaginations almost present at the base of the furrows between cervical folds (Figure1). Likewise, these furrows extend short distance in the lamina propria in youngers of six months of age, and showed branching at their base, and more elongated branched glands seen in more adults (Figures 2 and 3). However, the course of these glands was oblique and presented like crypts extending from the surface epithelium through the lamina propria. The simple columnar cells of the surface epithelium extends with the lining of these glands, but were taller with basal oval nuclei. These glands showed further branching in the depth of lamina propria near the muscular layer of the cervix uteri of 3.5 years aged goat (Figure 4). The age accompanied with changes revealed that the glands were less developed in younger, there was increased branching in the older, showing great development depending upon sexual maturity of the animal.

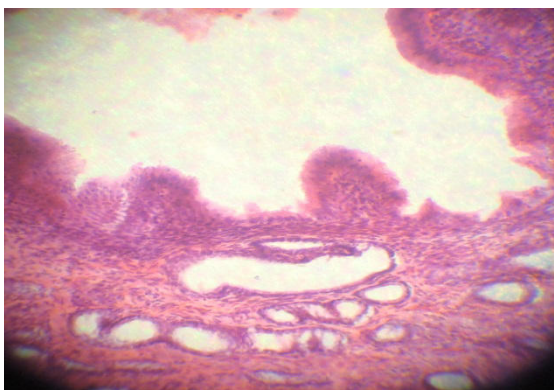


Figure 1. Cervix uteri of 6 months aged goat shows invaginations of gland opening in the surface epithelium towered the lamina propria (H & E  $\times$  120).

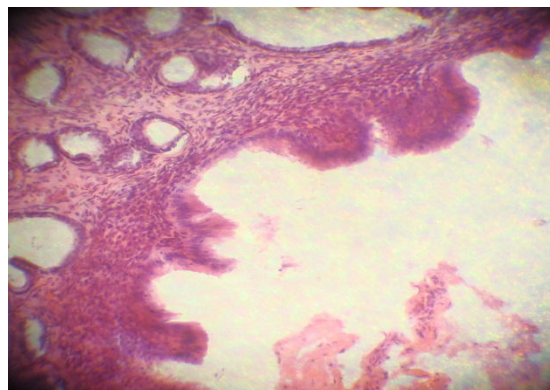


Figure 2. Cervix uteri of 6 months aged goat shows short extended and less branched glands (H & E  $\times$  120).

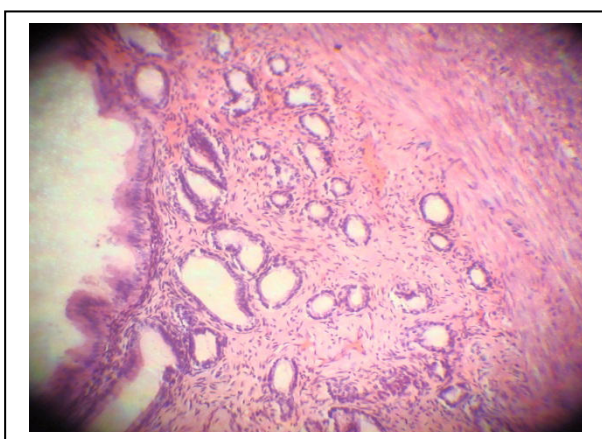


Figure 3. Cervix uteri of 9 months aged goat shows more branched glands (H & E  $\times$  120).

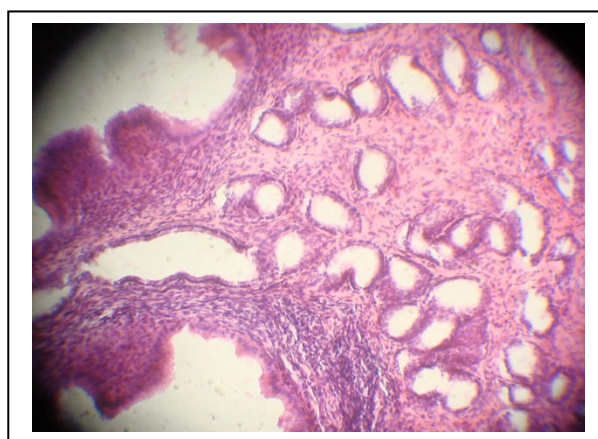


Figure 4. Cervix uteri of 3.5 years aged goat shows further branching in the depth of lamina propria (H & E  $\times$  120).

#### 4. Discussion

The present finding was glands in the cervix uteri of goats, which was simple tubular and branched appeared as invaginations of the surface epithelium toward lamina propria. These structures are in agreement with the report of (Joshi *et al.*, 1975), whom they observed the glands of cervix uteri chiefly as simple tubular branched in goat and Caspian Miniature Horse previously. But this finding of glands type are not in agreement with observation of (Dellmann *et al.*, 1968), who described these glands as simple tubular coiled type in the same animal. In present investigation these glands gave clear evidence of branching in almost all sections. However, in some of the locations which gave an appearance similar to which considered by (Dellmann *et al.*, 1968), as the sectioned coiled glands were evidenced to be form branched tubular, because the appearance of glands in sections as seen in some planes obtained if the branched glands are cut through a plane as indicated by other line. Fluhmann (1961) suggested that the cervical epithelial structures of endocervical mucosa was indicate system of clefts or crypts, which are together gave an illusory impression of glands. He added that the crypts may run in a transverse and oblique plane. The evidence of bifurcation in present study agreed with (Fluhmann, 1961) view which have recently been supported by (Hafez *et al.*, 1972). Whilst discussing the cervical glands of primates formed a system of clefts that run in all directions over endocervical canal and these clefts ends by blind diverticula which coursed horizontally under the mucosa giving false impression during histological sections. That the cervical glands were classified from a type thus supporting the views of (Fluhmann, 1961).

#### References

- Dellmann H, Carithers R (1968). Glands in the cervix uteri of the domestic goat (*Capra hircus* L.). *American journal of veterinary research* **29**(7): 1509.
- Fluhmann F (1961). *The Cervix Uteri: And Its Diseases*. edn. WB Saunders.
- Guseva NV, Knight ST, Whittimore JD, Wyrick PB (2003). Primary cultures of female swine genital epithelial cells in vitro: a new approach for the study of hormonal modulation of Chlamydia infection. *Infection and immunity* **71**(8): 4700-4710.
- Hafez E, Jaszczak S (1972). Comparative anatomy and histology of the cervix uteri in non-human primates. *Primates* **13**(3): 297-314.
- Harris R, Brinton L, Cowdell R, Skegg D, Smith P, Vessey M, *et al.* (1980). Characteristics of women with dysplasia or carcinoma in situ of the cervix uteri. *British journal of cancer* **42**(3): 359.
- Joshi C, Nanada B, Saigal R (1975). Histomorphological and histochemical studies on the female genitalia of ageing goat. II. Glands in cervix uteri. *Anatomischer Anzeiger* **139**(1-2): 193-199.
- Klaes R, Friedrich T, Spitkovsky D, Ridder R, Rudy W, Petry U, *et al.* (2001). Overexpression of p16INK4a as a specific marker for dysplastic and neoplastic epithelial cells of the cervix uteri. *International journal of cancer* **92**(2): 276-284.
- Krebs FC, Miller SR, Catalone BJ, Fichorova R, Anderson D, Malamud D, *et al.* (2002). Comparative in vitro sensitivities of human immune cell lines, vaginal and cervical epithelial cell lines, and primary cells to candidate microbicides nonoxynol 9, C31G, and sodium dodecyl sulfate. *Antimicrobial agents and chemotherapy* **46**(7): 2292-2298.
- Miessen K, Einspanier R, Schoen J (2012). Establishment and characterization of a differentiated epithelial cell culture model derived from the porcine cervix uteri. *BMC Veterinary Research* **8**(1): 31.
- Quayle AJ (2002). The innate and early immune response to pathogen challenge in the female genital tract and the pivotal role of epithelial cells. *Journal of reproductive immunology* **57**(1): 61-79.
- Ravarino A, Nemolato S, Macciocu E, Fraschini M, Senes G, Faa G, *et al.* (2012). CINtec PLUS Immunocytochemistry as a Tool for the Cytologic Diagnosis of Glandular Lesions of the Cervix Uteri. *American journal of clinical pathology* **138**(5): 652.
- Robertson SA (2007). Seminal fluid signaling in the female reproductive tract: lessons from rodents and pigs. *Journal of Animal Science* **85**(13 suppl): E36-E44.

Sarmadi S, Izadi-mood N, Poursashkari M, Yarandi F, Sanii S (2012). HPV L1 capsid protein expression in squamous intraepithelial lesions of cervix uteri and its relevance to disease outcome. *Archives of gynecology and obstetrics* **285**(3): 779-784.

Sharkey DJ, Macpherson AM, Tremellen KP, Robertson SA (2007). Seminal plasma differentially regulates inflammatory cytokine gene expression in human cervical and vaginal epithelial cells. *Molecular human reproduction* **13**(7): 491-501.

Song C, Gao B, Wu H, Wang X, Chen G, Mao J (2010). Spatial and temporal expression of spermadhesin genes in reproductive tracts of male and female pigs and ejaculated sperm. *Theriogenology* **73**(5): 551-559.