

Results of orbital cellulitis treatment

Awuah Peter^{1*} Duah Issahalq Mohammed^{2*}

1. School of Medical Sciences, Kwame Nkrumah University of Science and Technology, Kumasi –Ghana.
2. School of Medical Sciences, Kwame Nkrumah University of Science and Technology, Kumasi –Ghana.

*E-mail: drawuah@yahoo.com

ABSTRACT

The research seeks to emphasize the importance of prompt surgical intervention in the management of complicated orbital cellulitis without over relying on CT Scans. A retrospective study that reviewed 36 patents with orbital complications arising as a result of sinusitis were admitted to the Ear, Nose, Throat and Eye ward of the main teaching hospital of the Ashanti Region-Komfo Anokye Teaching Hospital was done. The study analysis was from January, 2007 to October, 2010. The clinical presentations, laboratory examinations, diagnoses, management methods were analyzed. Appropriate evaluation of patients with orbital inflammation included a comprehensive clinical examination and radiographic studies. The age range of the study was 1-70 years with males more than females. The commonest sinus which was infected was the ethmoid. Relying on the soft tissues x-rays, prompt clinical assessment and immediate surgical intervention in a deprived area where CT Scans and ultrasonography are scarce gives 95% cure of patients. The findings of this study suggest that surgical intervention, especially trephening of the frontal sinus is a must, to avoid potential complications such as brain abscess and vision loss in orbital abscess.

KEY WORDS: Sinusitis, sinuses, orbital cellulitis.

INTRODUCTION

The paranasal sinuses are spaces within the bones of the skull and face, which are filled with air. The paranasal sinuses are set up in four pairs that are more or less symmetrical from left to right. The maxillary Sinuses are the largest of them, and are located under the eyes in the inner part of the cheek bones. The next largest are the frontal sinuses, located in the forehead above each eye. The ethmoid sinuses are much smaller and located behind either side of the bridge of the nose medial to the eyes. The sphenoid sinuses are located in the centre of the skull, behind the nose and the eyes. Sinusitis is characterized by inflammation of the lining of the paranasal sinuses. The vast majority of sinusitis are caused by viral infection and disease stage are caused by either obstruction of the sinus drainage pathway (sinus Ostia) or ciliary impairment. Due to the proximity of the sinuses to the nasal mucosa and its continuity, infection easily spreads to them causing serious morbidity. Orbital complications accounts for 74-85% of complications arising from acute sinusitis and usually this is secondary to acute ethmoidal sinusitis (Pengiran, Goh and Gendeh (2010). The orbit is easily involved in ethmoiditis because of a thin paper-like bone (lamina papyracia) that separates the two. Orbital complications of sinogenic origin can be either intracranial or extra cranial and must be treated aggressively with antibiotics and or plus immediate surgical intervention. Chandler described a widely accepted classification of orbital complications of acute sinusitis since 1970. A review of the literature showed that in Ghana no study had been conducted on the orbital complications of sinusitis. We report our experience with the diagnosis and treatment of patients admitted with orbital complications of sinusitis at Komfo Anokye Teaching Hospital.

METHODS

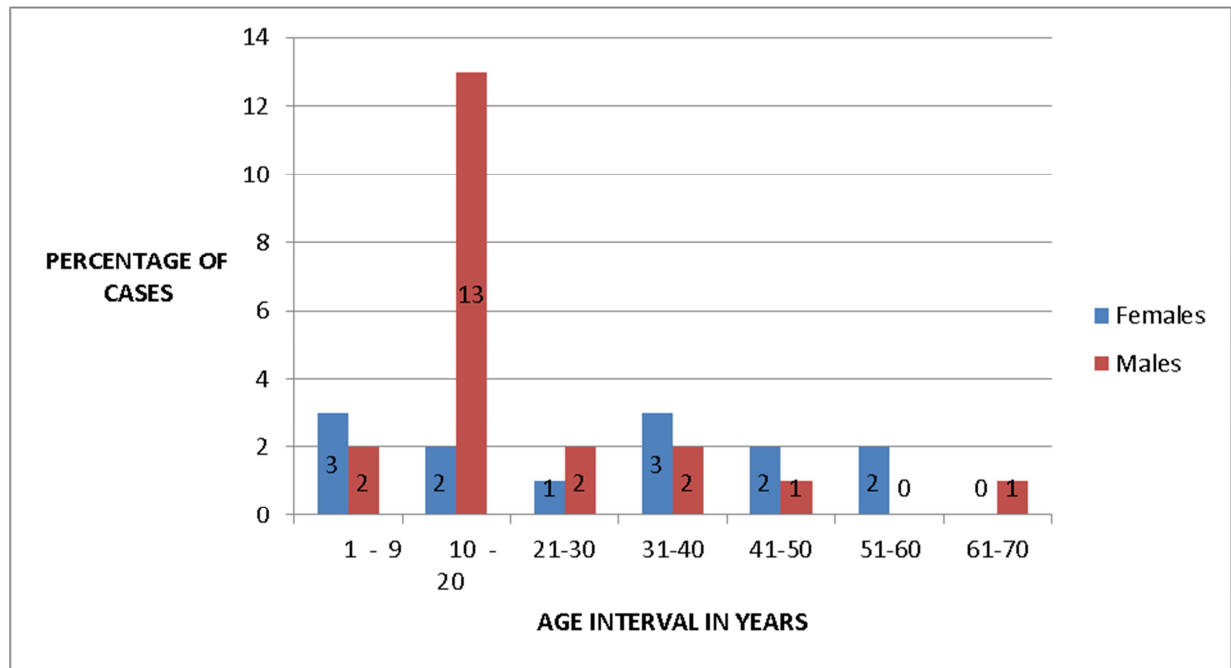
It is a Retrospective study of patients with sinusitis and its orbital complications at Komfo Anokye Teaching Hospital from January, 2007 to October, 2010. Orbital diseases not related to sinusitis were excluded from the study. Clinical examination tested for charges is visual acuity, pupillary reactivity, and extra ocular motion. Soft tissue X- ray was used for the diagnosis of orbital infections, its complications and meticulous clinical examination of the patient. CT scan and ultrasonography were not available. Chandler's (1970) classification of

orbital complications of sinusitis was used. The bacteriological etiology of the disease was determined in each case on the basis of the results of culture.

RESULTS

Of the total number of 36 cases, males dominated with a total number of 23(63.8%) and females were 13 (36.2%).The age ranges was between 1 and 70 years. Majority of the sinuses on the right side were more involved than the left.

Figure 1: Age and Sex Distribution of Patients with Orbital Complications of Sinusitis



At the time of admission the commonest presentations were; eyelid oedema and erythema 36(100%); Chemosis and engorged conjunctiva 36(100%); Proptosis 20(55.6%); Purulent rhinorrhoea 16(44.5%); Restricted extra-ocular mobility 14(38.8%); Vision loss 3(8.3%).There were constitutional symptoms of pulsating headache, fever and general malaise. All the patients underwent Soft Tissue X ray of the paranasal sinuses which showed sinusitis in all of them. The pattern was ethmoid 2(5.6%), Maxillary 1 (2.7%), Frontal 1(2.7), Ethmoid, Frontal and Maxillary 24 (66.7%), Ethmoid and Frontal 6 (16.7%), Ethmoid and Maxillary 2 (5.6), Sphenoid 0. The ethmoid sinus is commonly involved but multiple involvements of sinuses (66.7%) were the most common. Infections of sinuses on the right were more common than the left.

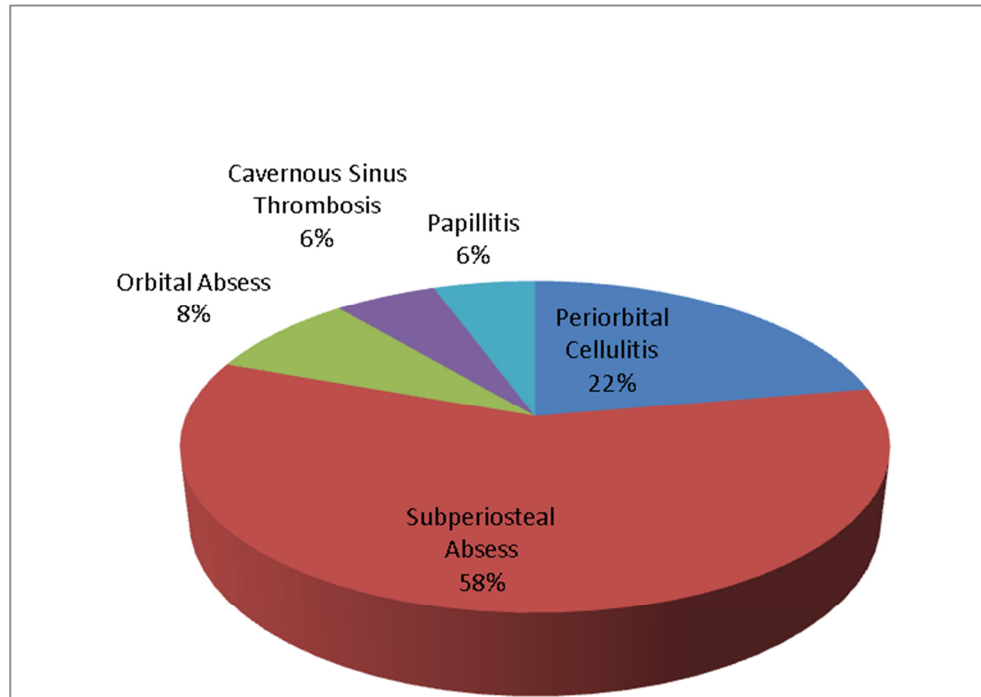
TABLE 1

STAGES OF DISEASE

	Number	Percentage
Periorbital Cellulitis (I)	8	22
Subperiosteal Abscess (II)	21	58
Orbital Abscess (III)	3	9.0
Cavernous Sinus Thrombosis (IV)	2	5.5
Papillitis (V)	2	5.5
TOTAL	36	100

As can be seen in Table 3 the Chandler system of classification showed periorbital 8 (22%), Supriosteal abscess 21(58%), Orbital abscess 3 (8%), Cavernous Sinus Thrombosis 2 (5.5%) and Papillitis 2 (5.5%). Figure 2 displays percentage of types of orbital complications. The pus culture report showed staphylococcus aureus (85%) as the most common pathogen followed by beta hemolytic streptococci (5%), H influenza (5%) and others (5%).

Figure 2: Percentage of Types of Orbital Complications



DISCUSSIONS

Acute sinusitis is most commonly seen in the pediatric age group and so are the Complications. The findings of this study are similar to those of previous studies done elsewhere with the highest incidence seen in the first and second decades (61%) with male preponderance. The Ethmoid sinus (94%) is most commonly seen to be involved in orbital complications of sinusitis followed by Frontal (86%) and Maxillary (75%) with the most common pattern of sinus involvement with the combination of Ethmoid, Maxillary & Frontal Sinuses (67%). Both eyes are commonly involved in this disease. But the right sinuses involvement is commoner than the left. All the 36 patients presented with Eyelid and erythema and edema of the conjunctiva of conjunctiva, 100%. All 36 had chemosis and engorged conjunctiva, 100%. 20 presented with proptosis. 55.6%. Those that presented with purulent rhinorrhoea were 16, (44.4%). Restricted extra-ocular mobility was 14, (38.3%). Only 3 patients presented with vision loss, 8.3%. CT Scan can detect and delineate the extent of involvement and demonstrate abscesses in the orbit. In this study it wasn't employed. We used the Plain sinus film which is useful in older children and adults, but in children under 2 years of age, there is considerable variation in the interpretation of roentgenographs. Majority of the patients developed subperiosteal abscess 58%, followed by Periorbital cellulitis 22%. However orbital abscess was 8% and Cavernous Sinus thrombosis was 6%. All the patients that had cavernous sinus thrombosis died after a prolonged treatment. The first line of treatment on admission is intravenous antibiotics, Benzyl penicillin and Metronidazole or Cephalothin in high doses. All the patients in group I (Chandler) improved with antibiotics alone without surgical intervention. The surgical intervention was indicated in patients belonging to group II, III, IV and V (Chandler). The surgical intervention may be in the form of;

- a) Incision And Drainage b) Intra-nasal antrostomy. c) Frontal sinus trephening. D) Internal And External Ethmoidectomy.

CONCLUSIONS

Optimal management of patients with orbital cellulites depends on how accurately the disease is classified and on the appropriateness of which antibiotics and surgery are used to treat the disease. Indeed orbital complications has a good prognosis when detected early and managed appropriately. Prompt recognitions as well as aggressive treatment avoids potential morbidity of blindness.

The presence of an abscess, which was ultimately found at surgical exploration, was not diagnosed by the plain x-rays in most of these patients. Clinical examination remained the most important indicator for surgical intervention in patients with orbital complications of sinusitis. Again, parenteral antibiotic is the mainstay of treatment with emergency surgical drainage indicated in the presence of abscess.

In Hospitals where CT Scans and Ultrasonographic equipments are not available the reliance on Plain X-rays with meticulous examination and early simple trephening give almost 90% success in management of sinusitis and its orbital complications.

REFERENCES

- 1) Lavania A , Sharma V ,Reddy N S , Baksh R .Orbital cellulites: A Complication Of sinusitis; Kathmandu University medical journal 2005 Jul; 3(3):292-293.
- 2) S Elango, Krishna Reddy TN. Orbital complications of acute sinusitis. Singapore Medical journal 1990 31:341-344
- 3) Nwaorgu OGB, Awobem FJ, Onakoya PA, Awobem AA. Orbital cellulitis Complicating sinusitis: A 15 year review. Nigerian journal of surgical research.2004 6(1):14-16.
- 4) Younis RT, Lazar RH, Bustillo A, Anand VK. Orbital infection as a complication Of sinusitis: are diagnostic and treatment trends changing? Ear Nose Throat J. 2002 Nov;81(11):771-5
- 5) Haq M. U., Hussain S.; Pakistan journal of medical science Vol 25 April –June 2009 No 2:308-312.
- 6) Chandler JR, Langenbrunner DJ, Stevens ER. The pathogenesis of orbital Complications in acute sinusitis. Laryngoscope. 1970 Sep; 80(9):1414-28.
- 7) Tanna N., Preciado D.A.A.,Clary M.S., Choi S.S.; Surgical treatment of subperiosteal abscess ; Arch Otolaryngology Head and Neck Surg .2008;134(7):764-767.
- 8) Patt BS, Manning SC. Blindness resulting from orbital complications of Sinusitis. Otolaryngol Head Neck Surg. 1991 Jun; 104(6):789-95.
- 9) Schramm VL Jr, Curtin HD, Kennerdell JS. Evaluation of orbital cellulitis and Results of treatment. Laryngoscope. 1982 Jul; 92(7 Pt 1):732-8.
- 10) Schramm VL, Myers EN, Kennerdell JS. Orbital complications of acute Sinusitis: evaluation, management, and outcome. Otolaryngology. 1978 Mar-Apr; 86(2):ORL221-30.
- 11) Gans H, Sekula J, Wlodyka J. Treatment of acute orbital complications. Arch Otolaryngol. 1974 Nov;100(5):329-32

12) Osguthorpe JD, Hochman M. Inflammatory sinus diseases affecting the orbit. *Otolaryngol Clin North Am.* 1993 Aug; 26(4):657-71.

13) Godwin WJ. Orbital complications of ethmoiditis. *Otolaryngol Clin North Am.* 1985;18:139-47

14) Sütbeyaz Y, Aktan B, Yoruk O, Ozdemir H, Gundogdu C. Treatment of sinusitis with corticosteroids in combination with antibiotics in experimentally Induced rhinosinusitis. *Ann Otol Rhinol Laryngol.* 2008 May;117(5):389-94.

This academic article was published by The International Institute for Science, Technology and Education (IISTE). The IISTE is a pioneer in the Open Access Publishing service based in the U.S. and Europe. The aim of the institute is Accelerating Global Knowledge Sharing.

More information about the publisher can be found in the IISTE's homepage:

<http://www.iiste.org>

The IISTE is currently hosting more than 30 peer-reviewed academic journals and collaborating with academic institutions around the world. **Prospective authors of IISTE journals can find the submission instruction on the following page:**

<http://www.iiste.org/Journals/>

The IISTE editorial team promises to review and publish all the qualified submissions in a fast manner. All the journals articles are available online to the readers all over the world without financial, legal, or technical barriers other than those inseparable from gaining access to the internet itself. Printed version of the journals is also available upon request of readers and authors.

IISTE Knowledge Sharing Partners

EBSCO, Index Copernicus, Ulrich's Periodicals Directory, JournalTOCS, PKP Open Archives Harvester, Bielefeld Academic Search Engine, Elektronische Zeitschriftenbibliothek EZB, Open J-Gate, OCLC WorldCat, Universe Digital Library, NewJour, Google Scholar

