

The Effects of Excess Consumption of Aqueous Seed Extract of *Piper Guineense* on the Duodenum of Adult Female Albino Rats

Akudike C.J.*¹ Ezejindu D.N.¹ Ndukwe G.U.²

1. Department of Anatomy, College of Health Science, Nnamdi Azikiwe University, Nnewi Campus, Nigeria
2. Department of Anatomy, Faculty of Basic Medical Sciences, Abia State University Uturu, Abia State, Nigeria

Abstract

The plant *Piper guineense* is indeed of great medicinal and culinary value. This study was carried out to ascertain the effect of excess consumption of aqueous seed extract of *Piper guineense* on the duodenum of adult female wistar rats. A group of 20 animals of 4 groups each were used to carry out this study. Group 1 served as control group, group 2, 3 and 4 served as experimental groups each receiving 1000mg/kg, 1500mg/kg and 2000mg/kg body weight of extracts respectively. The animals were administered this experimental product for a period of 28 days after which, they were sacrificed for organ harvesting and tissue processing. The results obtained revealed that there was a dose-dependent fragmentation of the intestinal epithelia lining as well as reduction in size of wall. This therefore suggests that *Piper guineense* can cause damages to the duodenum which can be irreparable whenever it is excessively consumed and so an excessive consumption should be warned against.

Keywords: Duodenum, Epithelia, Fragmentation, *Piper guineense*.

INTRODUCTION

The use of plants for varying purposes by man is of great essence as man's survival has been dependent on his increasing curiosity and desire to examine all aspects of his environments by trial and error methods to bring to conclusion which plants are of good nutritional value, medicinal or harmful to him (Ampofo and Romand, 1978; Ebeye *et al.*, 2007). In the year 1991, the 44th World Health Assembly approved the 44.34 Resolution which encourages all member countries of the World Health Organization (WHO) to promote the use of traditional, harmless, efficient and scientifically approved remedies (Pamplona-Rogers, 2004; Morah, 2007) and to this end, the World Health Organization (WHO) has continued to conduct and sponsor lots of workshops on drug development from medicinal plants, with the African Union (AU) on her part has established research centers at different parts of the African continent (Morah, 2007).

Over the years, researches have been carried out on *Piper guineense* popularly known as West African black pepper with little or no knowledge on its effect on parts of the digestive system. The plant is sold in local markets across West Africa and is usually used to prepare different kinds of dishes such as pepper soup etc. Traditionally, the chemical composition of *Piper guineense* is said to vary within the same geographical region, from geographical region to another, and within different seasons. Root samples collected in Volta region of Ghana in September/October were found to contain mainly wisanine and α , β -dihydroxywisanine and not piperine or α , β -dihydroxypiperine. But yet still in this same area at around January/February, root samples of this same plant were also collected and found to contain piperine and α , β -dihydroxypiperine as the main alkaloids (Addae-Mensah *et al.*, 1977; Morah, 2007). Piperine, the major alkaloid in piper species, has been shown to have antimycobacterial activity (Jin *et al.*, 2011) and pharmacological activity such as immunoregulatory activity (Pradeep and Kuttan, 2004). Piperine has also been shown to have certain serious toxicities such as antifertility (Daware *et al.*, 2000), respiratory paralysis, hemorrhagic necrosis and oedema in gastrointestinal tract, urinary bladder and adrenal glands (Piyachaturawat *et al.*, 1983) and immunotoxicological effects (Dogra *et al.*, 2004). Studies on the gastric ulcerogenic activities of *Piper guineense* ethanolic extract in male albino wistar rats caused gastric ulcerations accompanied by increase in total gastric acidity, while there was a dose-dependent increase in mortality rates in the animals (Raji *et al.*, 2003).

The duodenum is a 25cm C-shaped tube lying in front of and to the right of the inferior vena cava and abdominal aorta. It consists of four parts which include the superior, descending, horizontal and ascending parts (Sinnatambu, 2012). The duodenum begins to develop early in the fourth week from the distal part of the foregut, proximal part of the midgut and splanchnic mesenchyme associated with the endodermal parts of the primordial gut and grows rapidly to form a C-shaped loop that projects ventrally (Moore and Persaud, 2008).

This present study was carried out to study the effects of excess consumption of aqueous seed extract of *Piper guineense* on the duodenum of adult female albino rats.

MATERIALS AND METHOD

Plant Collection and Identification

The seeds of *Piper guineense* were obtained from Nkwo-Nnewi market, Nnewi North Local Government Area in Anambra state, Nigeria. The seeds were authentically identified at the Department of Botany, Nnamdi Azikiwe

University, Awka, Nigeria by a botanist.

Preparation of Plant Extracts

The seeds were then washed with clean water and sun-dried for a period of 14 days in accordance to the guide of Omafuvbe and Kolawole, 2004. The dried seeds weighing about 310g were then ground to fine powder to ensure homogeneity using a milling machine. The powder was then sieved through no. 20 mesh sized sieve and then put in distilled water for a period of seventy-two hours. This solution was then filtered through with Whatman filter paper no. 1 and the filtrate produced put in water bath at 50°C to concentrate and produce the extract which was in a thick paste-like form.

Experimental Animals and Ethical Approval

20 adult female wistar albino rats weighing between 137-147g purchased from a local farm in Nsukka, Enugu state, Nigeria were used for the experiment. They were housed in group of 5 in 4 big mesh cages in a well-ventilated animal house of the College of Health Sciences, Nnamdi Azikiwe University, Nnewi Campus. They were allowed free access to food and water daily. Before the commencement of the research, ethical approval was given by the Ethical committee of the Faculty of Basic Medical Sciences, Nnamdi Azikiwe University, Nnewi Campus.

Experimental Protocol

The animals were grouped into 4 of 5 animals each. The animals were allowed to acclimatize for a period of 2 weeks. The route of administration of extracts was orally with the aid of a rubber oral gavage tube. The animals were then administered the extract through the following protocols every evening for 28 days:

Group 1 served as the control group and fed with water and feed only.

Group 2 were administered 1000mg/kg body weight of the extract daily.

Group 3 were administered 1500mg/kg body weight of the extract daily.

Group 5 were administered 2000mg/kg body weight of the extract daily.

These animals were observed every three hours except during the nights.

Tissue Collection and Processing

The duodenum was harvested 24 hours after the last administration of extract through an incision on the abdominal wall of the animal, the organs collected were then passed through traditional histological techniques using the haematoxylin and eosin dyes as staining materials for the preparation for viewing under a compound light microscope.

Statistical Analysis

This was carried out using the one way ANOVA test by the statistical package for social sciences (SPSS) 16.0 software package with the level of significance at 0.05 ($p < 0.05$).

RESULTS

General Physical Observations

During the 1st week, the faeces of all animals were black in colour and were hard with its urine having a clear colour.

During the 2nd week, the faeces of all experimental groups now became softer with a very dark brown colour and the urine still clear.

During the 3rd week, the faeces became softer than previous weeks and the urine becomes a little yellowish-clear colour.

During the 4th week being the last week of administration, the faeces became brown in colour, softer and sticky while the urine became yellowish.

Also through the experiment, there was a decrease in food and water intake by the experimental animals.

Body Weight Analysis

Table 3: Shows the summary of the mean body weights of the animals

Mean value±S.D ($p \leq 0.05$)

	GROUP 1 (Control)	GROUP 2 (1000mg/kg)	GROUP 3 (1500mg/kg)	GROUP 4 (2000mg/kg)
INITIAL WEIGHT	139.33±2.08	146.00±1.00	145.67±3.05	148.33±0.58
P-VALUE		0.001	0.001	0.000
FINAL WEIGHT	153.67±1.53	145.33±1.16	145.67±1.16	143.67±0.58
P-VALUE		0.000	0.000	0.000

The mean weights of the animals were analysed and showed there was a significant decrease in body weights of the animals of the experimental groups at the end of the experiment when comparing their initial and final weights to those of the control group.

Histological Analysis

The histological results of the groups are as follows:

Group 1 (control): the section shows normal intestinal glands projecting into the lumen and also layers.

Group 2 (1000mg/kg): the section shows normal intestinal epithelial projections into the lumen but some of which appear to be reduced in size and amputated.

Group 3 (1500mg/kg): the section shows slight fragmentation of the intestinal epithelial linings and reduction in size of the mucosa.

Group 4 (2000mg/kg): the section shows higher fragmentations and thinning out of the intestinal epithelium.

Group 1 (control):

Fig. 1: shows H & E section ($\times 60$) of the duodenum of group 1.

Group 2 (1000mg/kg):

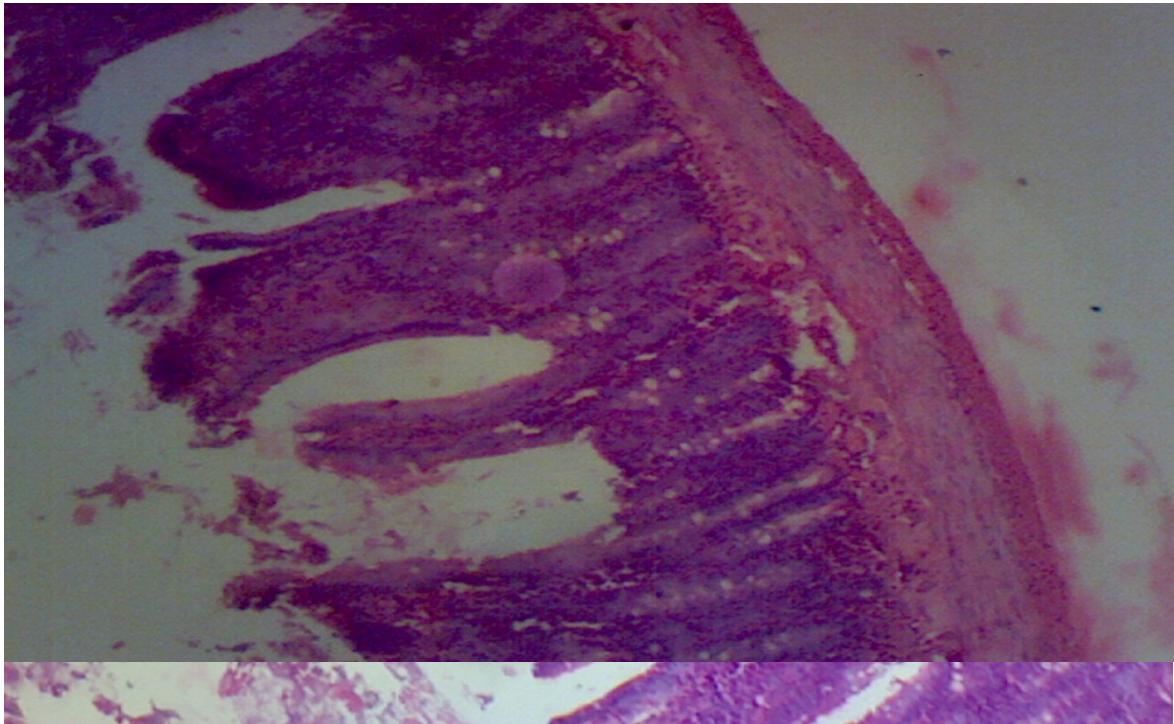


Fig. 2: shows H & E section ($\times 60$) of the duodenum of group 2.

Group 3 (1500mg/kg):

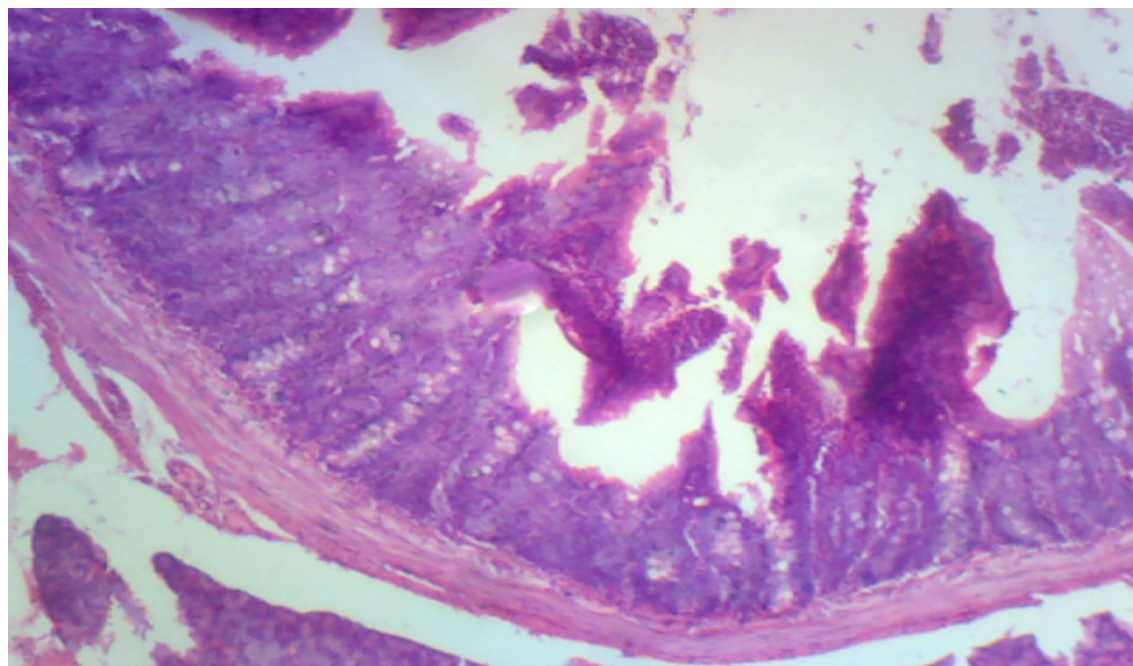


Fig. 3: shows H & E section ($\times 60$) of the duodenum of group 3.

Group 4 (2000mg/kg):

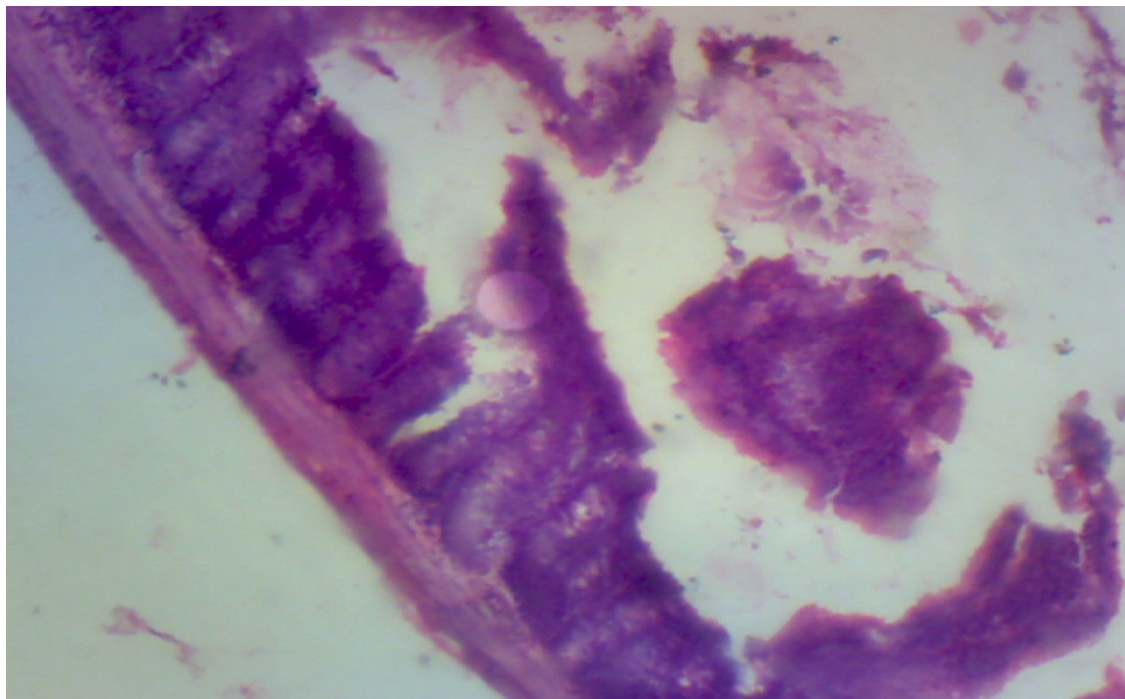


Fig. 4: shows H & E section ($\times 60$) of the duodenum of group 4.

DISCUSSION

The physical observations of urine excretion of the experimental groups showed continuous yellowish colouration of the urine could possibly be as a result of the increased deposition of electrolytes in the urine. Also, the excretion of softer, sticky and brown coloured faeces among the animals of the experimental groups shows that *Piper guineense* has the potential of aiding good bowel movements.

The study also showed that *Piper guineense* caused a very significant reduction in body weights of the animals of the experimental groups when compared to those of the control groups that gained weight.

The study further showed that the higher the dose of extract administered to the animals, the more the reduction in the epithelia lining of the duodenum as well as a higher the fragmentation of the epithelial walls within the duodenum and hence could lead to an increase in the lumen size of the duodenum.

CONCLUSION

In our world today, there are numerous plants yet to be scientifically explored as to know its medicinal and harmful effects especially when used in excess continuously and at high doses. This particular study has thereby provided a good basis to regulate the level of ingestion of *Piper guineense* seeds irrespective of the sex, age and race.

REFERENCES

1. Ampofo O. and Romand J (1978). In: Ebeye O.A, Emore E, Enaibe B.U and Igbigbi P.S. Hispathological Effect of *Piper guineense* Extract on Wistar Rats. Journal of Biological Sciences. 7; 1484-1487.
2. Pamplona-Rogers G.D (2004). In: Morah F.N.I. Medicinal Plants and Health Care Delivery. 45th Inaugural Lecture of the University of Calabar, Calabar. 2007; Pp: 21.
3. Morah F.N.I. (2007). Medicinal Plants and Health Care Delivery. 45thInaugural Lecture of the University of Calabar, Calabar.; Pp: 21.
4. Addae-Mensah J., Torto F.D, Dimonyeka C.L, Baxter I. and Sanders K.M (1977). In: Morah F.N.I. Medicinal Plants and Health Care Delivery. 45th Inaugural Lecture of the University of Calabar, Calabar. 2007; Pp: 18.
5. Jin J., Zhang J., Guo N., Feng H., Li L., Liang J., Sun K., Wu X., Wang X., Liu M., Deng X. and Yu L. (2011). The Plant Alkaloid Piperine as a Potential Inhibitor of Ethidium Bromide Efflux in *Mycobacterium smegmatis*. J. Med. Microbiol.; 60: 223-229.
6. Pradeep C.R and Kuttan G. (2004). Piperine is a Potent Inhibitor of Nuclear Factor-kappa B (NF-kappa

- B), c-Fos, CREB, ATF-2 and Proinflammatory Cytokine Gene Expression in B16F-10 Melanoma Cells. *Int. Immunopharmacol.*; 4: 1795-1803.
7. Daware M.B, Mujumdar A.M and Ghaskadbi S. (2000). Reproductive Toxicity of Piperine in Swiss Albino Mice. *Planta Med.* 66: 231-236.
 8. Piyachaturawat P, Glinsukon T and Toskulkao C. (1983). Acute and Subacute Toxicity of Piperine in Mice, Rats and Hamsters. *Toxicology Letters.*; 16: 351-359.
 9. Dogra R.K.S, Khanna S. and Shanker R. (2004). Immunotoxicological Effects of Piperine in Mice. *Toxicology*, 196: 229-236.
 10. Raji Y, Udoh U.S, and Ojo O.O. (2003). Gastric Ulcerogenic Activities of *Piper guineense* Extract in Rats. *Nigerian Journal of Physiological Sciences.*; 18 (1-2): 27-30.
 11. Sinnatamby C.S. (2011). *Last's Anatomy: Regional and Applied*. 12th Edition. Elsevier Ltd, China.; Pp: 253.
 12. Moore K.L and Persaud T.V.N. (2008). *The Developing Human; Clinically Oriented Embryology*. 8th Edition. Saunders Elsevier, China.; Pp: 216.
 13. Omafuvbe B.O and Kolawole D.O. (2004). Quality Assurance of Stored Pepper (*Piper guineense*) Using Controlled Processing Methods. *Pakistan Journal of Nutrition.*; 3 (4): 244-249.