

The Protective Role of Iraqi Propolis in Preventing Anemia Caused by AFB-1 in Male Rats

Ahmed Ayed Shehab* Majida Jaafer Alqayim
College of Vet. Medicine, Baghdad university, Aljaderyai street . Iraq

Abstract

Aflatoxins have been linked to cause anemia in many research, these effects can be countered by natural materials like Propolis. Our study designed to investigate the protective role of propolis against AFB-1 on erythrocytes indices and iron status and to find out the status of the anemia in rats exposed to AFB-1 for 60 days. 24 male rats divided into equal 4 groups: group C was control, second group AF received Aflatoxin-B1 (0.025mg/kg), third group P received Propolis in dose (50 mg /kg BW) and the fourth group AFP received Aflatoxin-B1 (0.025 mg/ 1kg BW) + Propolis (50 mg / 1kg BW). Results revealed that AFB1 orally induced anemia indicated by significant decrease of PCV, HB, RBCs count, MCV and MCH with increase of RDW in AF group and non-decreased in P and AFP groups when compared with control group. Iron status showed a significant increase in iron TIBC, UIBC and PTS in all of the groups while the ferritine decreased in all of them except the control. In conclusion , orally exposure to Aflatoxin-B1 for 60 days induced anemia characterized by iron overload and microcytic, hypochromic and anisocytosis erythrone. Propolis showed a high activity to improve all the above measurements and counter these deleterious effect of Aflatoxin-B1 to normal situation, and was successful in treatment of anemia.

Keywords: Aflatoxin, Propolis, Anemia, Erythrocytes indices, Iron status.

1. Introduction

Aflatoxins are a group of naturally occurring poisonous by-products from soil-borne fungus *Aspergillus*, that are known to contaminate different human and animal food stuffs, further more recently evidenced that AFB-1 can be excreted in the milk of dairy cattle exposed to contaminated food (Gizachew *et al.*, 2016). Consumption of food contaminated with Aflatoxin-B1, caused deleterious effects on different body's systems , make it a risk to human and animal health, and it is responsible for economic losses (Hasheminejad *et al.*, 2015; Amanda *et al.*, 2016). Previous studies have shown that espousing to AFB1 cause different side effects on liver , since liver is responsible for the metabolism of AFB1 to the reactive 8,9-epoxide , the binding of epoxide to hepatocytes DNA is the main causes for liver cells injury (McLean and Dutton, 1995, Samir, etal.2016). Trebak *et al.*, 2015 referred to the AF poisoning results in symptoms of depression, anorexia, diarrhea, jaundice or anemia that can lead to death. In addition aflatoxin affect the hematopoietic system and also results anemia (Salah 2013). Aflatoxins have been linked to anemia in many cases , usually anemia in aflatoxin exposed animals is known as hemolytic anemia by decreasing the circulating mature erythrocytes (Verma, and Raval, 1992) .Others , link anemia in animals to the direct effects of AFB-1 causing hematopoietic suppression , represented by decrease in total erythrocytes, packed-cell volume and hemoglobin which (Reddy, and Waliyar, 2012) as well as interaction of AFB-1 with RNA and DNA of hemopoietic cells (Verma, 2004).

Propolis, is a natural resin it's looks like wax material produced by honey bees as a mixture of various plants exudates. Chemical analysis of propolis revealed that it may contain verities of compounds like resin, essential oils and waxes, and also contains amino acids, minerals, ethanol, vitamin A, B complex, E, and flavonoids (Abubakar *et al.*, 2014). Propolis have general pharmacological value as a natural mixture of many chemical compounds as poly phenols: flavonoids, phenolic acids, phenolic aldehyde and alcohol, coumarins and steroids (Banskota *et al.*, 2000, Martose *et al.*,2000, Cardile *et al.*, 2003). For these constituents Propolis has the potential roles to improve the hematological measurments against many pathogenic microorganisms and counteract the effects of toxic material (Magda and Samaa, 2013, Al-qayim *et al.*, 2014). In addition it used safely for its anti oxidant (Niraldo *et al.*, 2014), anti-inflammatory and cardio-protective (Khalil and Sulaiman, 2010, Alqayim, 2014) hepato-protective (Nakamura *et al.*, 2012; Niraldo *et al.*, 2014; Al-Amoudi, 2015), and neuro-protective (Barrose *et al.*, 2013).

Propolis showed an effective roles against many pathogenic microorganisms and counteract the effects of toxic material and has the potential to improve the hematological parameters in Anemic animals (Alqayim *et al.*, 2014). Accordingly , the present study designed to evaluate the protective role of Iraqi propolis on erythrocytes indices and iron status in anemia caused by sub chronic exposure to AFB1.

2. Material and Methods

2.1 Experimental Design :

Twenty four adult male rats were divided into 4 equal groups: 1st (C) control group; 2nd (P) were given daily by oral gavage (50 mg /kg body weight) of propolis, (Mokhtar and Afrah, 2009) ; 3rd (Af) this group were given Aflatoxin (0.025mg/kg body weight); 4th (AFP) this group will be given by oral gavage (50 mg /kg body weight) of propolis + Aflatoxin (0.025mg/kg body weight). They all were kept under suitable condition of (21-25 C) in an air-condition room and fed freely with standard pellet diet (table-1). All applications were administered daily for 60 consecutive days. At The end of the experiment blood sample (4-5 ml) was collected from the rat obtained via cardiac puncture technique from each anesthetized animal for serum isolation for hematological and biochemical analysis.

Table 1: the components of the pellets:

Feed materials	%
Yellow corn	35
Wheat	35
Soybean	19
Animal protein	10
Vitamins and minerals	1

2.2 Erythrocytes indices:

Total red blood cells (RBC) count, hemoglobin (Hb) concentration, mean corpuscular volume (MCV), mean corpuscular hemoglobin (MCH), and Red cell distribution width (RDW) were accomplished by using hematological analyzer (Hycel Hematology analyzer, version B, ver2.5x.) at private general laboratory for processing in both hematology and biochemistry/ Baghdad city

2.3 Iron status

Serum iron: Serum iron concentration was enzymatically measured using enzymatic assay kit (Biolabo SA, Maizy-France).

Serum Ferritine: was measured by Ferritine enzyme immunoassay test Kit (Linear chemicals, Barcelona-Spain) using DANA 3200 ELISA Reade

Serum Total Iron Binding Capacity TIBC(µg/dl) measured by colorimetric method at 600 nm using a commercial kit.

2.4 Statistical analysis

The Statistical Analysis System- SAS (2012) was used to effect of different actors in study parameters. The Least significant difference-LSD test the comparative between means in this study.

3. Results

3.1 Protective Role of Propolis on erythrocytes indices in male rats with Aflatoxin induced anemia

Results obtained from the this experiment in related to the protective role of propolis against the anemia induced by Afl-B1 intubated rats for 60 days were shown in table-3. The Hb (g/dL) level sharply decreased ($P < 0.05$), in the AF group (7.88 ± 0.47) when compared with control group (13.00 ± 0.34), on the other hand propolis was efficient in correct the Hb value in to a near the normal values in AFP group (13.00 ± 0.29).

3.2 Protective Role of Propolis on Iron status against Aflatoxin-B1 induced anemia

Results obtained from the analysis of iron status represented in table 4. shown that there was significant ($P < 0.05$) increase of total iron (µg/dl) in AF and AFP groups (190.33 ± 2.57 , 156.67 ± 5.89), when compare with C and P groups (86.33 ± 2.33 , 110.67 ± 3.77) respectively. Furthermore, results presented in figures-1 & 2 revealed a negative correlation between total serum iron and hemoglobin and RBCs count in the present experiment.

Transferrin iron binding capacity (µg/dl) and Unsaturated iron binding capacity (µg/dl) were increased significantly (490.17 ± 9.66 , 520.83 ± 11.04) in AF and P group but the most sharp increase was in AFP group (650.67 ± 8.66), when compared to the control group (376.83 ± 7.25). Mean while the Ferritine was decreased significantly in all experimental groups (0.800 ± 0.07 , 0.750 ± 0.07 , 0.833 ± 0.08) when compare with control (1.48 ± 0.03).

Figures 3-6, revealed the histopathological changes of liver sections of experimental animals. Examination of light microscopic photograph of liver sections obtained from control group revealed normal radial arrangement of hepatic cord and sinusoids with normal appearance of kupffer cells, on the contrast liver of

AF group showed sinusoids dilation and hepatic cord atrophy, also there were prevascular mononuclear cells infiltration. In addition the kupffer cells were few in numbers and are enlarged and became in spherical shape and distributed within tissue (figure-4) other sections showed dilation of blood vessels and necrotic hepatocytes. Liver histopathological changes of P group showed normal hepatic cord with normal sinusoides arrangement with focal aggregation of mononuclear cells were high in number of macrophages (figure-5). Photograph in figure-6, revealed liver tissue changes of AFP group, there were hepatic cord atrophy caused by sinusoides dilation and blood vessels and cell swallowing. In general analysis of liver sections revealed no appearance of any signs for hemosidrine deposition in kupffer and hepatocytes in liver section of the present experimental animals..

Discussion

Erythrocytes indices:

The significant decrease in total RBCs indices denoted in the present study in AFB1 group could be attributed to the deleterious effects of Aflatoxin on bone marrow, also varies types of mycotoxins may resulting in varies ineffective erythropoiesis due to inhibition effects on proliferation of blood elements (Ficheux *et al.*, 2012), or due to decreased marrow pluripotent stem cells (Boorman, 1984). Recently Mageda and Ahmed, 2015 suppose the erythropoiesis, hemosynthesis and osmoregulatory dysfunction that occur owing to inhibiting the activities of several enzymes involved in heme biosynthesis (ATSDR, 2005) caused decrease in RBC, PCV, and HB. In addition, many research indicated the mycotoxins enhanced lipid peroxidation and MDA formation in liver tissue which is presumably results of free-radical-mediated toxicity (Abdel-Wahhab *et al.*, 2012). MDA reactivity towards amino groups can result in inhibition of DNA and RNA protein synthesis in liver (Hassan, *et al.* 2012), and therefore affect enzymes synthesis mainly those involved in hemosynthesis. Furthermore we suggest here the increase in preliminary RBCs destruction due to the oxidative stress induced directly by the effects of AFB1 on RBCs antioxidants system caused an increase in the rate of erythrocyte destruction in hematopoietic organs (Jenkins and Smith, 2003).

The current data demonstrated that propolis administration is considered as a potent antioxidant agent (Hegazi, 2002) since it could produce marked increase in catalase activity and prevent the preliminary destruction of RBCs (Alqayim *et al.*, 2014) and increase in antioxidant /oxidant, and change in some of the red blood cell parameters were detected (Jasprica *et al.*, 2007).

Red blood cell distribution width (RDW) is a measure of variation of circulating red blood cell volume. Measurement of RDW can be taken by for diagnosis of anemia. High RDW associated with anemia of chronic disease, anemia that resulting from an inefficient of the bone marrow to produce red blood cell and some hereditary diseases related to hemoglobin pathies (sheri perkins). It is mainly used to differentiate an anemia of mixed causes from an anemia of a single cause. Any deviation in the RDW from control value indicate abnormal erythrocytes size is known as anisocytosis. While erythrocytes have their own antioxidant system, they affected by oxidative stress induced during inflammation contribute to anisocytosis (Lippi, *et al.* 2009). In addition RDW showed higher levels in disease related to hypertensive and cardiac failure (savas *et al.*, 2014).

4.2 Protective Role of Propolis on Iron status against Aflatoxin-B1 induced anemia

In normal conditions, the blood iron levels reflect the balance between the release of iron from its storage and what is its use. Iron sources either from intestinal absorption or the storage of which is mainly from the reticuloendothelial system macrophages and other cells like hepatocytes and shaded enterocytes (Anderson *et al.*, 2007). This critical balance of plasma iron should meet the needs of body cells for iron mainly the iron utilization by bone marrow, were hemoglobin synthesis. The release of iron from those sourcing is strictly regulated by liver derived peptide hepcidine (Anderson *et al.*, 2007), When diatec iron increase this protein block the efflux of iron from its storage cells, disturbances in the hepcidin regulatory pathway underlie iron loading (Anderson *et al.*, 2009). In the present study the significant elevation in total serum iron suggests the deleterious effects of Aflatoxin-B1 on this mechanism, which could be attributed to defects in hepcidine synthesis and release because of the hepatotoxic and hepatocarcinogenic induced by the aflatoxin (Navarro and Senior, 2006, Wogan, 1999, Plaa and Hewitt, 1986).

Furthermore, in the present study iron elevation could be explained as a result of the role of macrophages in iron regulation is crashed due to either reduction of macrophages or due to its ineffectiveness. Macrophages play a central role for mammalian iron homeostasis, via the phagocytosis of senescent erythrocytes and their degradation enable efficient recycling of iron and the maintenance of systemic iron balance (Manfred *et al.*, 2015). Macrophages number and function as an immune system affected by Afltoxin-B1 (Moon *et al.*, 1999; Dugyala *et al.*, 1996). In the present study It became clear the effect of AFB-1 on phagocytic cells (macrophages) in the liver tissue where the number dropped significantly as documented by liver section photograph obtained from experimental animals. More ever the AFB1 decreased the macrophages role in immune response by

reducing the ability for producing variety of cell markers involved in inflammatory response (Bruneau *et al.*, 2012), ultra structural examination of the immune organ cells revealed a high apoptosis (Xi Peng *et al.*, 2015).

Bone marrow hematopoietic tissue suppression and reduction in hemoglobin synthesis and defect in the iron utilization might be one of the causes for increase of serum iron. Present results clearly indicated that the lack of hemoglobin did not happen because of iron deficiency and on the contrary, there was an increase in iron regress with hemoglobin deficiency.

Aflatoxin B₁ (AFB₁)-induced chromosome aberrations (CA) in rat bone marrow cells consisted mainly of gaps and breaks, caused inhibition of several enzymes involved in heme biosynthesis result in dysfunction of erythropoiesis, hemosynthesis, and osmoregulation, similar results were previously mentioned by Boorman (1984) as the deleterious effects of mycotoxines on bone marrow such as decreased marrow pluripotent stem cells and decreased Fe⁵⁹ uptake in marrow and spleen of exposed rats. The present results related to erythrocytes indices suggested abnormal hematopoiesis activity caused by AFB-1 exposing for 60 days resulted in iron over load. In the same pattern, we suggest that increasing destruction of red blood cells caused by oxidative stress induced by AFB-1 (Verma and Raval 1991) led to increased serum iron.

In the present study, although, TIBC indicate the maximum of iron that can be bound to transferrin was increased, but with this there was increase in the UIBC, due to the excessive increase in iron, and this is shown by the result of the transferrin saturation percentage where significantly increased. Reflect the response of the body to face the significant increase in blood iron caused by oral exposing to AFB₁. Iron is delivered to tissues by circulating transferrin, a transporter that captures iron released into the plasma mainly from intestinal enterocytes or reticuloendothelial macrophages. Normally the transferrin-iron complex is endocytosing by macrophages and hepatocytes via TFRs located on their cell membranes, AFB₁ caused disabled these receptors for endocytosing the transferrin-iron complex consequently they persist in the blood., this clearly supported by the lack of any signs of hemosidrine deposit in liver tissue as revealed liver histopathological photograph. Iron homeostasis and macrophage biology are closely interconnected, on the one hand, iron exerts multiple effects on macrophage polarization and functionality. On the other hand, macrophages are central for mammalian iron homeostasis. The phagocytosis of senescent erythrocytes and their degradation by macrophages enable efficient recycling of iron and the maintenance of systemic iron balance.

Macrophages express multiple molecules and proteins for the acquisition and utilization of iron and many of these pathways are affected by inflammatory signals. Of note, iron availability within macrophages has significant effects on immune effector functions and metabolic pathways within these cells (Manfreid *et al.*, 2015). Ferritin, is one of the IRPs system in the body mediate the intracellular of iron storage, this iron-storage protein has also been implicated in iron-transport pathways, which may predominate in pathological states, where iron-rich intracellular ferritin is released from damaged tissues (Moreira *et al.*, 2011). In physiological conditions When iron is in excess, the ferritin synthesis and iron storage increase. At the same time, transferrin receptor synthesis and iron uptake decrease Our explanation for the unexpected decrease in ferritin is due to a specific side effects of AFB₁ on hepatocytes resulting in to denaturation of the storage protein, and /or from a direct effects of iron overload on this protein (Zacharski, 2000) consequently releasing large amounts of iron into the cytoplasm of the hepatocytes. The inverse relationship between total iron and total RBCs count in add to reduced Hemoglobin suggest that the significant elevation of iron is dependent on increased destruction of RBCs caused by AFB-I, and hemoglobin synthesis suppression. These results are confirmed more by the histological changes of liver tissue were indicated no signs of hemosidrine deposition within hepatocytes and macrophages, furthermore the hepatocytes damage, all of the above mention to the impairment of iron utilization by hepatocytes in AFB-1 exposed animals.

In the present study administration of propolis was efficient of balancing the iron level in AFP group. Propolis and other natural product improve the digestive absorption of iron and other minerals, elevating total circulating iron in iron deficiency animals (Ana *et al.*, 2000). In the present study the significant elevation of TIBC and UIBC with a semi normal total iron in rats received propolis indicated the good response of animals received propolis to the increased iron absorption. On the other hand propolis succeeded in reducing ferritin thus reducing the excess iron storage in the tissue in order to prevent the case iron over load. In addition to this, propolis was improved in prevention of the preliminary RBCs elimination (Alqayim *et al.*, 2014).

5. Conclusion

Despite the significant increased of total iron, TIBC, and UIBC there were significant decrease in the storage iron protein, ferritin, which may refer to iron overload caused by aflatoxin-B₁. This unexpected iron over load could be resulted from higher preliminary RBCs destruction and decreased hemoglobin synthesis due to hematopoietic system damage

The mechanisms responsible for increase circulating iron were Cumulative effects due to the impact of AFB₁ and the improvement of propolis, as mentioned previously. However, propolis was efficient in Maintain normal ratio of transferrin saturation and ferritin, reflecting a protective role in iron status.

References

- Abdel-Wahhab M.A., Ibrahim A.A., El-Nekeety A.A., Hassan N.S., Mohamed A.A. 2012. Panax ginseng C.A. Meyer extract counteracts the oxidative stress in rats fed multi- mycotoxins-contaminated diet. *Com Sci.*,3(3):143-153.
- Abubakar, M.B.; Abdullah, W.Z.; Sulaiman, S.A. and Boon Suen Ang (2014). Polyphenols As Key Players For The Antileukaemic Effects Of Propolis. *Evidence-Based Complementary And Alternative Medicine*, 2014 (2014):11.
- Al-Amoudi, W. (2015). Ameliorative Role And Antioxidant Effect Of Propolis Against Hepatotoxicity Of Fenvalerate In Albino Rats. *J Cytol Histol.* 6:303.
- Al-Qayim A.J.M; Laith Sadiq Ghali1 and Tahani S. Al-Azwai. (2014). Comparative Effects Of Propolis And Malic Acid On Hematological Parameters Of Aluminum Exposed Male Rats. *G.J.B.B.*,3 (1):6-11
- Amanda, A.; Manyes, L.; Meca, G.; Ferrer, E.; Luciano, F.B.; Pimpão, C.T. and Font, G. (2016). Mycotoxins and their consequences in aquaculture: A review. *Aquaculture*, 451:1–10.
- Ana, F.L., Fermín, M, Sofia, A.; Yolanda, G.; Anunciación, A.; Javier De Las R. and Javier A. (2000). Responses of Sugar Beet Roots to Iron Deficiency. Changes in Carbon Assimilation and Oxygen Use. *Plant Physiology*, 124(2):885-898.
- Anderson GJ, Darshan D, Wilkins SJ, Frazer DM. *Biomaterials*. (2007). Regulation of systemic iron homeostasis: how the body responds to changes in iron demand. *BioMetals*, 20:665-674.
- Andersonx, GJ.; Frazer, DM. and McLaren, GD. (2009). Iron absorption and metabolism. *Curr Opin Gastroenterol*, 25(2):129-135.
- ATSDR. (2005). Draft Toxicological Profile for Lead. US Department of health and human services, Atlanta, Georgia, USA :102–225
- Banskota, A. H.; Tezuka, Y.; Adnyana, K.; Midorikawa, K.; Matsushige, K.(2000). Cytotoxic, Hepatoprotective And Free Radical Scavenging Effects Of Propolis From Brazil, Peru, The Netherlands And China. *Journal Of Ethnopharmacology*, 72,(1-2):239-246.
- Barros, Silva R.; Santos, N. A.; Martins, N.M.; Ferreira D.A.; Barbosa F. (2013). Caffeic Acid Phenethyl Ester Protects Against The Dopaminergic Neuronal Loss Induced By 6-Hydroxydopamine In Rats. *Neuroscience* 233:86–94
- Boorman, GA.; Hong, HL; Dieter, M.P.; Hayes, H.T.; Pohland, A.E.; Stack, M. and Luster, M.I. (1984). Myelotoxicity and macrophage alteration in mice exposed to ochratoxin A. *Toxicol Appl Pharmacol*, 72(2):304-12.
- Bruneau, J.C.; Stack, E.; O'Kennedy, R.and; Loscher, C.E. (2012). Aflatoxins B(1), B(2) and G(1) modulate cytokine secretion and cell surface marker expression in J774A.1 murine macrophages. *Toxicol. In Vitro.* 26:686–693.
- Cardile, V.; Panico, A.; Gentile, B.; Borrelli, F.; Russo A. (2003). A. Effect Of Propolis On Human Cartilage And Chondrocytes. *Life Sciences*, 73(8):1027-1035.
- De Guadalupe, M.M.; Carvajalmoreno, M.; Javier, J.; Espinosa-Aguirre; Gonsebatt-Bonaparte, M.E.; Rojo-Callejas, F.; Castillo-Urueta, P.; Pérez-López, I. and Ruiz-Vel, S. (2015). Role of ph in the Mutagenicity of Aflatoxin B1 in Maize Tortillas during In Vitro Human Digestion Model. *Journal of Food & Nutritional Disorders*, 4:3.
- Dugyala, R. R. and Sharma, R. P. (1996). The effect of aflatoxin on cytokine mRNA and corresponding protein levels in peritoneal macrophages and splenic lymphocytes. *Int. J. Immunopharmacol.*, 18:599.
- Ficheux, A.S.; Sibiril, Y.; Le Garrec, R. and Parent-Massin, D. (2012). *In vitro* myelotoxicity assessment of the emerging mycotoxins Beauvericin, Enniatin b and Moniliformin on human hematopoietic progenitors. *Toxicol.*, 59(1):182–191
- Gizachew, D.; Szonyi, B.; Tegegne, A.; Hanson, J. and Grace, D. (2016). Aflatoxin contamination of milk and dairy feeds in the Greater Addis Ababa milk shed, Ethiopia. *Food Control*, 59:773–779
- Hasheminejad, S.A.; Makki, O.F.; Nik, H.A.and Ebrahimzadeh, A. (2015). The effects of aflatoxin B1 and silymarin-containing milk thistle seed s on ileal morphology and digestibility in broiler chickens. *Veterinary Science Development*, 5 (2).
- Hassan A.M., Abdel-Aziem S.H., Abdel-Wahhab M.A. (2012). Modulation of DNA damage and alteration of gene expression during aflatoxicosis via dietary supplementation of Spirulina (*Arthrospira*) and whey protein concentrate. *Ecotoxicol. Environ. Safety*,79:294-300.
- Hegazi, A.G.; El Hady, F.K.A. (2002). Egyptian propolis: 3. Antioxidant, antimicrobial activities and chemical composition of propolis from reclaimed lands. *Z. Naturforsch. C* , 57, 395–402.
- Jasprica, I.; Mornar, A.; Debeljak, Z.; Bubalo, A.S; Medić-Šarić, M.; Mayer, L. (2007). *In vivo* study of propolis supplementation effects on antioxidative status and red blood cells. *Journal of Ethnopharmacology*, 110(3):548–554.
- Jenkins, F. and Smith, J. (2003). Effect of sublethal concentrations of endosulfan on hematological and serum

- biochemical parameters in the carp, *Cyprinus carpio* Bull. Environ. Contam. Toxicol., 70:947–993.
- Khalil, M.I. and Sulaiman, S.A. (2010). The Potential Role of Honey and its Polyphenols in Preventing Heart Diseases. Afr J Tradit Complement Altern Med., 7(4):315–321.
- Magda, E.M. And Samaa, S. E. (2013). Protective Effect Of Ascorbic Acid, Biopropolis And Royal Journal Of Natural Sciences Research, 3,(1):102- 112
- Manfred N., Andrea, S., Egon, D., Ivan T., Igor T., and Günter W. (2015). Ride on the ferrous wheel – The cycle of iron in macrophages in health and disease. Immunobiology , 220, (2): 280–294.
- Martos, I.; Ferreres, F.; Tomas-Barberan, F. A.(2000). Identification Of Flavonoid Markers For Thebotanical Origin Of Eucalyptus Honey. Journal Of Agricultural & Food Chemistry, 48,(5):1498-1502.
- McLean,M. and Dutton,M.F. (1995). Cellular interactions and metabolism of aflatoxin: an update. Pharmacol. Ther., 65, 163–192.
- Mokhtar I. Yousef and Afrah F. Salama. (2009). Propolis protection from reproductive toxicity caused by aluminium chloride in male rats. Food and Chemical Toxicology, 47(6):1168-1175.
- Moon, E.Y.; Rhee, D.D. and Pyo, S. (1999). In vitro suppressive effect of aflatoxin on murine oeritoneal macrophage functions. Toxicology, 133: 171-179.
- Moreira, L.L.; Dias, T.; Dias, L.G.; Rogão, M.; Da Silva, J.P. and Estevinho, L. M.(2011). Propolis influence on erythrocyte membrane disorder (hereditary spherocytosis): A first approach. Food and Chemical Toxicology, 49(2):520–526.
- Nakamura, T.; Ohta, Y.; Ohashi, K.; Ikeno, K. and Watanabe, R. (2012). Protective Effect Of Brazilian Propolis Against Hepatic Oxidative Damage In Rats With Water-Immersion Restraint Stress. Phytother. Res. 26:1482–1489.
- Navarro V.J. and Senior, J.R. (2006). Drug-related hepatotoxicity. N. Engl. J. Med., 35(4):731–739.
- Lippi, G.; Filippozzi, L.; Montagnana, M.; Salvagno, G.L.; Franchini, M. Guidi, G.C. and Targher, G. (2009). Clinical usefulness of measuring red blood cell distribution width on admission in patients with acute coronary syndromes. Clin Chem Lab Med., 47:353–357.
- Niraldo, P.; Aguinaldo, P. Barbosa; Amarilis, S. Paulino and Maria C. Marcucci. (2014). Hepatoprotective effect of green propolis is related with antioxidant action in vivo and in vitro. ScopMed., 2(4):57-102.
- Plaa, G.L. and Hewitt, W.R. (1986). Detection and evolution of chemically induced liver injury. In: Hayes, A.W. (Ed.), Principles and Methods of Toxicology. Raven press, New York :401-441.
- Reddy, S. V. and Waliyar, F. (2012). Properties of aflatoxin and it producing fungi. International Crops Research Institute for the Semi-Arid Tropics.
- Salah Mahmood Ashour. (2013). The use of Stem Cells to evoke the immune system in aflatoxin immunosuppressant Ewes. PHD thesis, department of physiology, collage of veterinary medicine, University of Baghdad.
- Samir, A.; Jalila, B.S.; Jebali, R.; Ben Younes, R. and Oueslati, R. (2016). Interaction of aflatoxin B₁ and fumonisin B₁ in mice causes immunotoxicity and oxidative stress: Possible protective role using lactic acid bacteria. Journal of Immunotoxicology, 13(1):46-54.
- Savas, S.; Şafak, Ş.; Lutfi, A.; Elif, B.; Yunus, K.Y.; Fatih, A. and Kayıhan, K. (2014). Is there any relationship between RDW levels and atrial fibrillation in hypertensive patient? Afr. Health Sci., 14(1): 267–272. Sci., 73(9):R117-24.
- Trebak, F.; Alaoui, A.; Alexandre, D.; El Ouezzani, S.; Anouar, Y.; Chartrel, N. and Magoul, R. (2015). Impact of aflatoxin B₁ on hypothalamic neuropeptides regulating feeding behavior. Neurotoxicology, 49:165-173.
- Verma, R.J. and Raval, P.J. (1991). Cytotoxicity of aflatoxin on red blood corpuscles.
- Verma, R.J. and Raval, P.J. (1992). Alteration in erythrocytes during induced chronic aflatoxicosis in rabbits. Bulletin of environmental contamination and toxicology, 49(6): 861-865.
- Verma, R. J. (2004). Aflatoxin Cause DNA Damage. Int J Hum Genet, Vol.4 (4) : 231-236.
- Viuda-Martos, M.; Ruiz-Navajas, Y.; Fernandez-Lopez, J. And Perez-Alvarez,
- Wogan, G.N., (1999). Aflatoxin as a human carcinogen. Hepatology,30: 573-575.
- Xi Peng; Bai, S.; Ding, X.; Zeng, Q.; Zhang, K. and Fang, J. (2015). Pathological changes in the immune organs of broiler chickens fed on corn naturally contaminated with aflatoxins B₁ and B₂. Avian Pathology, 44(3):192-199.
- Zacharski, Leo R.; Ornstein, D.L.; Woloshin, S. and Schwartz, L.M. (2000). Association of age, sex, and race with body iron stores in adults. American Heart Journal, 140(1):98–104.

Table 2: Protective Role of Propolis on , RBC count ($10^6/\text{mm}^3$), MCV (fL), MCH (pg) and RDW (%) in male rats with aflatoxin induced anemia for 60 days (Mean \pm SE. no=6.)

Treatments	HB (g/dL)	RBC count ($10^6/\text{mm}^3$)	MCV (fL)	MCH (pg)	RDW (%)
Control	13.00 \pm 0.34 ^a	7.10 \pm 0.31 ^{ab}	54.45 \pm 1.30 ^a	18.85 \pm 0.84 ^{ab}	13.05 \pm 0.23 ^b
AF	7.88 \pm 0.47 ^b	5.08 \pm 0.39 ^c	52.96 \pm 2.86 ^a	18.86 \pm 0.44 ^{ab}	18.68 \pm 0.75 ^a
P	13.06 \pm 0.39 ^a	7.85 \pm 0.41 ^a	49.31 \pm 2.40 ^a	16.62 \pm 1.31 ^b	13.36 \pm 0.17 ^b
AFP	13.00 \pm 0.29 ^a	6.72 \pm 0.25 ^b	51.58 \pm 1.96 ^a	19.18 \pm 0.63 ^a	13.85 \pm 0.23 ^b
LSD value	1.130 **	1.029 **	6.518 NS	2.559 *	1.236 **

* (P<0.05), ** (P<0.01), NS: Non-significant.

C = received distilled water AF= received Aflatoxin-B1 (0.025mg/kg) P= received Propolis in dose (50 mg /kg BW) AFP= Received Aflatoxin-B1 (0.025 mg/ 1kg BW) + Propolis (50 mg / 1kg BW). Small letter = indicate significant (P<0.05) differences within the group (row)

Table 3: Protective Role of Propolis on Total iron($\mu\text{g}/\text{dl}$), iron binding capacity($\mu\text{g}/\text{dl}$), unsaturated iron binding capacity(UIBC) ($\mu\text{g}/\text{dl}$), Transferrin saturation(TS) (%), and ferritine ($\mu\text{g}/\text{L}$) in male rats with Aflatoxin induced anemia for 60 days (Mean \pm SE. no=6.)

Treatments	Iron ($\mu\text{g}/\text{dl}$)	T.I.B.C ($\mu\text{g}/\text{dl}$)	UIBC ($\mu\text{g}/\text{dl}$)	PTS (%)	Ferritine ($\mu\text{g}/\text{L}$)
Control	86.33 \pm 2.33 ^j	376.83 \pm 7.25 ^k	290.50 \pm 5.21 ^g	22.85 \pm 0.29 ^g	1.48 \pm 0.03 ^a
AF	190.33 \pm 2.57 ^a	490.17 \pm 9.66 ^f	299.83 \pm 7.30 ^g	38.80 \pm 0.31 ^a	0.800 \pm 0.07 ^d
P	110.67 \pm 3.77 ^g	520.83 \pm 11.04 ^c	410.17 \pm 14.28 ^c	21.32 \pm 1.15 ^h	0.750 \pm 0.07 ^d
AFP	156.67 \pm 5.89 ^c	650.67 \pm 8.66 ^a	494.00 \pm 14.02 ^a	24.08 \pm 1.19 ^f	0.833 \pm 0.08 ^d
LSD value	11.53 **	27.33 **	32.36 **	2.521 **	0.204 **

C = received distilled water AF= received Aflatoxin-B1 (0.025mg/kg) P= received Propolis in dose (50 mg /kg BW) AFP= Received Aflatoxin-B1 (0.025 mg/ 1kg BW) + Propolis (50 mg / 1kg BW). Small letter = indicate significant (P<0.05) differences within the group (row)

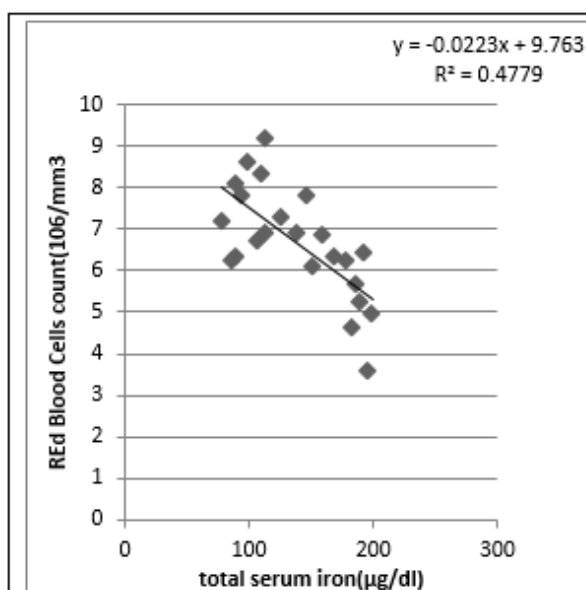


Figure-1: Relationship between serum iron and red blood cells count in rats fed AFB-1 for 60 days . The R^2 value show significant regression of variable of y on variation of x values

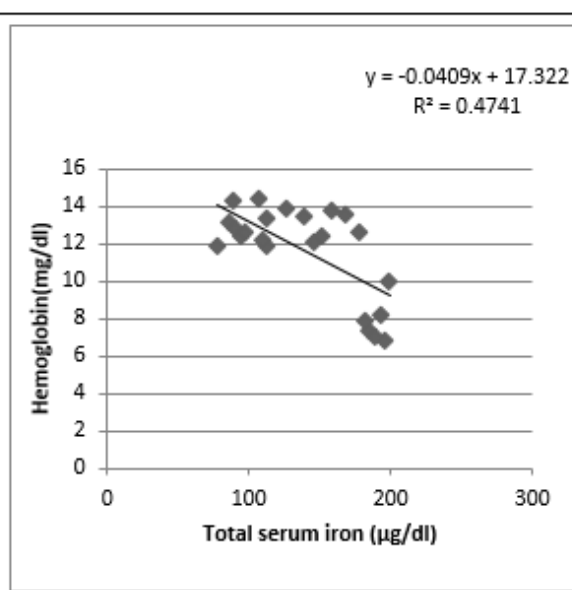


Figure-2: Relationship between serum iron and red Hemoglobin in rats fed AFB-1 for 60 days . The R^2 value show significant regression of variable of y on variation of x values

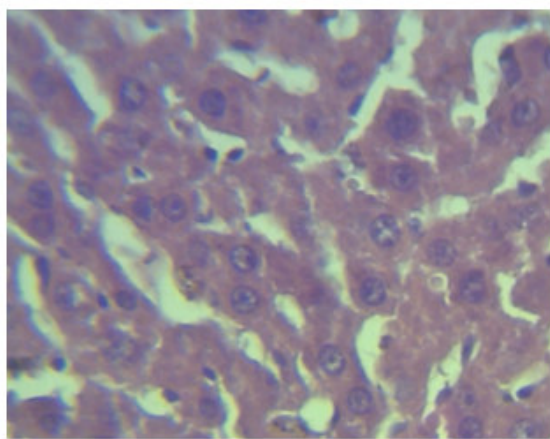


Figure-3:Light microscope photograph of liver section in control group showing normal appearance of hepatic cord , arranged sinusoides,with kupffer cells.H&E. (X40)

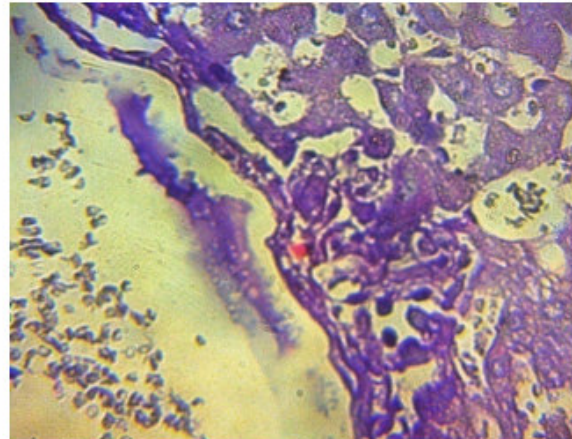


Figure-4:Light microscope photograph of liver section in AF group. Showing sever destruction of hepatic cord with slight mononeuclear cells infiltration. H&E. (X40)

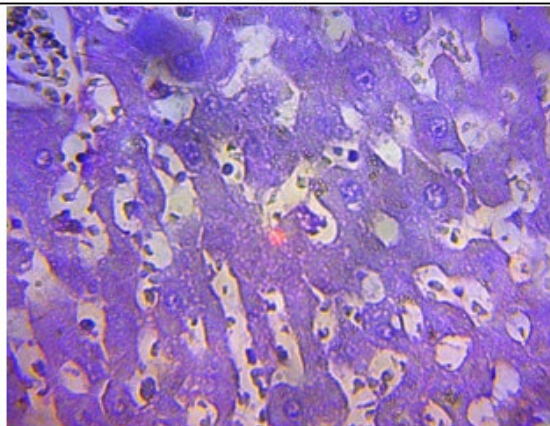


Figure-5:Light microscope photograph of liver section in P group, showing no clear pathological lesions except slight mononuclear cells infiltration in some dilated sinusoids .H&E. (X40)

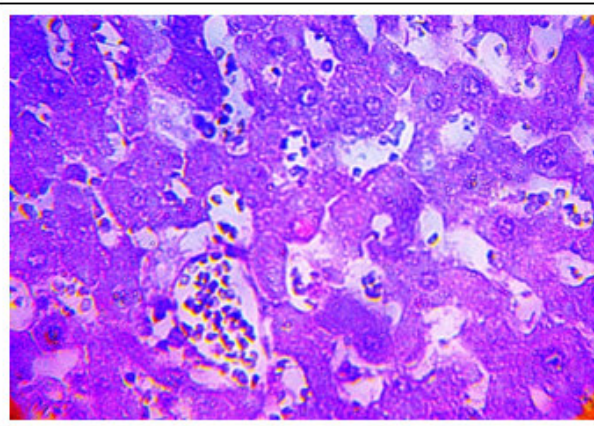


Figure-3:Light microscope photograph of liver section in AFP group. Showing moderate mononuclear cells inf in dilated synasoids with hepatocyte swelling with appearance of number apptotic hepatocyt. H&E. (X40)