

In Vivo Histological Evaluation of the Effect of Pomegranate and Aloe Vera and a Combination of Both on Wound Healing of Buccal Mucosa.

Zainab Mohammed Ali ^{1*} Ban A. Ghani Jamil ²

1. Master student. Department of Oral Diagnosis, College of Dentistry, University of Baghdad.

2. Assist. Professor, Department of Oral Diagnosis, College of Dentistry, University of Baghdad

Abstract

Background: Wound healing is a complex and dynamic interplay between various cell types, the extra cellular matrix (ECM), cytokines, and growth factors. Researches indicate that pomegranate and their extract may serve as natural alternatives due to their potency against a wide range of bacterial and viral pathogens. Methanol extract of the fruit especially the peel exhibit the broadest antibacterial activity. Studies on Aloe vera have proved the antiseptic, anti inflammatory, antiviral and antifungal properties and the use of this plant is proved beneficial. This plant is proved to be non allergic and very good in building up the immune system. Aim of the study was to evaluate effect of local application of pomegranate, aloe vera & mixture of both on acceleration of healing of oral mucosa. **Materials and methods:** Sixty adult male Wistar rats weighting an average of (250-300gm) were used in this study. Incisional buccal mucosal wound was induced in each animal and they were be divided into the following groups control (A) and experimental groups (pomegranate B, aloe vera C, pomegranate and aloe vera D). **Results:** Mean values of epithelial and stromal cells count at healing site increased with time and highly significant difference was recorded among all studied groups in different durations for epithelium, while for stromal cells highly significant difference was obtained at ten days.

Conclusion: The results of present study indicated that healing of buccal mucosa could be accelerated by combined topical application of pomegranate and aloe vera gel

Keywords: Aloe Vera extract, Methanolic extract of pomegranate peel, wound healing

1. Introduction

Wound healing is the process by which body tissues repairs itself after trauma. The undamaged tissues form a protective barrier against the external environment. When the barrier is broken, an orchestrated cascade of biochemical events is set into motion to repair the damage (*Orgill and Blanco, 2009*).

This process is divided into predictable phases: blood clotting (hemostasis), inflammation, tissue growth (proliferation) and tissue remodeling (maturation). Blood clotting may be considered to be part of the inflammation stage instead of a separate stage (*Stadelmann et al., 1998*).

The traditional importance of pomegranate as a medicinal plant is now being reinforced by emerging scientific data that demonstrate that the fruit contains significant anti-oxidant and anti-inflammatory activities and may exhibit anti-carcinogenic properties (*Syed et al., 2013*).

Ethanol extract of rinds of *Punica granatum* has the ability to accelerate healing in both normal and infected wounds because of its antimicrobial and antifungal activity on various types of bacteria and fungi (*Dahham et al., 2010*).

Interest is gathering among researchers regarding the use of this plant. Studies have proved the antiseptic, anti inflammatory, antiviral and antifungal properties of aloe vera and the use of this plant is proved beneficial. This plant is proved to be non allergic and very good in building up the immune system. Aloe vera is gaining popularity in dentistry as it is completely natural and there is no side effects being reported with its use (*Sujatha et al., 2014*).

2. Materials and Methods

- Aloe Vera extract
- Methanolic extract of pomegranate peel.
- Ketamin 50mg/ml
- Xylocain (10 %)
- Zylazine (20mg/ml).
- Formalin 10%, Ethanol alcohol 96%, Xylol, Paraffin wax.
- Hematoxylen and eosin (H&E).

Experimental design

Sixty male Wester rats age from 6-8 months were used in this study, their weights ranged between 250-400 grams, they were divided into control (A) and experimental groups B, C and D (15) rats for each. Incisional

wound was induced on buccal mucosa of each animal, and left to heal normally in group A, while groups B, C and D topical application of pomegranate gel, aloe vera gel and a mixture of both materials was done respectively.

Preparation of methanolic extract of pomegranate peel

The peel powder (25 grams) was mixed with 100 ml of methanolic alcohol at 30 °C for 1 hour by using a magnetic stirrer. The extract was filtered through Whatman No. 41 filter paper for removal of peel particles. The residue was re-extracted with the same solvent (Singh *et al.*; 2002). Aloe vera gel extracted by squeezing the leaves of the plant directly.

Histological preparation

Scarification of animals was done at 3, 7 and 10 days healing periods, all tissue specimens were fixed in 10% neutral formalin and processed following routine procedure. Each formalin-fixed paraffin-embedded specimen was cut into serial sections of 5µm thickness for staining with Haematoxylin and Eosin staining (H&E), and were examined by light microscope. Mean values of epithelial and connective tissue cell counting at wound site were statistically analyzed using SPSS (statistical package of social science) software version, the following statistics were used: Descriptive statistics means, standard deviations, minimum and maximum values, frequency (No.), percentages, and statistical tables and figures.

Inferential statistics including: One-way ANOVA test, LSD test.

3. Results

Histological findings

Three days duration

A-Control group

Microphotograph view at wound site of control group of three days healing period shows the cut edge of the wound, granulation tissue, scarce inflammatory cells adjacent a blood vessels (Figures1,2).

Experimental groups

B- Pomegranate gel group

Microphotograph view at wound site of three days duration shows granulation tissue near the cut edge of the wound, migrating epithelial cells, collagen fibers, fibroblasts (figures3, 4).

C- Aloe vera gel group

Histological findings of wound site of aloe vera group after three days, shows stromal granulation tissue, blood islets, collagen fibers and fibroblasts (Figures 5, 6).

D- Pomegranate and aloe vera group

Microphotograph of wound site of three days duration shows congested blood vessels, surrounded by inflammatory cells, granulation tissue, fibroblasts (Figure 7).

Seven days duration

A-Control group

Histological findings of control group 7days postoperatively shows new epithelium, organizing collagen fibers and fibroblasts in dermis (Figures8).

Experimental groups

B-Pomegranate gel group

After seven days of pomegranate gel application a microphotograph view shows wound surface is sealed by the newly formed epithelium, loose fibrous connective tissue, numerous blood vessels, detected in the dermis (Figures 9).

C-Aloe vera gel group

Histological section of aloe vera gel group of 7 days duration shows granulation tissue filling base of wound site and migrating epithelial cells are noticed at its edge, and stromal blood vessels, collagen fibers associated with fibroblasts are illustrated (Figure10).

D- Pomegranate and aloe vera group

Section at wound site of seven days duration after application of both pomegranate and aloe vera, shows complete closure of the wound by new epithelium, stromal collagen fibers and formative fibroblasts (Figures11).

Ten days duration

A-Control group

Histological findings ten days postoperatively revealed complete healing of wound area and it seems that newly formed epithelium is thickened, connective tissue fibers appear organized associated with fibroblasts (Figures12).

Experimental groups

B-Pomegranate gel

Microphotograph view after ten days shows cell layers of the new epithelium, progenitor cells, fibroblasts and

collagen fibers in dermis (Figure13).

C-Aloe vera gel group

After ten days duration histological section at wound site shows new epithelium and stromal connective tissues shows numerous blood vessels, organized collagen fibers (Figures14).

D- Pomegranate and aloe vera group

Histological findings of ten days duration for combination of pomegranate gel and aloe vera gel shows complete healing of wound site, well organized connective tissue fibers fibroblasts and blood vessels (figures15).

Assessment of epithelium and stromal connective tissue cell count among the studied groups :

Epithelium

Table (1) shows descriptive statistics of epithelial cell count/mm² of control (A) and experimental groups (B, C and D) at different healing periods (3,7 and 10 days) at wound site. It is noticed that the mean values of cell count of control groups increased with time, and highest values were recorded with D group at ten days. Regarding experimental groups (B, C, D) the mean values of cell count increased with time and the highest values were noticed with group D for all healing intervals. High significant difference was detected between all studied groups during each healing period.

As illustrated in (figure16) mean values were higher in experimental than in control groups, highest values were detected with group D at ten days duration.

Stromal connective tissue cells

As illustrated in table 2 the least mean values of stromal cells /mm² at wound site were detected in control groups and they increased with time (7. 24, 8. 14, 9. 98 respectively). Regarding experimental groups mean values were nearly the same among groups for each healing period.

High significant difference in the recorded values among the groups was seen at ten days, whereas significant and non-significant differences were noticed at three and seven days durations respectively. These findings are shown in (figure17).

Comparison between epithelial and stromal cells count in different durations

As illustrated in table 3, the highest mean values of epithelial cells (14. 50) was seen in group D at 10 days and (11. 88) at 3 days for stromal connective tissue cells. Highly significant difference between epithelium and stromal connective tissue cells was detected in groups C and D at ten days healing period, whereas significant difference was noticed in group A at 3days, B at 7 and 10 days . Those findings are shown in figure 18.

4. Discussion

Herbal ingredients of the mixture (pomegranate and aloe vera) were completely new; since no similar paper has been published up to now after screening web site for similar study for last few years. Therefore, to compare it with previous studies, it seems reasonable to consider each ingredients separately.

From the microscopic point of view, the mucosa that covers the mouth is represented by an external layer of epithelial cells that is supported by connective tissue of variable constitution. This mucosa is a protective barrier for the organism because it does not allow for penetration of any external agent that can be harmful to health (Neville *et al.* 2009).

However, the exact mechanism of the healing process of wound is not clearly understood there are a number of parameters which are involved in the healing of wound including histological results (re-epithelialization, granulation tissue, collagen accumulation, inflammatory, reaction, angiogenesis, ulcer formation (Kandemiri *et al.* ,2013).

At three days duration: Within 24 hours, neutrophils enter the wound site and scavenge cellular debris, foreign bodies and bacteria. After 2-3 days, the inflammatory cell population begins to shift to macrophages and fibroblasts appear in the wound site. After 3-5 days, the fibroblasts become activated and begin synthesizing collagen (Norton *et al.*, 2003). Deyhimi *et al.* , in 2016 who evaluated the histological influences of photodynamic therapy (PDT) on healing process of surgically made wounds on buccal mucosa of rat model and reported that at day 4 of follow-up, no difference was seen in healing stage among the groups which had almost the same histological grade at this time of experiment; and proliferation of marginal epithelium was initiated which was nearly similar to the findings of the present study during examination of the histological section at wound site of the studied groups, no obvious extreme differences was noticed.

Light micrograph of group A showed disruption in the epithelial continuity. Re-epithelialization process was noticed by the presence of a few proliferative epithelial cells at both edges of the wound not completely bridging the incision confined by findings of Mahmoud *et al.*, 2015 who investigated the acceleration of the healing process of vestibular/ gingival extension surgical procedure by modulating the cellular metabolism, accelerating tissue re-epithelialization.

The results of present study have shown that mean values of cell count of both epithelium and stromal CT of the studied groups increased with time ,and in general they were higher in experimental as compared to control groups, and highest values were recorded with D group indicating the progression of healing process as

recruitment and proliferation of cells was accelerated after application of pomegranate and aloe vera separately (B and C groups) and in combination (D group), with the enhancement of epithelialization sealing wound edges and besides granulation tissue deposition was noticed on histological findings with the differentiation and proliferation of fibroblasts that initiated collagen matrix

in agreement with findings of a study conducted in 2011, in which a traumatic ulcer in rat cheek mucosa was induced and approximately 3 days after the histological profile of the ulcer starts to present alterations, it is in this phase that the proliferation of blood vessels and fibroblast occurs, signaling the beginning of the repair (Cavalcante *et al.*, 2011).

At Seven days duration: Healing was observed at the incision area with re-epithelialization. The underlying connective tissue revealed dense, well organized collagen fibers and nearly devoid of inflammatory cell infiltration in agreement with Mahmoud *et al.* 2015. Generally during the histological analysis of wound site in the experimental groups (B,C,D) it was possible to observe the complete remodeling of the epidermis indicating the regression of lesion compared with the group A, which obviously appeared more prominent as time of healing progressed and that after day 7, re-epithelialization (the time for epithelial reconstruction) was observed and this period showed a typical histological picture of proliferative phase with detected fibroblast and new vessels in agreement with Alfars, 2009 who studied the early changes of wound healing in rabbits.

The increased rate of cell count with time could be due to the pomegranate extract that significantly enhanced the wound closure rate, which is confined by

clinical and biochemical survey with histological results obtained by Kandemiri *et al.*, 2013 who showed that oral administrations of pomegranate seed extract (PSE) exhibits potent healing properties on excision wounds, in rabbits model.

Histological examination showed the ability of Pomegranate gel (PG) to increase fibroblast infiltration, collagen regeneration, vascularization, and epithelialization in the wound area of diabetic rats. Neovascularization during wound repair serves a dual function by providing essential nutrients and oxygen to the wound site and promoting granulation tissue formation (Yan *et al.*, 2013), which agreed with this study concerning the effect of PG in accelerating cell proliferation as compared to control group.

Accelerated wound healing was observed in the group treated with Aloe vera (AV) as compared to control (Mendonça *et al.*, 2009) in agreement with the findings of the present study. Histologically wounds treated with aloe vera showed increase in macrophages, fibroblast migration, collagen regeneration and epithelialization compared with the control group (Jawad, 2014).

At Ten days duration: The histopathological findings of a study conducted in 2012, revealed formation of fibrovascular tissue (granulation tissue) which consisted of blood capillaries mixed with fibrous tissue, with re-epithelialization of the epidermal cell layer (Hassan *et al.*, 2012), which seems to agree with the examined histological section of this study at same healing period with thickened newly restored epithelium. In statistical analysis of epithelial cells count, highest mean values were detected with group D (application of combined P and AV gel) at ten days duration in agreement with (Bazafkan *et al.*, 2014) who found that a significant difference (in wound healing rate and epithelial cell count) was observed between the control and experimental groups in which the mean value were higher in experimental than in control groups and highest values were detected in the group of ointment application in his study.

The mean values of stromal CT cell count decreased with time which could be explained according to the fact that fibrous CT cell population and activity seems to be greatest at early phases of healing process since the stimulation of polymorphonuclear leukocytes (PMNS) aggregation may promote fibrinogenesis and concurrent fibroblast proliferation by increasing the release of connective tissue activating proteins (AL -Douri and Al-Kazaz, 2010).

According to web search for about last ten years, no investigation was found that has evaluated the effect of PG as combined with AV in an experimental model of buccal mucosal wound healing. The present study has explored the wound healing property of P, AV and has compared it with effect of both using buccal mucosa incisional wound healing. Wound closure appeared to occur earlier when mixture P, AV gel was applied to the wound. issue activating proteins (AL -Douri and Al-Kazaz, 2010).

References

- Abdalbari A. Alfars, HISTOLOGICAL STUDY OF EARLY EVENTS DURING WOUND HEALING IN RABBITS, Bas. J. Vet. Res. . 8 (1)2009 : 130.
- Al-Douri AS, Al-Kazaz SGhA. The Effect of Nigella Sativa Oil (Black Seed) on the Healing of Chemically Induced Oral Ulcer in Rabbit (Experimental Study). Al-Rafidain Dent J. 2010; 10 (1):151-157.
- AZZA H. M. HASSAN, M. D. 1,*; ALI M. SAAFAN, M. D. 2; SHERIF SAFWAT, M. D. 3 and TAREK M. IBRAHIM, Histopathological Evaluation of Low Level Laser Therapy (LLLT) on Oral Mucosal Wound Healing in Rabbits Under Corticosteroid Therapy M. D. 4 Med. J. Cairo Univ. , Vol. 80, No. 1, June: 375-384, 2012

- *D P Orgill; C Blanco (28 January 2009). "4 The Pathophysiologic Basis for Wound Healing and Cutaneous Regeneration". Biomaterials for Treating Skin Loss. Elsevier. pp. 25-. ISBN 978-1-84569-554-5*
- Dahham SS, Ali MN, Tabassum H, Khan M (2010) Studies on Antibacterial and Antifungal Activity of Pomegranate (*Punica granatum* L.). American-Eurasian J. Agric. & Environ. Sci. , 9 (3): 273-281.)
- Deeba N. Syed, Jean-Christopher Chamcheu, Vaqar M. Adhami, and Hasan Mukhtar* Pomegranate Extracts and Cancer Prevention: Molecular and Cellular Activities Anticancer Agents Med Chem. 2013; 13 (8): 1149–1161.
- F. M. KANDEMIR1,, A. SAGLIYAN2*, M. OZKARACA,, C. GUNAY, M. C. HAN,, F. BENZER. Revue Méd. Vét. , Effects of oral administrations of pomegranate seed extract on surgical wound healing in rabbits 2013, 164, 8-9, 400-408.
- G Sujatha, G Senthil Kumar, J Muruganandan,3 and T Srinivasa Prasad Clin Diagn Aloe Vera in Dentistry ,Res. 2014 ; 8 (10): ZI01–ZI02
- Galyléia Meneses Cavalcante; Renata Janaína Sousa de PaulaI; Leonardo Peres de SouzaII; Fabrício Bitu SousaIII; Mário Rogério Lima MotaIII; Ana Paula Negreiros Nunes Alves. Experimental model of traumatic ulcer in the cheek mucosa of rats. Acta Cir. Bras. 26 (3) : 227-34 . 2011.
- Maha Mahmoud, Marwa Madi, Nancy Mamdouh. Topical Surface Modifiers to Accelerate Healing and Re-Epithelization Process in Vestibular/ Gingival Extension Surgical Procedure Australian Journal of Basic and Applied Sciences, 9 (20) June 2015, Pages: 423-431.
- Mendonça FA1, Passarini Junior JR, Esquisatto MA, Mendonça JS, Franchini CC, Santos GM. Acta Cir Bras Effects of the application of Aloe vera (L.) and microcurrent on the healing of wounds surgically induced in Wistar rats. . 2009 Mar-Apr;24 (2):150-5.
- Mohammad Hassan Bazafkan , Ameneh Hardani , Mohammad Reza Afzal Zadeh, Ashraf Amir Zargar, Mahmoud Orazi Zadeh, Ali Asghar Hemmati, Esrafil Mansori, Maryam Ghasemiboroon , and Vesam Kooti Wound Healing Effect of an Ointment Made From a Mixture of Brassica oleracea var , Punica granatum , and Plantago major L Extracts in Rats , Jentashapir Journal of Health Research. 2014 t; 5 (4): e21877.
- Neville BW, Damm DD, Allen CM, Bouquot JE. Patologia Oral e Maxilo Facial. 3ed. Rio de Janeiro: Editora Guanabara Koogan; 2009.
- Norton, J. A. , R. R. Bollinger, A. E. Chang, 2003. Basic science and clinical evidence. Essential practice of surgery. New York. Springer-Verlag, pp: 77-88.
- Parviz Deyhimi, Heidar Khademi, Reza Birang, and Mohammad Akhoondzadeh J Dent (Shiraz). Histological Evaluation of Wound Healing Process after Photodynamic Therapy of Rat Oral Mucosal Ulcer . 2016 Mar; 17 (1): 43–48.
- R. A. M. Jawad. AL-Qadisiya. The antimicrobial and wound healing effect of Aloe Vera in induced diabetic rats) Journal of Veterinary Medicine Science 2014 ;13 (1): 7-14
- R. P. Singh , K. N. Chidambara Murthy , and G. K. Jayaprakasha . J. Agric. (Studies on the Antioxidant Activity of Pomegranate (*Punica granatum*) Peel and Seed Extracts Using in Vitro Models, Food Chem. , 2002, 50 (1), pp 81–86)
- Stadelmann, WK; Digenis, AG; Tobin, GR (1998). "Physiology and healing dynamics of chronic cutaneous wounds". American journal of surgery 176 (2A Suppl): 26S–38S.
- Yan H1, Peng KJ, Wang QL, Gu ZY, Lu YQ, Zhao J, Xu F, Liu YL, Tang Y, Deng FM, Zhou P, Jin JG, Wang XC. Effect of pomegranate peel polyphenol gel on cutaneous wound healing in alloxan-induced diabetic rats. Chin Med J (Engl). 2013;126 (9):1700-1706.

Table 1: Descriptive statistics and groups' difference in each duration for epithelial cells.

Duration	Groups	Descriptive statistics					Groups' difference d. f. =19	
		N	Mean	S. D.	Min.	Max.	F-test	p-value
3 days	A	5	4.92	0.81	3.7	5.9	7.882	0.002 (HS)
	B	5	8.80	2.04	6.2	11.3		
	C	5	7.44	1.72	5.7	10		
	D	5	9.34	1.44	7.7	10.9		
7 days	A	5	8.12	0.50	7.5	8.9	12.859	0.000 (HS)
	B	5	11.06	0.93	9.9	11.8		
	C	5	10.70	0.46	10.4	11.5		
	D	5	11.58	1.53	9.4	13.2		
10 days	A	5	10.24	2.28	7.8	12.6	10.183	0.000 (HS)
	B	5	12.20	0.85	10.7	12.8		
	C	5	11.22	0.57	10.7	12.2		
	D	5	14.50	0.53	13.7	15.2		

Table 2: Descriptive statistics and groups' difference in each duration for stromal CT cells.

Duration	Groups	Descriptive statistics					Groups' difference d. f. =19	
		N	Mean	S. D.	Min.	Max.	F-test	p-value
3 days	A	5	7.24	1.62	5.8	10	3.366	0.045 (S)
	B	5	10.06	2.08	7.3	13.8		
	C	5	11.00	2.16	7.9	14.1		
	D	5	11.88	2.02	7.8	16.3		
7 days	A	5	8.14	0.88	7.3	9.4	0.399	0.755 (NS)
	B	5	9.16	1.37	6.9	10.4		
	C	5	9.12	2.39	5.7	11.4		
	D	5	9.06	1.88	7.5	12.2		
10 days	A	5	9.98	0.63	9.3	11	6.053	0.005 (HS)
	B	5	9.74	1.53	8.4	12.1		
	C	5	6.42	1.87	4.7	8.6		
	D	5	9.62	1.77	6.9	11.4		

Table 3: Descriptive statistics and tissues' difference in each duration and group

Groups	Durations	Descriptive statistics				Comparison d. f. =8	
		Epi.		C. T.		t-test	p-value
		Mean	S. D.	Mean	S. D.		
A	3 days	4.92	0.81	7.24	1.62	-2.864	0.021 (S)
	7 days	8.12	0.50	8.14	0.88	-0.044	0.966
	10 days	10.24	2.28	9.98	0.63	0.246	0.812
B	3 days	8.80	2.04	10.06	2.08	-0.835	0.428
	7 days	11.06	0.93	9.16	1.37	2.559	0.034 (S)
	10 days	12.20	0.85	9.74	1.53	3.138	0.014 (S)
C	3 days	7.44	1.72	11.00	2.16	-2.800	0.023 (S)
	7 days	10.70	0.46	9.12	2.39	1.451	0.185
	10 days	11.22	0.57	6.42	1.87	5.482	0.001 (HS)
D	3 days	9.34	1.44	11.88	2.02	-1.698	0.128
	7 days	11.58	1.53	9.06	1.88	2.321	0.049 (NS)
	10 days	14.50	0.53	9.62	1.77	5.890	0.000 (HS)

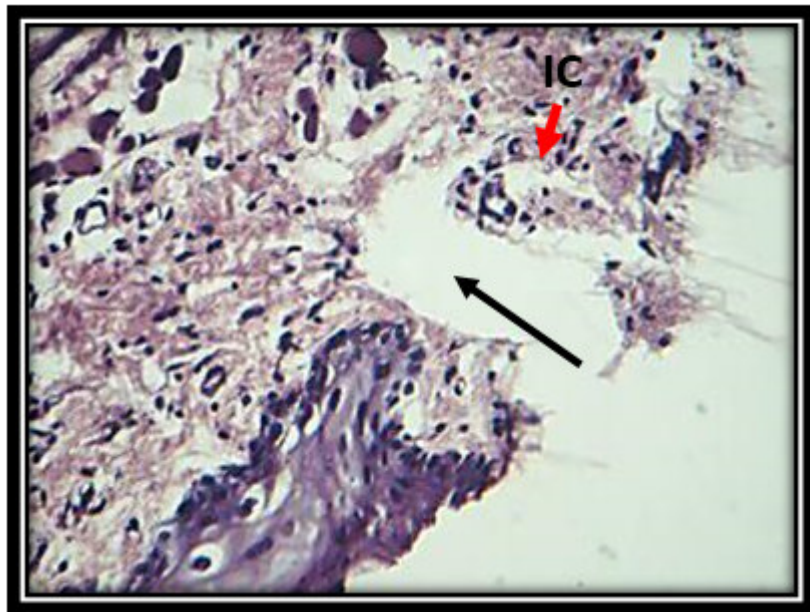


Figure1: View of 3days duration in control group shows cut edge of wound (arrow),inflammatory cells (IC). H&EX20.

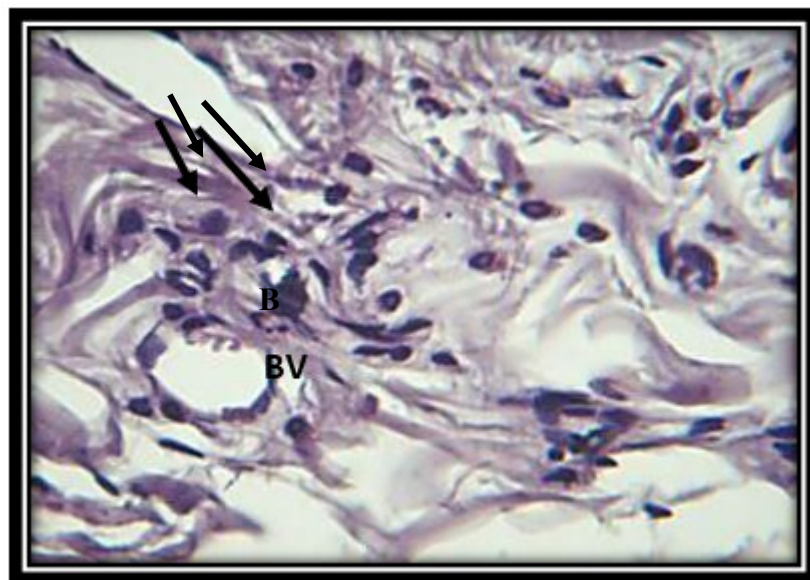


Figure2: View of 3days duration in control group shows accumulation of inflammatory cell near blood vessels (BV). H&EX40.

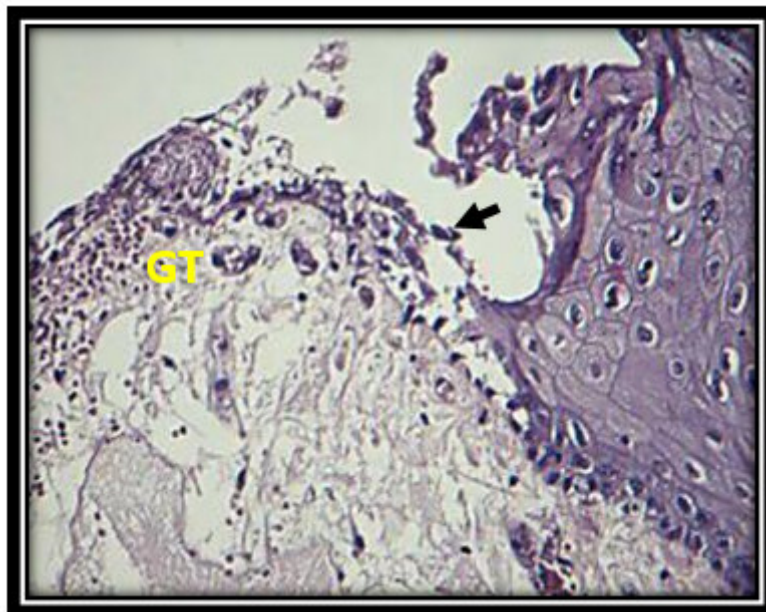


Figure 3: Microphotograph of wound site shows granulation tissue at cut edge of wound, migrating epithelial cells (arrow) . H&EX10.

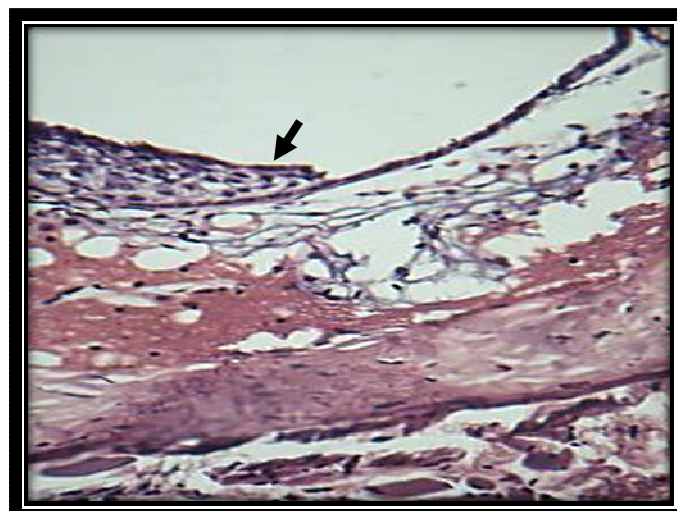


Figure 4: Microphotograph after 3days of pomegranate gel application shows migrating epithelial cells (arrow) at wound edge. H&EX10.

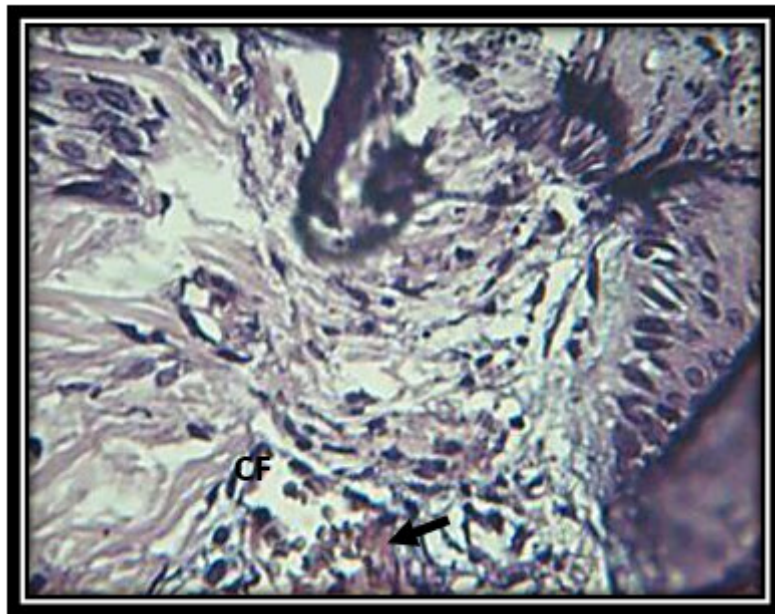


Figure5: Microphotograph of wound site of 3days duration shows remodeling collagen fibers (CF), blood islets (arrow) . H&EX20.

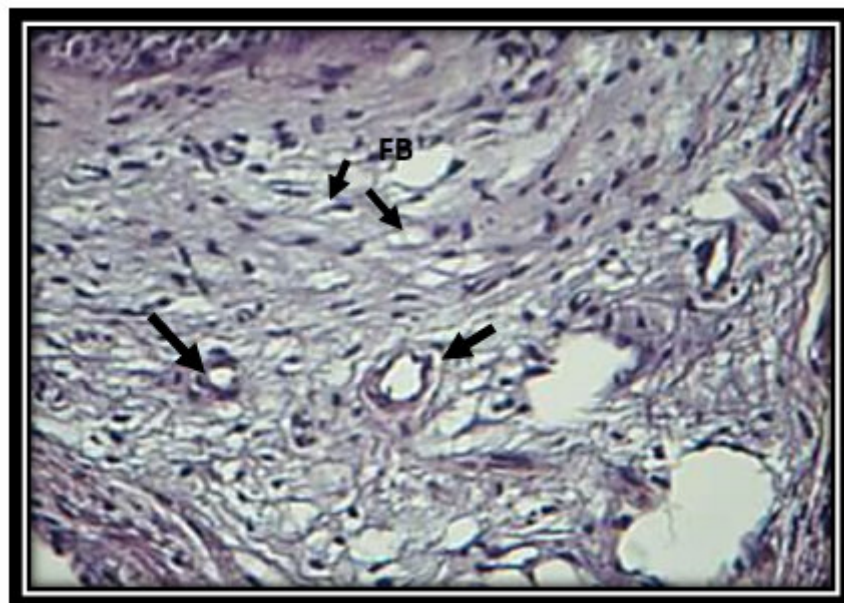


Figure6: Microphotograph after 3days of pomegranate group shows connective tissue with blood vessels (arrows),collagen fibers and fibroblasts (FB). H&EX20.

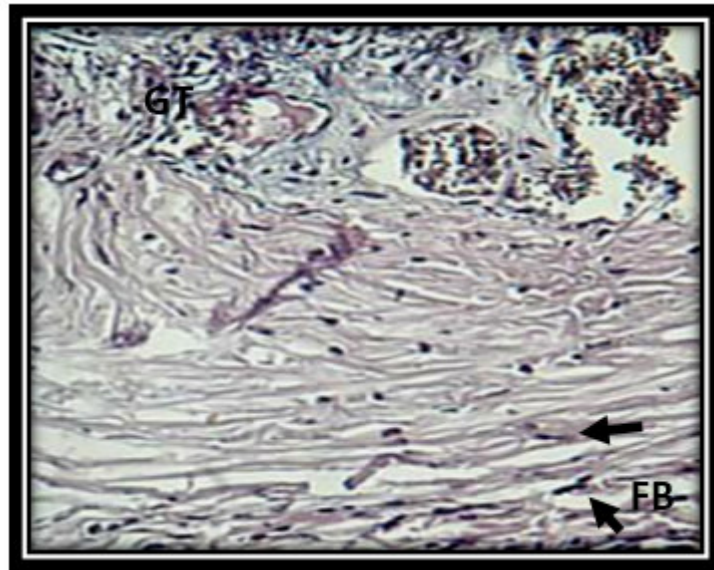


Figure7: Microphotograph of group D after 3days shows granulation tissues (GT),collagen fibers and fibroblasts. H&EX10.

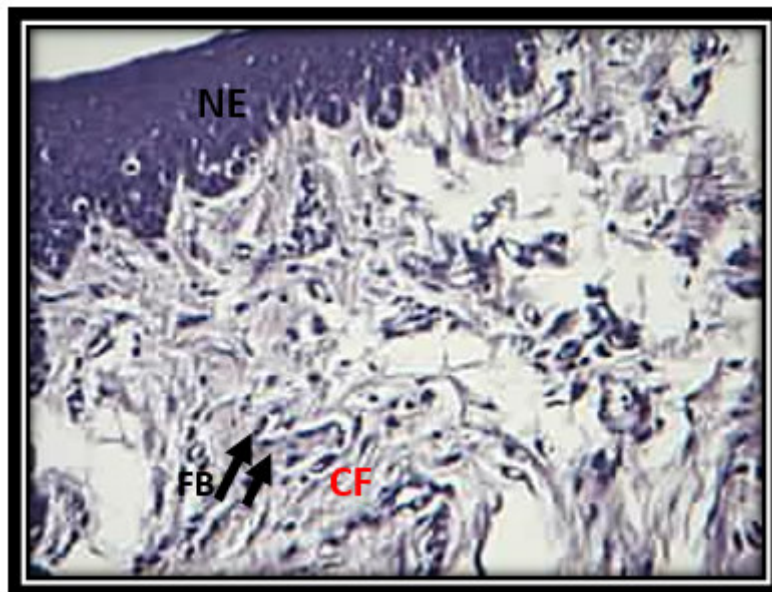


Figure 8: Microphotograph of 7daysduration of control group shows new epithelium, organizing collagen fibers (CF) and fibroblasts (FB). H&EX20.

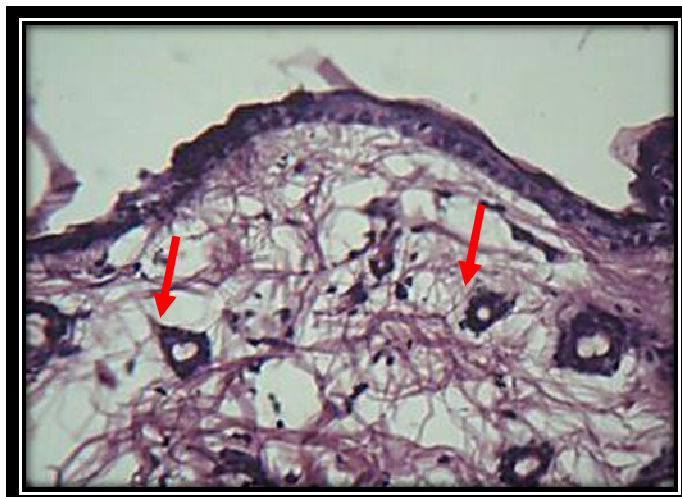

Figure9: View of pomegranate gel group 7days postoperatively, shows blood vessels (arrows), collagen fibers H&EX10.

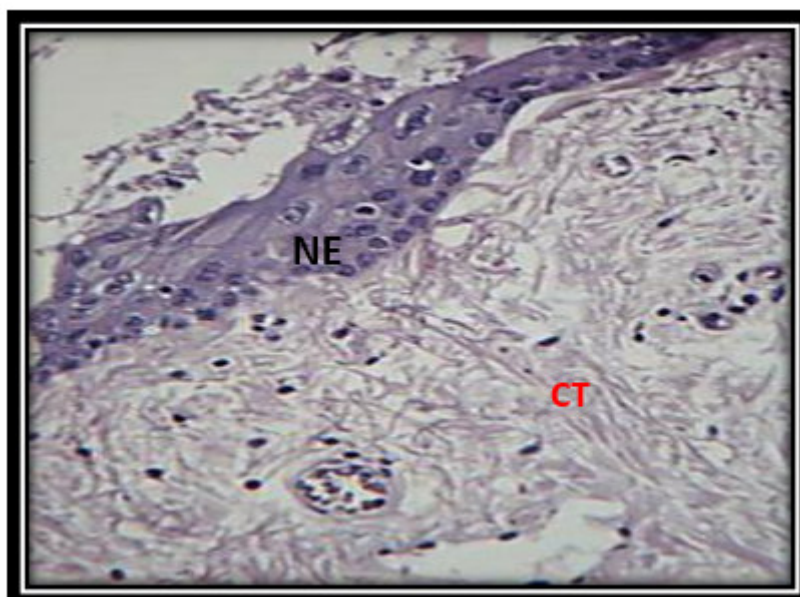


Figure10: View of aloe vera gel application group shows new epithelium (NE), fibrous connective tissue (CT). H&EX20 .

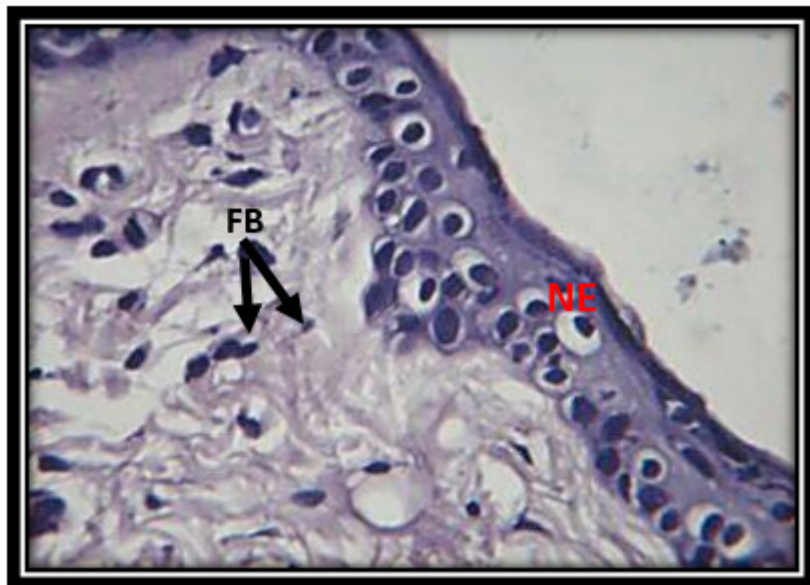

Figure11: Higher magnification of previous figure 3-15 shows new epithelium, fibrous connective tissue and fibroblasts (FB) . H&E x40.

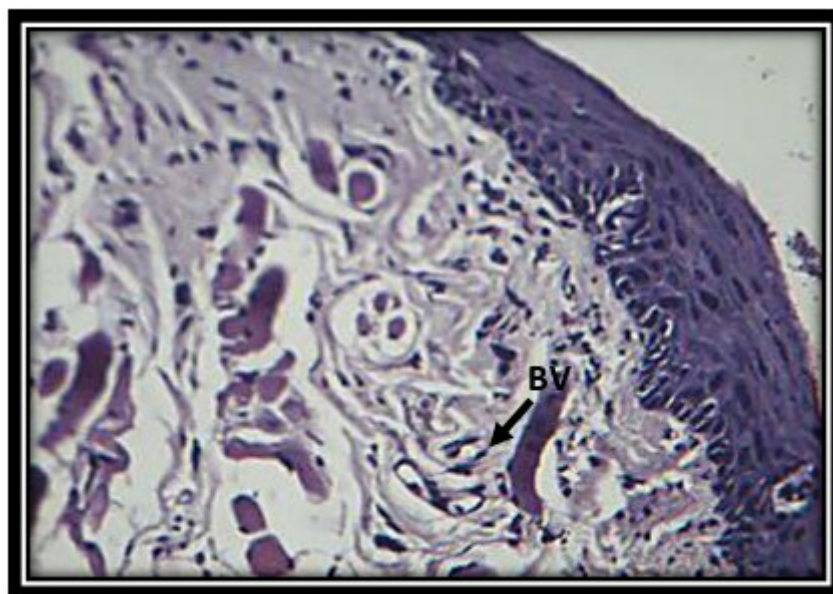


Figure12: View of wound site after 10 days of control group shows new epithelium, fibroblasts collagen fibers, blood vessels (BV). H&E x20

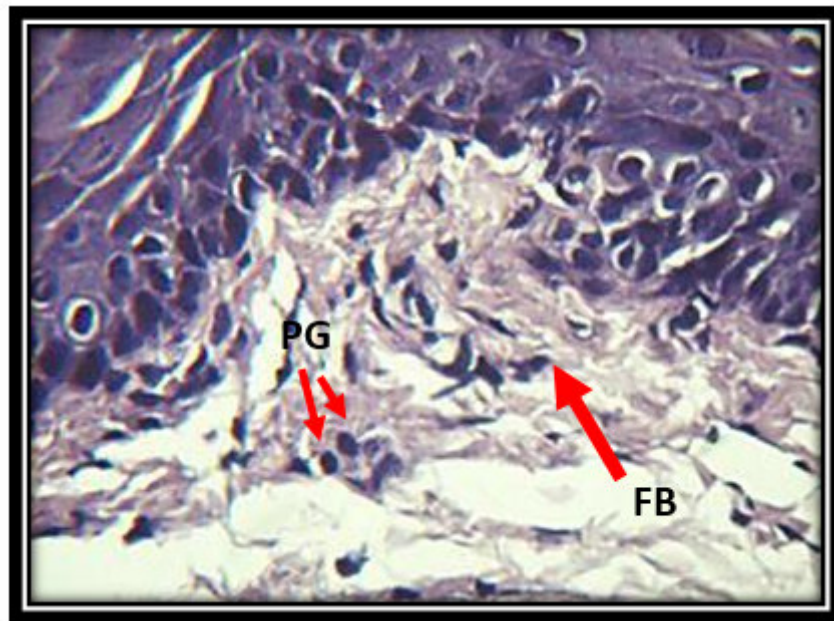


Figure13:View of 10 days duration of pomegranate group shows ,epithelial cell layers progenitor cells (PG)and fibroblasts (FB). H&E x40

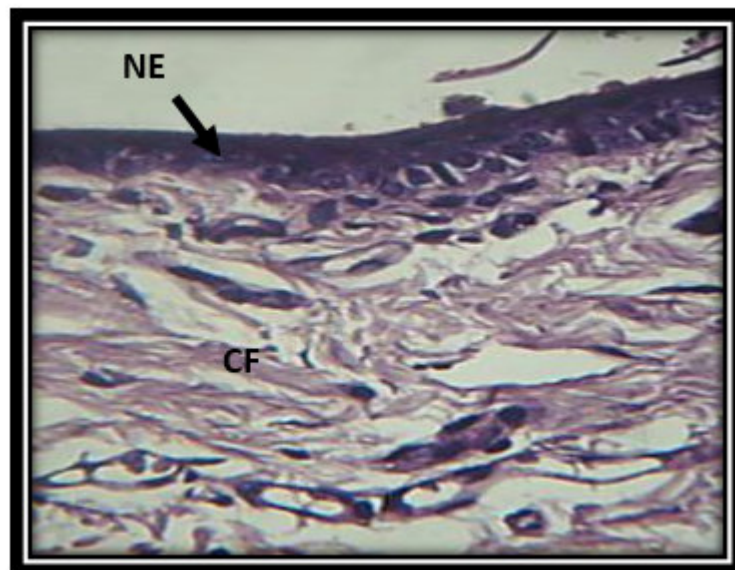


Figure14: View after ten days of pomegranate gel application shows new epithelium (NE) , collagen fibers (CF) ,fibroblasts . H&E x40.

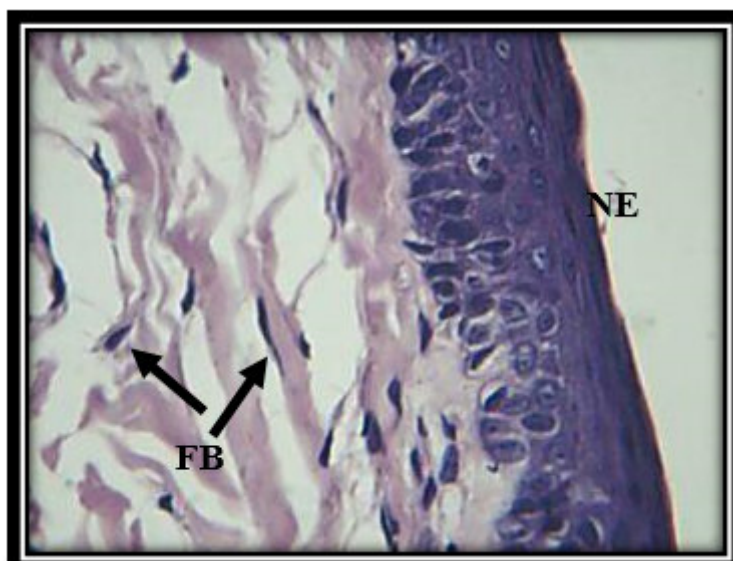
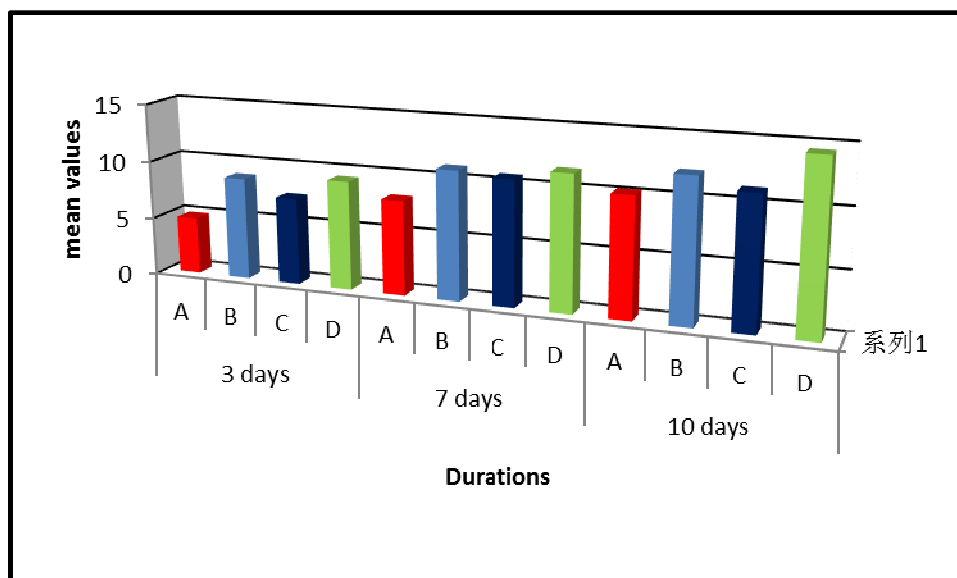


Figure15: View, shows epithelium, collagen fibers, fibroblasts . H&E x40.



A	Control
B	Pomegranate
C	Aloe-Vera
D	Aloe-Vera + Pomegranate (Combination)

Figure16: Comparison of the mean values of epithelial cell count among studied groups in different healing intervals.

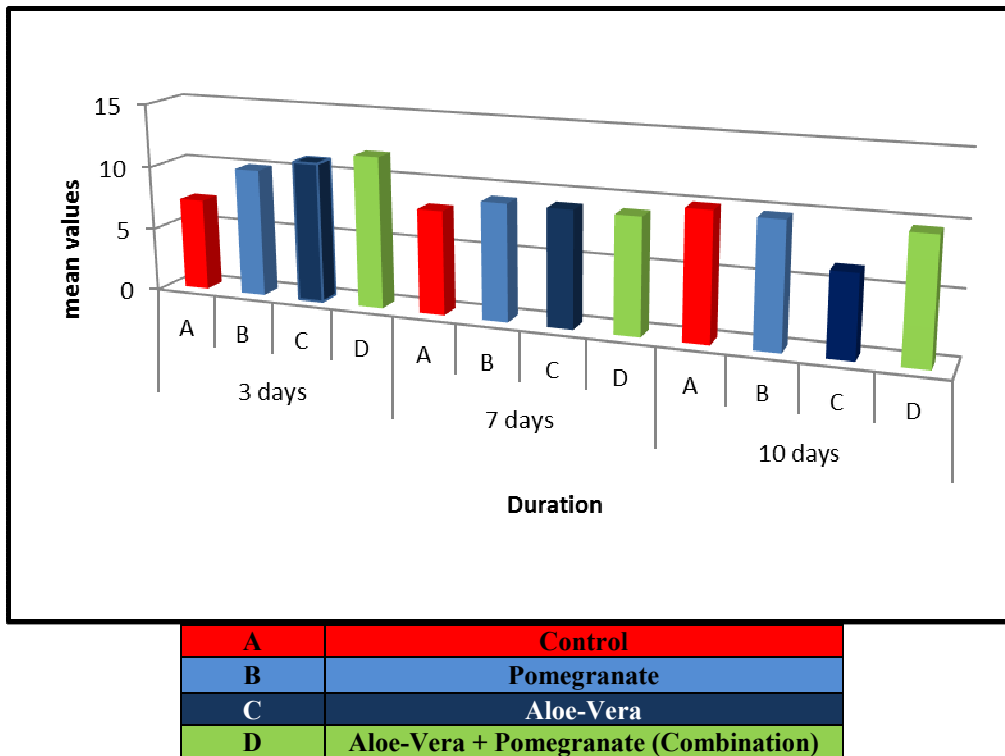


Figure17: Comparison of the mean values of stromal CT cell t among studied groups in different healing intervals.

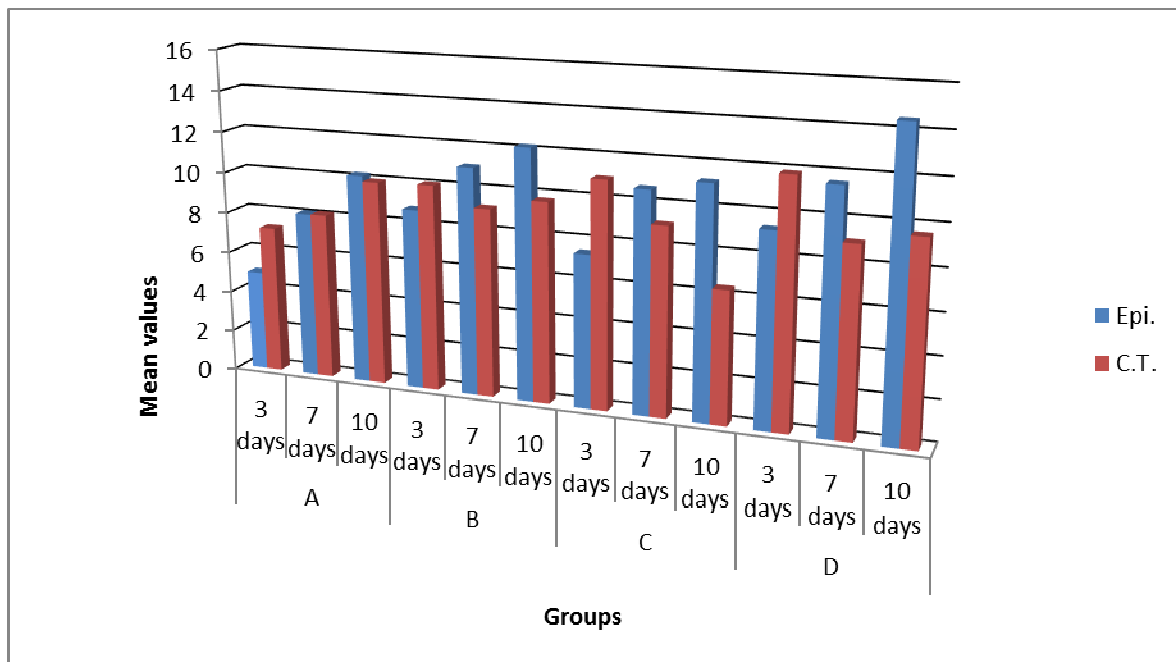


Figure18: Comparison of mean values of epithelial and stromal cell /mm² among studied groups in different healing intervals