

Effect of Organic Turmeric (*Curcuma longa*) Feeding on Testicular Histology of Rabbits Exposed to Ultraviolet Radiation

*¹Amao O.A, ²Togun, V.A, ³Adebisi, J.A, ²Williams, O.S, ²Oladipo, S.T.

¹Department of Animal Nutrition and Biotechnology, Faculty of Agricultural Sciences

²Department of Animal Production and Health, Faculty of Agricultural Sciences

³Department of Biochemistry, Faculty of Basic Medical Sciences,

Ladoke Akintola University of Technology (LAUTECH), P.M.B. 4000, Ogbomoso, Oyo State, Nigeria.

Abstract

A total of thirty six male rabbits ranging in weight between 450-600g were weight-balanced into six treatment groups that received rabbit diets either without turmeric (D₁) or with turmeric (D₂) at varying periods within a nine- week experimental period. The treatments were T0, T1, T2, T3, T4 and T5 for control, D₂ plus exposure to UV radiation, D₂ until radiation, D₂ after radiation, D₁ throughout the experimental period with UV radiation and D₂ throughout the experimental period without UV radiation, respectively. Testicular histology revealed that feeding organic turmeric in the diet before exposure conferred some protection on the testicular tissue while the feeding of turmeric in the diet after exposure corrected the damage inflicted by exposure to UV radiation. The group (T4) that did not receive turmeric showed conspicuous damage in the testicular tissue on exposure to ultraviolet radiation. It was concluded that organic turmeric could alleviate the histological damage on account of exposure to ultraviolet radiation.

Key words: Organic turmeric, Ultraviolet radiation, Rabbit, Testis, Histology

Introduction

Rabbits can be raised on high fiber feeds not utilized by man (N.R.C, 1981). Santoma *et al.* (1987) reported that rabbit in comparison with other livestock has a peculiar digestive physiology which permits the use of forages and industrial by-products, thus making it a non-competitive species with human food such as cereals.

Rabbits have some advantages that can be harnessed by smallholder farming system. The small body size, short generation interval, rapid growth rate, genetic diversity and high reproductive potentials are characteristics which make them suitable as meat producing livestock in developing countries (Arijenwa *et al.*, 2000). Rabbits give more kits and have shorter generation interval compared to other livestock like cattle, sheep and goats. Oseni (2008) suggested that two-thirds of research emphasis should be placed on smallholder rabbit units in backyards to enable them imbibe new technologies for improved production.

Turmeric plant (*Curcuma longa*) is a rhizome which has been mentioned as a spice and medicinal agent as early as 1600 BC in Rigveda and is consumed almost daily as condiments by the people of Nepal (Eigner and Scholz, 1999). The addition of different levels of Turmeric as feed additives was found to enhance the overall performance of broiler chicks (Durrani, 2006). The active ingredients found in turmeric are curcumin, dimethoxycurcumin, bisdemethoxycurcumin and tetrahydrocurcuminoids (Osawa *et al.*, 1995). Plant extracts of the turmeric were also found to have antifungal and anti-oxidative value (Osawa *et al.*, 1995). Pharmacological properties of *Curcuma longa* are nematocidal (Kiuchi *et al.*, 1993) and anti inflammatory (Ammon *et al.*, 1993). Consumption of turmeric has been associated with various beneficial effects on human health through protection against inflammatory, apoptotic and oxidative processes (Ammon and Wahl, 1991).

Ultraviolet radiation energy is an invisible light ray which living organisms are generally exposed to on daily basis. It has been indicated that when organisms are exposed to ultraviolet radiation, a constant fraction of the living cells are inactivated during each progressive increment in time (Davies *et al.*, 2002). Ultraviolet radiation inactivates the cells of the organism by absorption of light which causes a photochemical reaction that alters the molecular components essential to cell function (Davies *et al.*, 2002). Ultraviolet radiation induces the production of Vitamin D in the skin which helps bone growth and maintenance of bone density, immunity, cell proliferation, insulin secretion and maintenance of normal blood pressure (Vieth, 1999). Prolonged exposure to solar ultraviolet radiation may result in acute and chronic health effects on the skin, eye and immune system through mutagenic or carcinogenic process (USERPA, 1966). There is dearth of information on the use of turmeric to mitigate the harmful effect of UV radiation on reproductive organs of rabbit. This study was therefore conducted to investigate the effect of turmeric on the histological structure of testis of rabbits exposed to UV radiation.

Materials and Methods

The experiment was conducted at the Rabbit Unit of the Teaching and Research Farm, Ladoke Akintola University of Technology (LAUTECH), Ogbomoso Oyo State Nigeria. Thirty six male weaner rabbits of mixed breed (New Zealand White, California White, and Chinchilla) weighing between 450 - 600g were used for the

study. They were weight-balanced and allotted to 6 dietary groups of 6 replicates each. Each rabbit was housed individually for ease of data collection. Experimental diets were given to the animals for one week to acclimatize before data collection. The rabbits received diet either without 2% turmeric (D₁) or with 2% turmeric (D₂) at varying periods within the nine weeks of the experiment. The treatments were T0, (Control – No Turmeric, no UV radiation exposure); T1, (Turmeric feeding before and after UV radiation exposure); T2, (Turmeric feeding before and not after UV radiation exposure); T3, (Turmeric feeding after UV radiation); T4 (UV radiation exposure without turmeric feeding) and T5 (Turmeric feeding without UV radiation exposure). Rabbits were exposed to Ultraviolet radiation in a radiation box of 1 x 2m² equipped with fluorescent ultraviolet tubes measuring 0.61m. The rabbits were exposed for 10 minutes per animal per day for five days. Animals were slaughtered 30 days after exposure to ultraviolet radiation and the male reproductive organs were carefully removed for histological examinations. The histological analysis followed the standard procedure for slide preparation including fixation, clearing, dehydration, embedding, infiltration, blocking and staining.

Table 1: Gross composition (%) of the experimental diets

Ingredients (%)	D1 (- Turmeric)	D2 (+ Turmeric)
Maize	36.00	36.00
Groundnut Cake	5.00	5.00
Wheat offal	15.00	15.00
Palm kernel cake	27.00	25.00
Corn Bran	11.00	11.00
Turmeric	-	2.00
Other fixed ingredients	6.00	6.00
Total	100.00	100.00

Results and Discussion

The histological results are shown in Figures 1 to 6. Plate1 shows the testicular structure of rabbit fed the control diet (T5). The testicular structure was normal with seminiferous tubules full of spermatogenic cells. The lumen was intact and full with normal sertoli cells. The basement membrane was normal and showed no abnormality. Figure 2 shows the testicular structure of rabbit buck fed organic turmeric before and after exposure to ultraviolet radiation (T1). There were no major damages to the cells, but the seminiferous tubules suffered necrosis (seminiferous tubules were smaller), there was disintegration of the lumen with attendant effect on the epithelial lining of the cells. The necrosis resulted from the damages to the rabbits by exposure to ultraviolet radiation. Figure 3 shows the testicular structure of rabbit fed organic turmeric before but not after exposure to ultraviolet radiation (T2). There was no major damage to testicular cells but the seminiferous tubules in the lobules were smaller as a result of exposure to ultraviolet radiation. The lumen and the leydig cells were intact. Figure 4 shows the testicular structure of rabbit fed organic turmeric after exposure to ultraviolet radiation (T3). There were no major damages to the germinal, Leydig and Sertoli cells. The seminiferous tubules were normal with spermatozoa at various stages of development in the lumen. Figure 5 shows the testicular structure of rabbit not fed organic turmeric throughout the experiment but exposed to ultraviolet radiation (T4). Degeneration of basement membrane, germ and Sertoli cells were observed. The seminiferous tubules were distorted; the leydig cells were diffused into the lumen and spermatozoa were disorganized. The basement membrane and the germinal epithelial lining were disintegrated. Figure 6 shows the testicular structure of rabbit fed organic turmeric without exposure to ultraviolet radiation (T5). There was no major damage to the basement membrane, germ and Sertoli cells. The seminiferous tubules were normal with conspicuous spermatozoa at various stages of development. The Leydig cells were also intact.

The histological results showed that rabbits that were not exposed to ultraviolet radiation had no damage to their cells. Necrosis was observed in the rabbits exposed to UV radiation. Robin *et al* (1981) and Pamphilon and Wallington (1991) reported that necrosis is the morphological change caused by the progressive degenerative action of enzymes on the lethally injured cells. Powell *et al.* (1993) reported that UV radiation is known to affect the cell membranes of living organisms. It changes the cell surface antigens thereby blocking the cell to cell interactions and antigen introduction.

Conclusion

Turmeric treatment has been found to ameliorate the effect of UV radiation in this study. It could be concluded that consumption of organic turmeric could serve as prophylactic and curative treatment for reproductive damages that may result from exposure to UV radiation.

References

Ammon, H.P and Wahl, M. A. (1991). Pharmacology of *Curcuma longa*. *Planta Med.* 57:

- 1-7.
- Ammon, H., Safayhi, H, Mack, T. and Sabieraj, J. (1993). Mechanism of anti-inflammatory actions of curcumin. *J. Ethnophar.* 38: 113-119.
- Arijeniwa A., Otaikhian S.O., Imaseun J.A. 2000. Performance of weaner rabbits fed grower diets supplemented with different grass legume rations. In: *Proc. 5th Annual conference of Animal Sci. Ass. Nig. (ASAN), 2000 September*, 103-105.
- Davies, H., Bignell, G.R. and Cox, C. (2002). Mutations of the BRAF gene in human cancer. *Nature* 417 (6892): 949-954
- Durrani, F.R., Ismail, M., Sultan, A., Suhail, S.M., Chand, N. and Durrani, Z. 2006. Effect of different levels of feed added Turmeric (*Curcuma longa*) on the performance of broiler chicks. *Journal of Agricultural and Biological Science* 1: 9-11
- Eigner, D. and Scholz, D. (1999). *Ferula asa-foetida* and *Curcuma longa* in traditional medicinal treatment and diet in Nepal. *J. Ethnopharmacol.*, 1999, 67, 1-6.
- Joe, B and Lockesh, B. R. (1994). The role of cucumin and dietary n-fatty acids in lowering the generation of reactive oxygen species in rat peritoneal macrophages. *Biochemistry and Biophysiol.* 1224: 225-263.
- National Research Council, (NRC) (1981). Nutrient Requirements of Domestic Animals. No. 9. Nutrient Requirement of rabbits. Second Revised Edition, National Academy of Science. National Research Council, Washington D.C.
- Osawa, T., Suguyama, Y., Inayoshi, M. and Kawakisi, S. (1995). Anti-oxidative activity of tetrahydrocurcuminoids. *Biotechnol. and Biochem.* 59: 1609 - 1611
- Oseni S.O. (2008). A proposal for the genetic improvement of rabbits for smallholder units in Nigeria. *9th World Rabbit Congress – June 10-13, 2008- Verona – Italy*. P 464.
- Pamphilon, D.H., Alnaqdy, A.A. and Wallington, T.B. (1991). Immunomodulation by ultraviolet light: Clinical studies and biological effects. *Immunol. Today.* 12: 119 – 123.
- Santoma, D. J.C., Carabrano, R., and Fraga, M.J. (1987). Butterworth Litho Preparation Department G. *Brit.* 109-134.
- Powell, M. B., Rosenberg, R. K., Graham, M.J., Birch, M. L., Yamanishi, D. T., Buckmeier, J. A. and Meyskens, F. L. J. (1993). Protein kinase C beta expression in melanoma cells and melanocytes; differential expression correlates with biological responses to 12-0 tetradecanoylphorbol 13- acetate, *J. Cancer Resource Clinic.* 119:199-206.
- United State Environmental Protection Agency (USERPA) (1996). Water-US Environmental Protection Agency.
- Vieth, R. (1999). Vitamin D supplementation, 25-hydroxyvitamin D concentrations and safety. *American Journal of Clinical Nutrition* 69 (5): 842 - 856

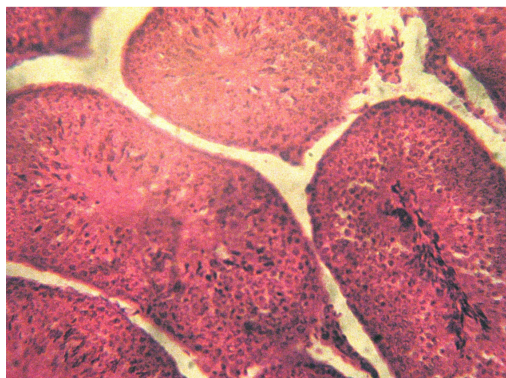


Figure 1. Testis of Control rabbit (No turmeric, No UV radiation)

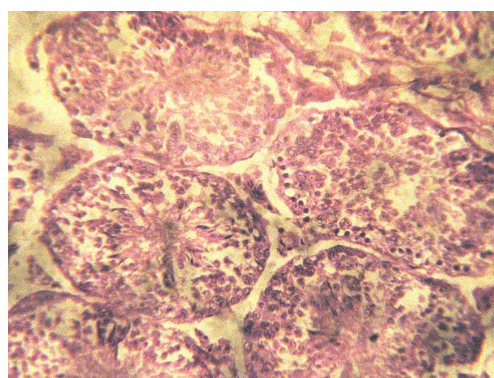

Figure 2. Testis of rabbit fed turmeric before and after UV radiation

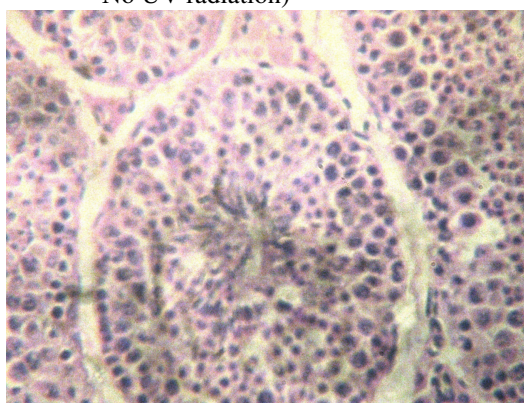


Figure 3. Testis of rabbit fed turmeric before exposure to UV radiation

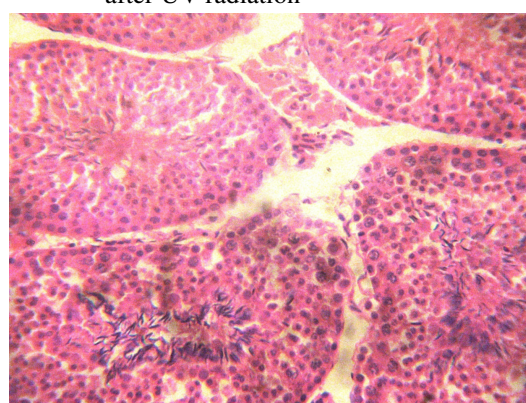


Figure 4. Testis of rabbit fed turmeric after UV radiation

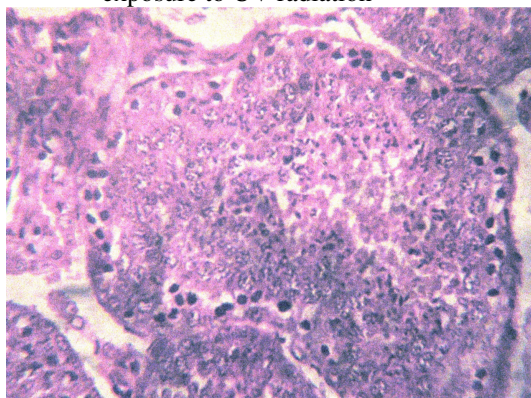


Figure 5. Testis of rabbit exposed to UV radiation without turmeric feeding at all

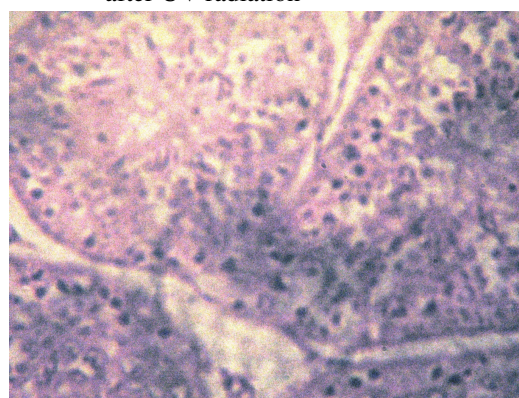


Figure 6. Testis of rabbit fed turmeric without exposure to UV radiation at all