

Effect Of Alcoholic Extract Of *Costus speciosus* Koen. on *Aspergillus fumigatus* in lab rats (II)

Neeran Obied AL-Ameri^{1*} Zahraa Falah Azeez,²

1.College of Pharmacy / Al-Qadisiya University/Diwaniya/Iraq

2. College of Science / Al-Qadisiya University/ Diwaniya/Iraq

* Email of the corresponding author: Neeranasim@yahoo.com

Abstract

This study was designed to find out the therapeutic efficiency of alcoholic extract of *C. speciosus* in the treatment of pneumonia caused by fungus *A. fumigatus*, in the study (30) of male rats eggs *Rattus norvegicus* injury experimentally two solution spores of a single dose of (25)µ size and concentration of 10⁷ units consisting of the colony / ml by distillation inside the nose. Results of the study pathological macroscopic and histopathological ability of fungus to the events of infection, pneumonia when an autopsy after (14 days) from injury was infiltration of cells of the inflammatory and the emergence of edema and emphysema, and after the onset of clinical symptoms of weakness and difficulty breathing during the first week of injury the second group were treated extract of the plant at a dose (75 mg / kg) daily for a period (21 days) with oral dosage using the tube stomach. And proved the results obtained from the study of histological sections impact the effective and positive role for the test in the treatment represented by a restoration of the lung tissue to be mounted typical natural.

Keywords: *Costus speciosus* , *Aspergillus fumigatus* , histological effects.

Introduction

Includes genus *Aspergillus* many of medically important species known to its ability to bring a wide range of clinical diseases in humans and animals (Batra, et.al.,2006). As these fungi cause disease *Aspergillosis* who have lung or deployed (systemically) or Cutaneous (Ellis , 1994). The pulmonary *aspergillosis* disease the most common forms of infections between mixed pulmonary infections (Latge , 1999) It is a species belonging to this genus opportunistic pathogens able to events of infection through spores that aerobic able to access alveoli is weakest airflow due to its small size and the existence of factors that increase the severity of the infection of the host , and that makes the fungus is able to overcome the basic defensive lines for the host to lead eventually to cause infection to a range of hypersensitivity reactions to direct systemic infection , In addition to genetic and physiological methods multi-taken by some species of the genus *Aspergillus*, as *A. fumigatus* to avoid host defenses, causing disease and injury as production toxins and enzymes abroad mobiles, which is one of the most important virulence factors inherent in this fungus (Cho et.al.,2005) It is responsible for 90% of *aspergillosis* diseases (Sharif ,2012) Often the symptoms and clinical signs is clear and does not indicate the type of causative . In general, the severity of the infection depends on the host's immunity and virulent fungus (Alpsoy, 2010). . As for the antibiotics used in the treatment, there are many of them that work by different mechanisms, but the work of these antibiotics has a lot of nice negatives, mostly very narrow spectrum in inhibiting or killing fungal species as well as the deployment of many of the isolates were resistant to most antibiotics (Amine , 2008) In view of the recent trends in the use of medicinal plants as a treatment method and these plants *C. speciosus*, who belongs to the family *Zingiberaceae* (Choudhury,et.al.,2012). Rhizome of this plant used medically to contain the many of active compounds such as :prosapogenin B of dioscin , dioscin , gracillin , methyl protodioscin , methylprotogracillin ,protogracillin , diosgenin and other active compounds (Inoue,et.al.,1995).Antifungal activity of steroid saponins and saponogens of this plant was

analysed by Singh (Singh ,et.al.,1992) the antifungal activity on six species of pathogenic fungi was tested at different concentrations.

So the present study aimed to identify these efficiency towards *A.fumigatus* in vivo through the study of the effect of methanol extract of the plant toward the pathological changes of macroscopic and histopathological Caused by these opportunistic fungi in the lungs of lab rats .

Materials and methods

- **The research was conducted in the laboratories of the College of Science /University of Qadisiyah .**
- **Plant Materials**

Powder of *Costus speciosus* (Koen ex. Retz.) root was obtained of herbalists stores equipped with the consent of the Ministry of Health / Herbal Medicine Center, and is subject to examination and diagnosis of the health aspects and pharmacological effectiveness. The company has filled in the food business life, Amman – Jordan.

- **Preparation of plant extracts**

25g of the dried and powdered form of rhizome of *C. speciosus* was extracted successively with methanol 80% (each 250 ml.) using a Soxhlet apparatus . Then collected solution were filtered through Whatman No. 4 filter paper . The extracts were evaporated to dryness under reduced pressure at (50-45C°) by Rotary vacuum evaporator to obtain the respective extracts(Veeramuthu,et.al.,2012) to while getting the dried powder and stored in a freeze condition at (4C°) until used for further analysis.

- **Tested fungal and prepare fungal suspension**

Has been the development of fungi *A.fumigatus* isolated from lower respiratory tract infections to humans on the Sabouraud's Dextrose Agar and incubated at a temperature (37°C) for (7 days). Under sterile conditions developing colonies flooded about (2 ml) of physiological salt solution (0.85%) and using Loop separate the top of the colony and added a drop of material Tween 80 (0.01%) to reduce the surface tension. Collected spores in a glass tube and mixed device Vortex mixer . Spores suspended with a phosphate buffer solution to the became commentator absorbency of light (0.1) at wavelength 530 nm, equivalent to (107 spore / ml)(Espinel – Ingroff,et.al.,1995) .

- **Experimental infection**

In order to bring about pulmonary infection, Injected three groups of male albino rate type of *Rattus norvegicus* weighing 180-100 grams, through intranasal administration (I.N) a rate of 10 rats per group, the first group injected with (25 μ) of normal saline solution while animals remained second and third groups were injected with a single dose only amount (25 μ) of airborne fungal its focus(107 spore / ml) after it has been weakening the immune system by Hydrocortisone according to Naji method(Naji,et.al.,2006). Animals leave for a week until the signs of fatigue, weakness, loss of appetite as evidence of the incidence of fungal , then were given alcoholic plant extract solution (75 mg / kg) daily for a period (21 days) by oral dosing using a stomach tube. After the end of duration of the experiment had killed all the rats by intraperitoneal injection (I.P) at a dose of Ketamin and Xylazine about (5)

and (50) mg / kg of body weight for both anesthetists, respectively, were conducted anatomical, removed the lungs and fixed in a solution of formalin regulator neutral concentration (10%), and then attended the tissue sections and dye Hematoxylin & Eosin dye for the purpose of studying the pathological changes of gross and histological caused by the fungus and the therapeutic efficiency of the plant extract solution alcohol according to Bancroft and Stevens method(Bancroft, . &Stevens , 1982).

RESULTS

▪ Gross pathological changes

In the group of rats treated with a solution of spores only for magnified was observed in the lungs compared to the control group (Figure 1) as it was suffering from the presence of the different stages of pneumonia appeared congested then red hepatization with a bleeding spots. While the observed group treated with a solution of alcoholic extract of the plant the same marks but less severe (Figure 2) compared with control group (Fig.3)

▪ Histopathological changes

Results showed diagnostics microscopic sections tissue taken from the lungs of rats of the control group installation normally and not appear any pathological changes them, as observed alveoli separated from each other barriers between the alveolar Inter-alveolar septa is a typical problem of most of the lung tissue (Figure 4)and looks layer lining the bronchi regular aerobic typical (Figure 5)

explained microscopic examination of tissue sections of the lungs of rats treated in a solution of fungal spores and the presence of the causative agent of infected , as noted many of the pathological changes of tissue represented the presence of liquid and edematous (Edema) between the cells forming the wall of the alveolar pneumonia and emphysema and desquamation in the epithelial cells lining the bronchi and condensation of the cells lymphocytes around blood vessels (Perivascular lymphocytic cuffing) and around bronchioles (Peribronchiolar lymphocytic cuffing) and leaching of fluids hematoma as well as the bloody congestion within the blood vessels.(Fig.6m7m8)While (Fig.9,10,11) explaining Infected lung treated with extract of *C.speciosus* appear, natural air alveoli, alveoli is shape recovery less congestion, bronchi its natural form

Discussion

That the injury fungal Aspergillosis caused by penetrating fungus host defenses natural and acquired it can grow in the cells of the human and natural laboratory and this is what can the results of the current study and the changes that have been observed in the current study and appeared clearly in the pathological changes in the lung tissue of rats injected inside the nose solution spores fungus *A. fumigatus* marked by the presence of emphysema clearly with severe hyperplasia in the lining layer of the bronchi and bloody congestion and these diseases are in line with the symptoms of pneumonia(Naji,et.al.,2006) It seems clear from the pathological changes This may be attributed the cause to the content solution casual fungus from the secretions of fungal and which caused an increase blood pressure for (Microcirculation) and thus to increase the permeability of capillaries and hemoglobin free from red blood cell (Intravascular hemolysis) in addition to stimulating the production of (Proinflammatory mediators) such as($TNF-\alpha$) the charge for the crash in most parts of the body(Rivera,et.al.,2003). In addition to Hydrolytic enzyme promotes portability fungus disease , where the work of these enzymes to break down the cell membranes and the invasion

of tissues host, leading to dysfunction or physical disruption which is caused by the imbalance in the homeostasis of Procedure of the body the host (Sharif,2012), as well as some fungi of the genus *Aspergillus* take genetic techniques and physiology of multiple to avoid host defenses, causing disease(Alpsoy, 2010) It is worth be noted that factors virulence This represented a portion of the genotype is responsible for pathogenicity size (0.95 Kb) called (0.95 Kb positive strain) vary from isolates which is responsible for pathogenicity fungus (Roederm et.al.,2004), and is working to motivate and make the inflammatory response through its impact in stimulating the secretion of attractions chemical (Chemotactic factor) for initially neutrophil which showed the failure of the elimination of the cause entirely, given owned fungus-resistant gorging or phagocytosis through inhibition or curb the phagosome and objects case Lysosome (Casadevall ,2003). And watch the components of the causative agent of infection within infected lung tissue is considered conclusive evidence of injury and these findings are consistent with (AL-Ameri,2005) that the presence of mushrooms *A.fumigatus* filament within the host tissue is considered conclusive evidence of the incidence of this fungus.

In other hand, the results of the study showed that the treatment plant extract *C.speciosus* methanol has contributed to the reduction of the manifestations of the macroscopic changes, as macroscopic changes became less severe and perhaps closer to nature in the control group this leads us to that plant extract testing positive impact in improving and shows clearly the capacity and efficiency abstract lab translate decline in most of the negative effects and changes histopathological injury and restore tissue visceral pneumonia to fit typical usual almost appeared bronchioles air regularly almost layer epithelial interior where the form clear about cavity a fairly regular , featured alveoli is with installation tissue regularly almost when compared with those in rats , and appeared vascular regular wall and is congested and occupies a site adjacent to the people of aerobic , these findings are consistent with what was confirmed by Sanna (Sanna, et.al., 2012.) May translate the antioxidant activity, therapeutic efficacy in terms of some of the recent research confirmed scientifically validated(Gupta , 2010) That owning plant extracts *C. speciosus* the effectiveness of anti-oxidants, plant containment (Polyphenol) and owning Mstkhalsath active anti-oxidants is the frequent presence of hydroxyl radicals that work sweeping free radicals(Free Radical Scavenger) that is, they work to prevent the oxidation of the basic cellular components as a result of the accumulation of free radicals and tissue damage induced by the injection solution fungus spores *A. fumigatus*, thus, they are protecting cellular membranes and membrane organelles which gives protection and power necessary for the performance of their actions vital to effectively great at the same time you are working on the revitalization of several enzymes such as (Catalase, Dismutase, Superoxide) that works synergy Synergism with antioxidants other to protect cells in the body(Islam,et.al.,2010)

While the treated group showed with the alcoholic extract of the plant tissue pathological changes less severe than the previous group counterparts, as observed the presence of pulmonary emphysema less with no excess and alveoli with a radar installation composition as well were almost regular.

Conclusions

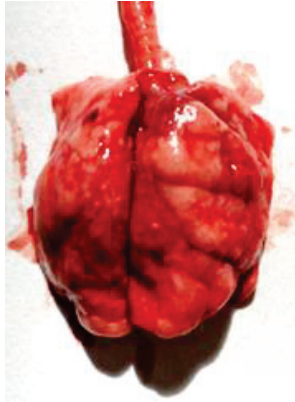
We conclude from this study that possible use of the plant under study as an alternative to chemotherapy

References

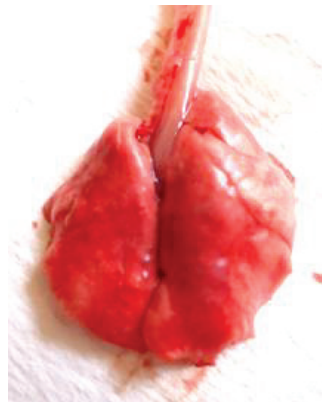
AL-Ameri, N.O.(2005). A study of taxonomy Epidemiology of pulumonary mycotic infectionin Al-Qadisyia Province .Ph.D. Thesis. Collage of Education-Al-Qadisyia Universi

- Alpsoy, L.(2010). Inhibitory effect of essential oil on aflatoxin activities . Afr . J. Biotechl.,9(17);2474-2481p.
- Amine , A. (2008) . Ketoconazole – induced testicular damage in rate reduced by Gentian extract , Experimental and toxicology pathology . 59:377-384 .
- Bancroft, J.D. and Stevens , A.(1982) . Theory and practice of histological techniques. 2nd (ed.) churchill living stone , Edinburgh, London.pp.662.
- Batra, V.,B. Asmar and J. Y. Ang. (2006). Aspergillosis. EMedicine D:/Medical Mycology/eMedicine-Aspergillosis Article by Vandana Batra MD.htm.
- Casadevall , A.J.; Steenberger Y. and Nosane chuk , D.J.(2003). Read made Virulence and dualuse virulence factors in pathogenic environmental fungi paradigm Curr. Opin. Microbiol. 16:332-337 .
- Cho, S.H., S.C. Seo, D. Schmechel, S. A. Grinshpun and T. Reponen. (2005) . Aerodynamic characteristics and respiratory deposition of fungal fragments Atmospheric Environment , 39:5454-5465 .
- Choudhury N.; Kalita J.C. and Haque A.(2012) . Effect of Costus speciosus (Koen) on Reproduction organs of Female Albino Mice .Choudhury Najma .ISSN 2230-8407
- Ellis , D.H. (1994). Clinical mycology : The human opportunistic mycolsis. Gillingham . Printers pty .Ltd . Australia . 166p.
- Espinell – Ingroff,A. Kerkering ,T.M., 1995. Spectrophotometric method of inoculum preparation for the in vitro susceptibility testing of filamentous fungi. J.Clin Microbiology. (2) : 392- 393 .
- Gupta , R.K.(2010) . Medicinal and Aromatic Plants , CBS Publishers and Distributors , Journal of Medicinal plants Research .p 234-499
- Inoue, K., Kobayashi, S., Noguchi, H., Sankawa, U., Ebizuka, Y.(1995). Natural Medicines , 49(3),336-339 .
- Islam , A.; Jfa . M.K.;Alam , M.B. and Hossain, M.S.(2010) . In vitro Antioxidant and Cytotoxic potential of Costus speciosus (Koen.) smith rhizome . IJPSR. Vol. 1(10):138-144 .
- Latge , Jean-Paul . (1999) . Aspergillus fumigatus and Aspergillosis . Clinical microbiology reviews . 310 – 350.
- Naji, Wedad Naji, Mohammad Sabri and Hassanein Khalil (2006). A study of some histological changes of mice experimentally infected with some fungi isolated from human patients with tuberculosis. Babylon University Journal of Pure and Applied Sciences. V. (12), N.(3).
- Rivera , C.; Tcharmatchi, M.; Mendoza , L. and Smith , C. (2003) . Endotoxemia and hepatic injury in arodant model of hindlimb unloading . J. App. Physiol., 95:1656-1663 .
- Roeder ,A.C.;Kirching , R.A.Q.; Pupec , M.; Schaller and Korting H.C.(2004). Toll-Like receptors and innate antifungal respone trends microbial , 12: 44-49 , Eukaryotic cell. J.Am.S. Microbiology , 3(5): 1097-1075 .
- Sanna, A.,Khalifa, A., and Dalia, M.(2012). Histological and ultrastructural studies on the effect of Costus Plant and Amphotericin B on male lung rats infected by Aspergillus niger . Life Science Journal 2012;9(4)
- Sharif, Fayyad Mohammed Sharif (2012). Medical Fungi . Memory for Printing and Publishing (468 pages).
- Singh, U.P., Srivastava, B.P., Singh, K.P. and Pandey, V.B. 1992. Antifungal activity of steroid saponins and saponinins from Avena sativa and Costus speciosus. Naturalia Sao Paulo., 17: 71-77.

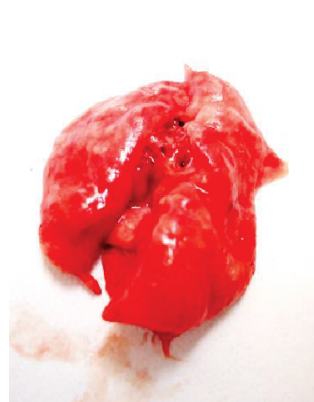
Veeramuthu D.; Naif A.; Savarimuthu L. and Chinnasamy M. (2012) . Antimicrobial activity of sesquiterpene lactones isolation from traditional medicinal plant, *Costus speciosus* (Koen) . 1472-6882 .



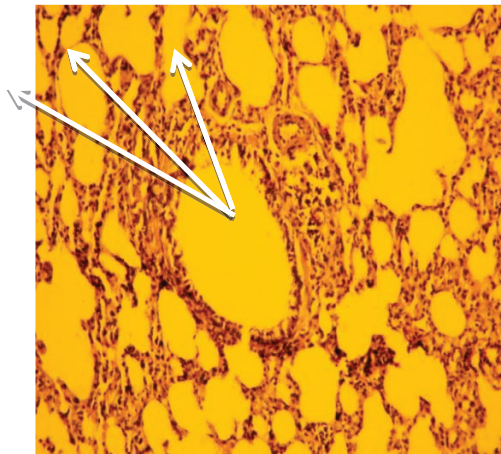
(Fig.1) Rat lung infected with fungus *A.fumigatus* observed congested and red hepatization.



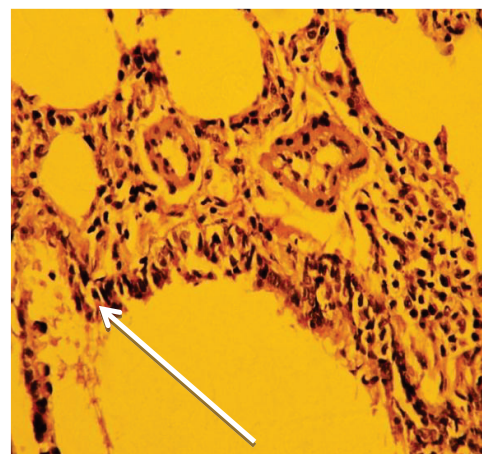
(Fig. 2) Rat lung infected with fungus *A.fumigatus* via inhalation and treated with a solution of plant extract *C.speciosus* for a period (21 days).



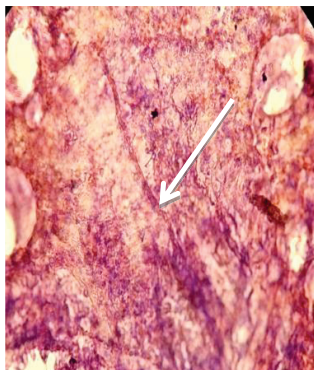(Fig. 3) Normal rat lung did not notice any pathological changes



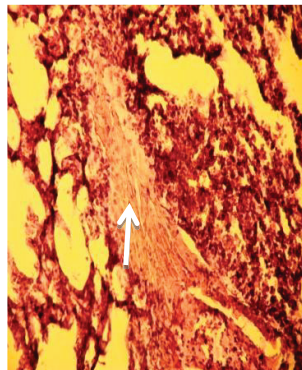
(Fig. 4) c.s. of lung tissue control group observed alveolitis, alveolar barriers between regular (H & E x100).



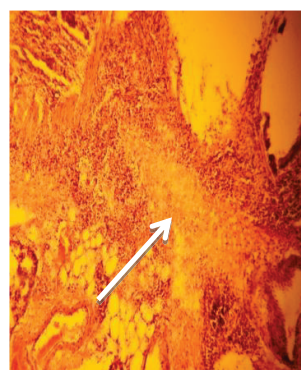
(Fig. 5) c.s. of lung tissue control group clarifying the cells lining the bronchi basis. (H & E x100)



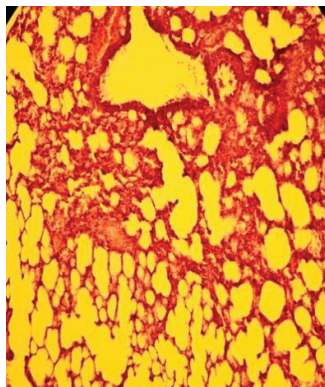
(Fig. 6) c.s.of infected lung
Appear hyphae of fungus
(→) (H&E x400)



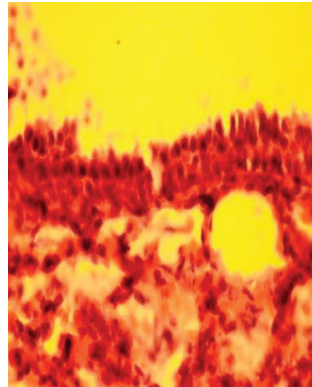
(Fig. 7) c.s. of infected lung
appear liquid mucous
in respiratory bronchitis,
bleeding and severe congestion,
inflammatory cells around
the alveoli (H&E x100)



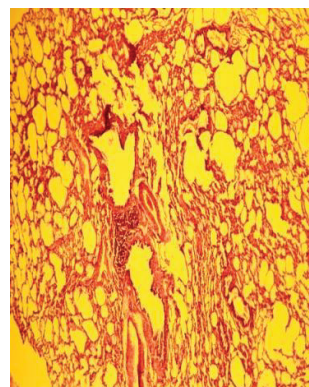
(Fig8.)c.s. of the lung appear
suppurative reaction
(H&E x100)



(Fig.9)c.s. of the
Infected lung treated with
extract of C.speciosus appear
alveoli is shape recovery
(H&E x100)



(Fig.10)c.s. of the infected
lung treated with extract,
bronchi its natural form
less congestion and
less bleeding
(H&E x1000)



(Fig. 11)c.s. of the infected
lung, appear- natural air alveoli
(H&E x100)

This academic article was published by The International Institute for Science, Technology and Education (IISTE). The IISTE is a pioneer in the Open Access Publishing service based in the U.S. and Europe. The aim of the institute is Accelerating Global Knowledge Sharing.

More information about the publisher can be found in the IISTE's homepage:

<http://www.iiste.org>

CALL FOR JOURNAL PAPERS

The IISTE is currently hosting more than 30 peer-reviewed academic journals and collaborating with academic institutions around the world. There's no deadline for submission. **Prospective authors of IISTE journals can find the submission instruction on the following page:** <http://www.iiste.org/journals/> The IISTE editorial team promises to review and publish all the qualified submissions in a **fast** manner. All the journals articles are available online to the readers all over the world without financial, legal, or technical barriers other than those inseparable from gaining access to the internet itself. Printed version of the journals is also available upon request of readers and authors.

MORE RESOURCES

Book publication information: <http://www.iiste.org/book/>

Recent conferences: <http://www.iiste.org/conference/>

IISTE Knowledge Sharing Partners

EBSCO, Index Copernicus, Ulrich's Periodicals Directory, JournalTOCS, PKP Open Archives Harvester, Bielefeld Academic Search Engine, Elektronische Zeitschriftenbibliothek EZB, Open J-Gate, OCLC WorldCat, Universe Digital Library, NewJour, Google Scholar

