

# Clinicopathological Evaluation of Appendicitis

Hatice Beseren,  
Kafkas University, Department of Pathology, Kars, Turkey

Gulden Yildiz,  
Kafkas University, Department of Pathology, Kars, Turkey

Tulay Diken Allahverdi  
Kafkas University, Department of General Surgery, Kars, Turkey

## Abstract

Acute appendicitis, most common acute requiring surgery. It is the cause of abdominal pain and appendectomy is the first of the emergency operations all over the World gets. Obstruction is the most common cause of acute appendicitis. The factors causing obstruction are fecalites, foreign body, gallbladder stone, cecum tumor or it may be a primary tumor of the appendix. In this review article, we aimed to create a resource by bringing together the clinical and pathological features of appendicitis cases.

**Keywords:** Acute appendicitis, acute surgery, appendectomy

**DOI:** 10.7176/JSTR/7-10-08

## Introduction

The appendix vermiformis is an underdeveloped remnant 7-10 cm long, attached to the cecum. Since its tip is not fixed, it can move freely. The appendix has a mesentery extending from the ileum, called the mesoappendices, and its wall consists of colonic type mucosa, submucosa, muscular layer and serosa. The most prominent microscopic feature is the mucosal and submucosal lymphoid tissue, which develops in early childhood, reaches the greatest diameter in adolescence, and then progressively atrophies. In the elderly, the distal portion undergoes fibrotic obliteration.

## Appendicitis

Acute appendicitis is an inflammatory disease of the appendix wall resulting in transmural necrosis and perforation followed by localized or generalized peritonitis. It is the most common disease of the appendix and is the most common cause of acute abdomen. Although it is more common in men, adolescents and young adults, it can occur at any age. Yersinia infection; It can spread from the ileum, causing granulomatous inflammation. Tuberculous appendicitis is usually accompanied by tuberculous enteritis. Chorn's disease and ulcerative colitis may involve the appendix to a small extent.

## Pathogenesis

It is thought that acute appendicitis develops as a result of occlusion of the appendix orifice, secondary expansion of the lumen and bacterial invasion of the wall. Mechanical obstruction, frequently caused by feces, to a lesser extent by tumors, parasites such as *Enterobius vermicularis*, or foreign bodies, has been demonstrated in 50-80% of cases. Lymphoid hyperplasia after bacterial or viral infection (*Salmonella* or measles) may obstruct the lumen. However, in some of the cases, obstruction cannot be shown and the cause of the disease cannot be determined. High rates of appendicitis are seen in industrialized countries fed with fiber-poor foods. Increased secretion as a result of occlusion, when the appendix fills, the pressure gradually increases, the venous pressure passes, causing venous stasis and ischemia. As a result, the mucosa becomes ulcerated and the invasion of intestinal bacteria begins.

## Clinical Findings

Acute appendicitis typically presents with abdominal pain in the form of epigastritis or periumbilical cramps. However, the pain may be diffuse or localized in the right lower quadrant since onset. Nausea, vomiting, mild fever and moderate leukocytosis ( $15\text{-}20,000\text{ cells/mm}^3$ ) are added to the table after a

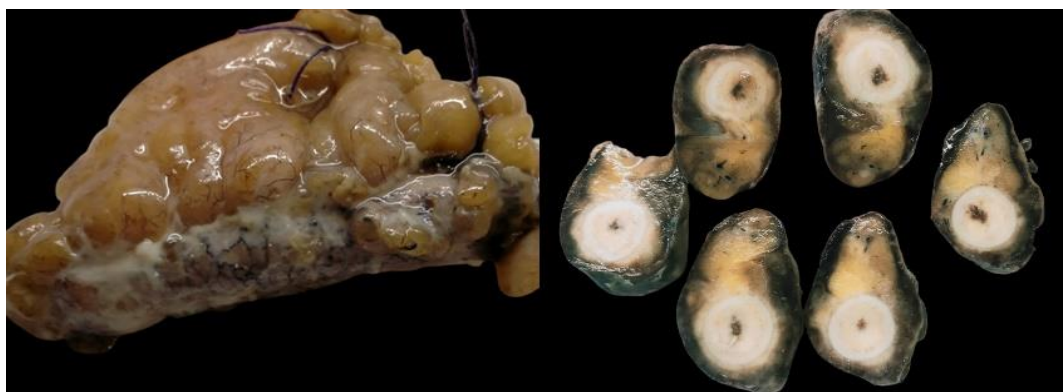short time. The pain shifts to the right lower quadrant, as a rule, point tenderness is detected. If there is a retrocecal location or malrotation in the appendix, atypical symptoms lead to misinterpretation. In the elderly or young children, when appendicitis causes mild symptoms, it is often not diagnosed before it is perforated. Many conditions that do not actually require surgery, such as mesenteric adenitis in children, Meckel's diverticulitis, mittelschmerz (pain due to pelvic bleeding during ovulation), acute salpingitis, Yersinia, or viral enterocolitis, are misdiagnosed as appendicitis in a not uncommon rate. The treatment of acute appendicitis is surgery in the majority of cases. Because perforation carries a greater risk of death than laparotomy, early surgical intervention is preferred, even in those with uncertain diagnosis. Indeed, 10-25% of all resected appendages are found to be normal. Chronic appendicitis is not usually recognized as a pathological entity. However, sometimes acute and chronic inflammation with granulation tissue, fibrosis, organized appendicitis or recurrent appendicitis have been reported. Since in some people the appendix is fibrous cord-shaped from birth, it is difficult to say that fibrosis develops as a result of previous inflammation.

### Pathology

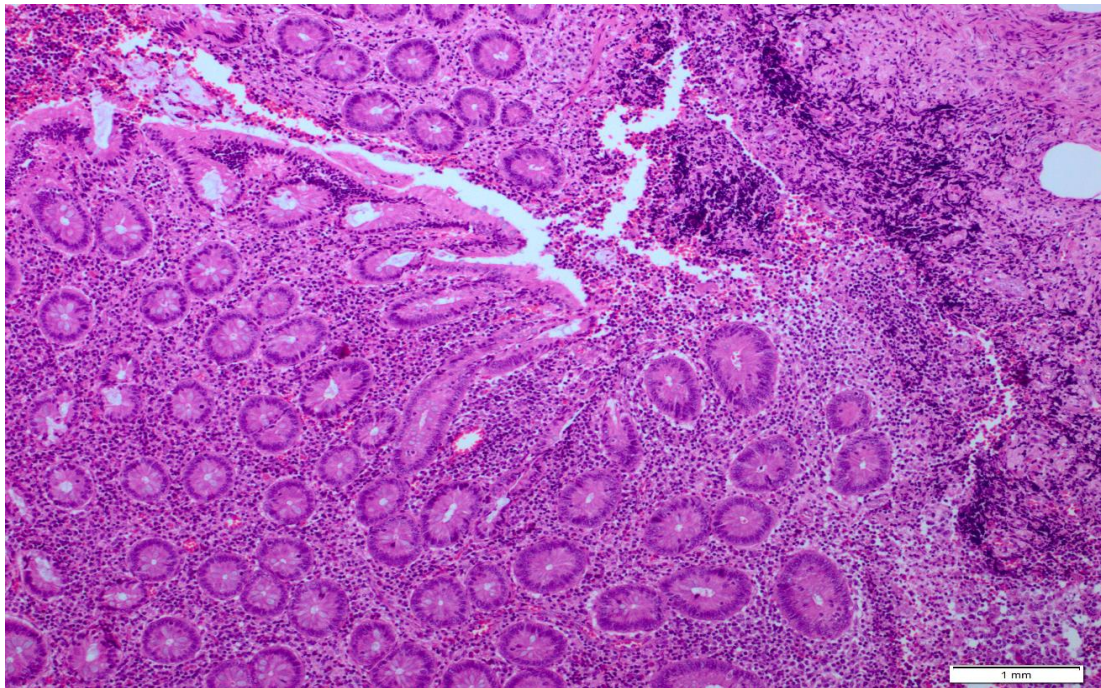
Macroscopically, the appendix is swollen, tense, and covered with exudate. The lumen often contains pus and fecalites may be present. Microscopically, in early cases, there are microabscesses in the mucosa and purulent exudate in the lumen. As the infection progresses, neutrophils reach the serosa by infiltrating the entire wall. Subserosal vessels are hyperemic and there is often mild perivascular infiltrate. The normally shiny serosa becomes a dull, granular, red membrane. In advanced cases, suppurative infiltration of the ulcer and wall (acute suppurative-phlegmonous appendicitis) leads to perforation with green-black gangrenous necrosis (acute gangrenous appendicitis) and discharge of luminal contents into the peritoneal cavity. Generally, the accepted histological criterion for appendicitis is neutrophilic infiltration of the muscular layer. In patients without surgery, chronic abscess may occur or the inflammatory event will heal with scarring. Complications of appendicitis are due to perforation, which is more common in children, young adults, and patients over 60 years of age. Periappendiceal abscesses are common, but abscesses can develop anywhere in the abdominal cavity. Fistula may develop between the perforated appendix and adjacent structures such as the small and large intestines, bladder, vagina or abdominal wall. Thrombophlebitis of the roots of the intrahepatic portal vein and secondary hepatic abscesses may occur, since the appendix carries superior mesenteric venous blood. Diffuse peritonitis and septicemia are dangerous sequelae. The most common complication after surgery is wound infection.

### Conclusion

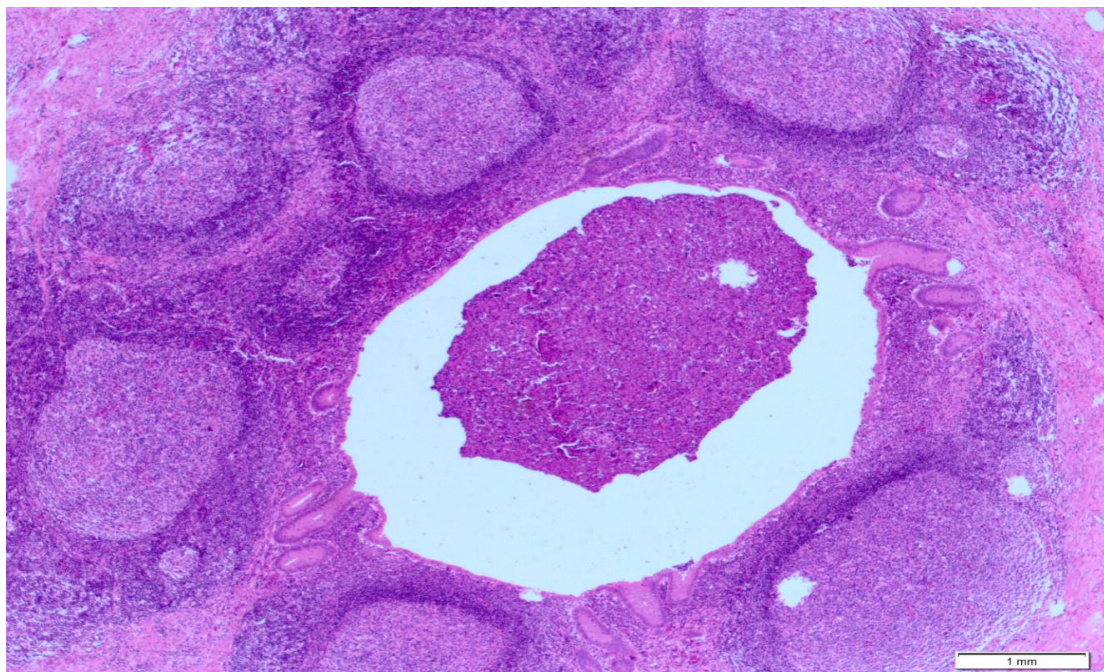
In conclusion, appendicitis is one of the most common diseases whose clinical findings can be overlooked. Therefore, even cases with uncertain diagnosis are operated so that perforation cases are not overlooked. The macroscopy of these cases is usually swollen, tight and filled with exudate. When the cut surfaces are examined, the lumen is dilated with pus or fecaloid structure. Microscopically, in early cases, there are microabscesses in the mucosa and purulent in the lumen, while in advanced cases, neutrophils infiltrate the entire wall and reach the serosa. We think that this review article will be a guide for clinic and pathology professionals.



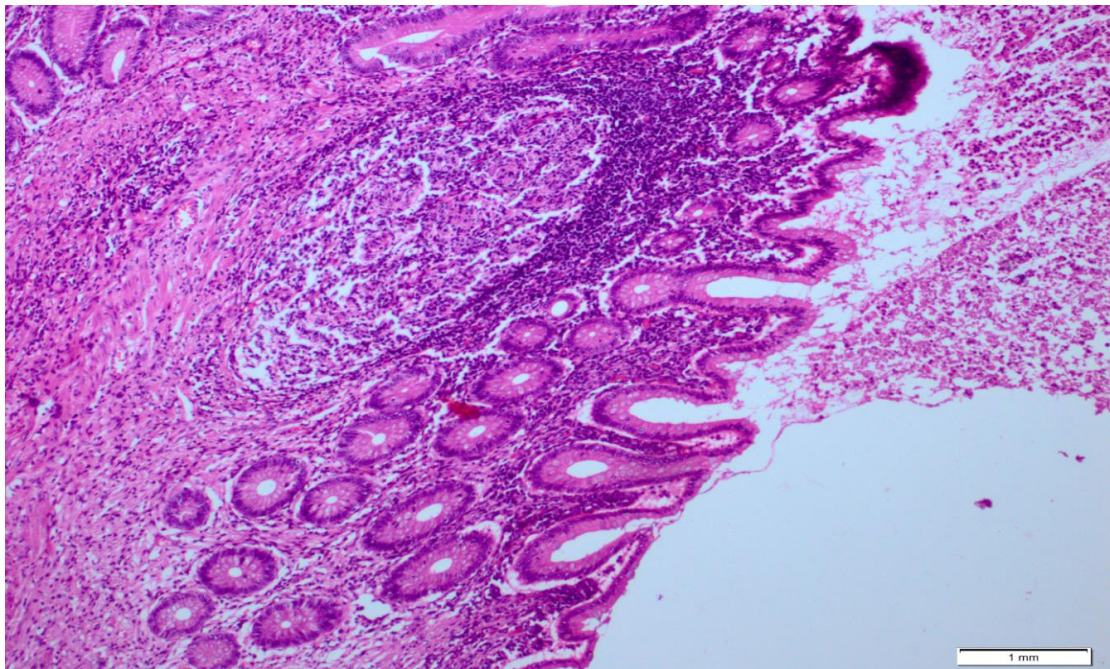
**Figure 1:** Microscopically, the appendix is swollen, tense, and covered with exudate. The cross-sectional surface is covered with creamy-white pus.



**Figure 2:** In the samples of the appendix wall, the surface epithelium is partially eroded, and inflammatory cell infiltration rich in polymorphuclear leukocytes starting from this area and progressing to the serosal surface is remarkable (HE, x10).



**Figure 3:** Follicular structures with prominent germinal centers(HE, x4).



**Figure 4:** In this area, lymphoid follicles with prominent germinal centers are distinguished under the surface epithelium (HE, x10).

#### References

1. Dunn JCY. Appendicitis. In: Coran AG, Adzick NS, Krummel TM, Laberge JM, Shamberger RC, Caldamone A, eds. *Pediatric Surgery*. Vol. 2. 7th ed. Philadelphia, USA: Saunders; 2012:1255-1263.
2. Puri P, Guiney EJ, O'Donnell B, et al. Effects of perforated appendicitis in girls on subsequent fertility. *Br Med J (Clin Res Ed)* 1984;288:25-6.
3. Andersson R, Lambe M, Bergström R. Fertility patterns after appendicectomy: historical cohort study. *BMJ*. 1999;10;318:963-7.
4. Jess, P: Acute appendicitis: epidemiology, diagnostic accuracy, and complications. *Scand. J. Gastroenterol*. 1983;18:161-164.
5. Luckmann, R: Incidence and case fatality rates for acute appendicitis in California; a population-based study of the effects of age. *Am. J. Epidemiol*. 1989;129:905-909.
6. Rusnak, R., Borer, J.M., Fastow, J.S: Misdiagnosis of acute appendicitis: common features discovered in cases after litigation. *Am. J. Emerg. Med*. 1994;12:397-401.